



**PATIENT**

Foster Burke-Frazier

**SPECIES**

Feline

**BREED**

DSH

**SEX**

Neutered Male

**AGE**

2011

**WEIGHT**

11.2 Pounds

**INTERPRETED BY**

Eric Lindquist, DMV  
DABVP, Cert. IVUSS

**IMAGING PERFORMED BY**

Amanda Crook-SDEP  
Certified Clinical  
Sonographer

**HOSPITAL NAME**

Rivers Edge PMC

**REFERRING VET**

Dr. Bridget Hayes

**INVOICE**

12764

**DATE**

8/26/21

**PRESENTING CLINICAL SIGNS**

History: Poor appetite and weight loss. Now not eating, not drinking, may have vomited. Hx of struvite crystals. Current Medications: clavamox, gabapentin, prazosin started 8/24

Abnormal PE/Chem/CBC/UA Results: See attached - BW normal, mild hematuria See attached radiographs - inhouse interpretation; no sig. findings.

Radiographs: Hyperinflated lungs. Mild renomegaly. Density in the cranial mediastinum.

**ULTRASONOGRAPHIC EXAMINATION OF THE HEART & ABDOMEN**

FELINE CARDIAC PARAMETERS	BODY WEIGHT (kg)	HR (BPM)	IVSd (cm)	LVIDd (cm)	LVWd (cm)	FS (%)	EF (%)
<b>NORMAL PARAMETER</b>	-----	150-240	0.3-0.6	1.0-2.1	0.25-0.6	35-67	80-100
<b>PATIENT</b>	--	159	0.46	1.78	0.43	67	95
FELINE CARDIAC PARAMETERS	LA/AO (Boon)	LA/AO HEART BASE (Sisson)	LA 2D 4-chamber long axis AS to FW (Sisson) (cm)	LVOT VEL. (m/s)	RVOT VEL. (m/s)	IVRT (m/)	
<b>NORMAL PARAMETER</b>	<1.5	0.88-1.79	0.7-1.7	<1.6	<1.3	40-60	
<b>PATIENT</b>	1.2	--	--	1.20	.80	NM	
Adapted from June Boon, Veterinary Echocardiography, 1998 Sisson D et al. JVIM 1991; 5: 232, Jacobs et al. Am J Vet Res 1985; 46:1705							

**Cardiac Presentation**

The echocardiogram in this patient demonstrated normal **left atrial** size based on 3 separate LA measurements. The cranial and caudal **mitral** valve leaflets presented normal linear structure and kinetics. The **left ventricle** presented normal thicknesses with linear contour and was not dilated nor restricted. The **myocardium** presented normal echogenicity without subjective evidence of significant fibrotic or ischemic disease. **Contractility** of the ventricular walls was adequate and in normal range for this patient evidenced by the fractional shortening measurement and subjective evaluation of the different regions and angles of the myocardium. The **left ventricular outflow** tract demonstrated normal laminar flow and subjective structural integrity. The **right atrium** and auricle revealed normal size, structure and content. No evidence of masses was noted or chamber overload. Trivial **Tricuspid** insufficiency noted at 2.4 m/s-not clinically significant. The **right ventricle** was of normal size (1/3 diameter of LV), chordae structure, myocardial echogenicity and thickness. **Pulmonic** tract assessment revealed normal valve structure, laminar flow, and diameter (approx.1:1 pa/ao ratio). No visible **pericardial** or free pleura fluid was noted or extra cardiac pathology in the visible planes. The cranial **mediastinum and pericardial regions** were free of masses in the visible window.

**Urinary System**



**PATIENT**

Foster Burke-Frazier

**SPECIES**

Feline

**BREED**

DSH

**SEX**

Neutered Male

**AGE**

2011

**WEIGHT**

11.2 Pounds

**INTERPRETED BY**

Eric Lindquist, DMV  
DABVP, Cert. IVUSS

**IMAGING PERFORMED BY**

Amanda Crook-SDEP  
Certified Clinical  
Sonographer

**HOSPITAL NAME**

Rivers Edge PMC

**REFERRING VET**

Dr. Bridget Hayes

**INVOICE**

12764

**DATE**

8/26/21

The **urinary bladder** and visible pelvic urethra were unremarkable for the level of repletion presented. The urine, however, did present some minor mildly echogenic debris consistent with mucous, exfoliated cells from renal or bladder origin, and/or blood clots as these echogenic changes can all present similarly. This is often related to urinary tract infection but may represent simple evidence of exfoliated debris or sterile inflammation. Cystocentesis, urinalysis, +/- culture would be recommended to rule out and define any UTI.

The **kidneys** revealed largely normal size and structure, corticomedullary definition and ratio (cortex 1/3 of medulla) were essentially maintained with some mild age-related loss of curvilinear patterns regarding the capsule and C/M junction. The cortices presented largely uniform texture with some increased echogenicity expected for his age patient. Medullary structure differed distinctly from that of the cortex and no evidence of pelvic dilation was present. The left kidney measured 4.64 cm. Minor mineralization was noted in the right kidney. The right kidney measured 4.45 cm.

**Adrenal Glands**

The **left adrenal gland** was visualized and recognized as having normal shape, size, position and echogenicity for this breed. The phrenic vasculature, glandular echogenicity and detail were unremarkable. Capsule, cortex, and medullary definition were normal for this age patient. The left adrenal gland measured 0.28 cm.

The region of the **right adrenal gland** was unremarkable.

**Spleen**

The **spleen** presented a smooth homogeneous parenchyma hyperechoic to liver and renal cortical parenchyma. The capsule was smooth without noticeable expansion or deviation from within the spleen or adjacent pathology. The splenic vasculature demonstrated normal volume without signs of congestion or thrombosis. No sonographic evidence of acute or chronic inflammatory, neoplastic, or infarctual changes were noted.

**Liver**

The **liver** images from right and left intercostal as well as subcostal views revealed subjectively normal liver size, contour, and structure. Some minor age-related parenchymal remodeling was noted but likely not clinically significant at this time. Vascular and biliary tracts were of normal volume and no evidence of congestion was noted. The gallbladder presented some dependent debris with essentially normal contour. The cystic and common bile ducts were normal. No overt evidence of active inflammatory, infiltrative or regenerative pathology was noted but should be paired with current or past LE elevations regarding any clinical significance to this presentation. The hepatic lymph nodes were unremarkable.

**Gastrointestinal**

The **small intestine** revealed a regional thickening. Wall thickness of 0.44 cm and 1.4 x 2.0 cm tapering intestinal mass deriving from the muscularis. The intestinal mass appears to be jejunum and appears to be resectable. This may not be neoplastic as the submucosal layer is largely intact, however, the muscularis is thickened. The remainder of the intestinal tract was unremarkable and empty.

**Pancreas**



## PATIENT

Foster Burke-Frazier

## SPECIES

Feline

## BREED

DSH

## SEX

Neutered Male

## AGE

2011

## WEIGHT

11.2 Pounds

## INTERPRETED BY

Eric Lindquist, DMV  
DABVP, Cert. IVUSS

## IMAGING PERFORMED BY

Amanda Crook-SDEP  
Certified Clinical  
Sonographer

## HOSPITAL NAME

Rivers Edge PMC

## REFERRING VET

Dr. Bridget Hayes

## INVOICE

12764

## DATE

8/26/21

The base and limbs of the **pancreas** were observed to be largely isoechoic to surrounding omental fat. Some minor parenchymal remodeling, however, with mild deviation from curvilinear normalcy was observed. Pancreatic duct and capsular irregularities were present consistent with age related changes. If pain upon imaging (+ Murphy sign) was present or if the patient is focally painful in subxyphoid palpation then low-grade smoldering chronic pancreatitis should be suspected.

## Thorax

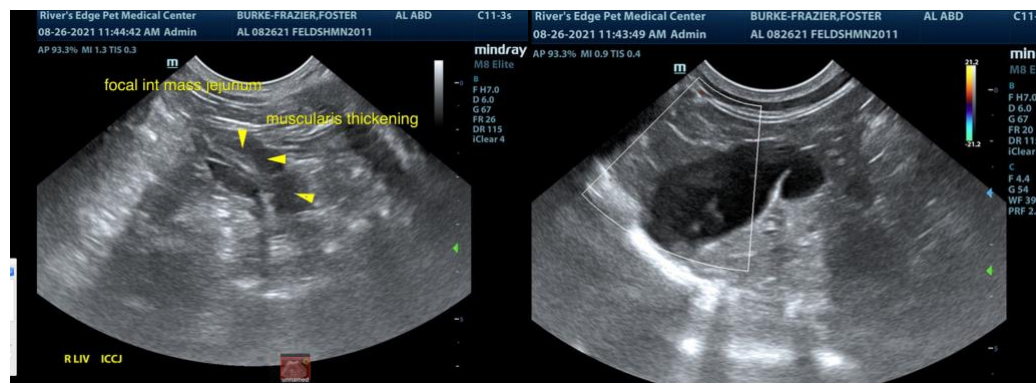
A 1.5 cm x 1.0 cm anechoic cyst was noted, most consistent with **branchial** cyst, likely not pathological.

## ULTRASONOGRAPHIC FINDINGS

- Normal echocardiogram- no evidence of pathology other than minor tricuspid insufficiency, not clinically significant
- Focal and jejunal mass with muscularis hypertrophy- regional lymphoma versus idiopathic muscularis hypertrophy, inflammatory bowel, dry form FIP all potentials in this case. Carcinoma, minor potential
- Largely geriatric changes

## INTERPRETATION OF THE FINDINGS & FURTHER RECOMMENDATIONS

Intraoperative ultrasound would be ideal in this patient with resection of approximately 4.0-5.0 cm of intestine as the remainder of the abdomen appears to be geriatric. I do not believe that the cranial mediastinum is related to the abdominal presentation as the structure appears to be consistent with a branchial cyst, ultrasound FNA/drainage could be performed to confirm. Ultrasound guided FNA of the intestinal mass could be considered, however, this type of mass often does not exfoliate adequately for a definitive diagnosis.





**PATIENT**

Foster Burke-Frazier

**SPECIES**

Feline

**BREED**

DSH

**SEX**

Neutered Male

**AGE**

2011

**WEIGHT**

11.2 Pounds

**INTERPRETED BY**

Eric Lindquist, DMV  
DABVP, Cert. IVUSS

**IMAGING PERFORMED BY**

Amanda Crook-SDEP  
Certified Clinical  
Sonographer

**HOSPITAL NAME**

Rivers Edge PMC

**REFERRING VET**

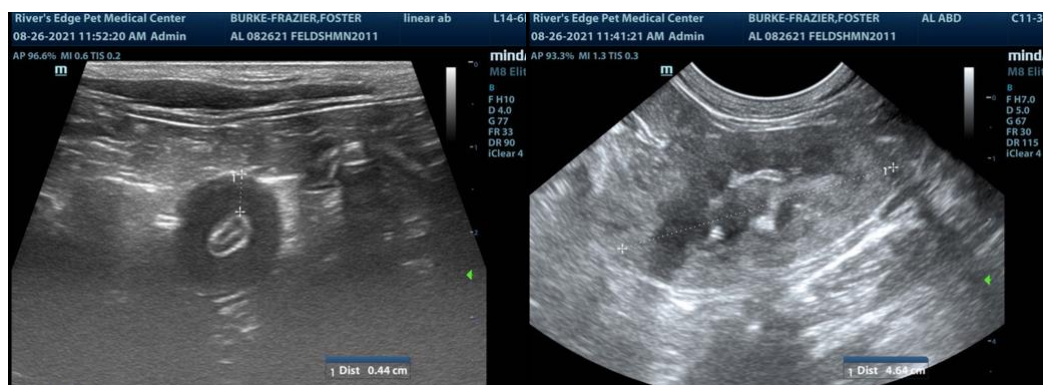
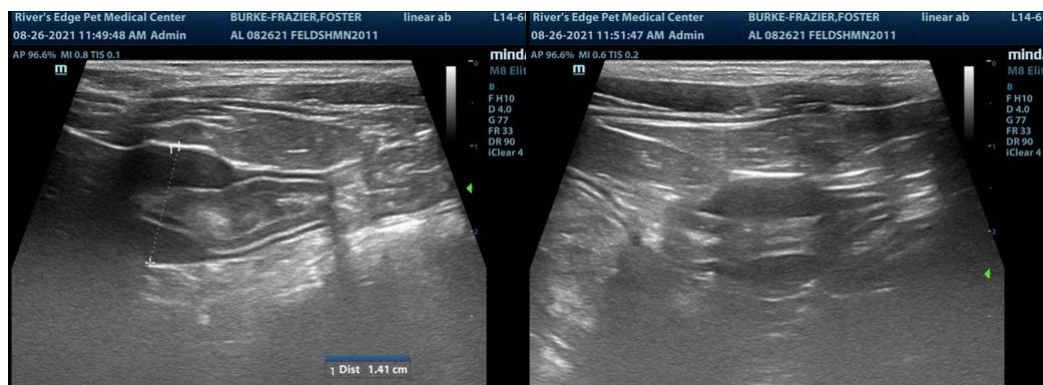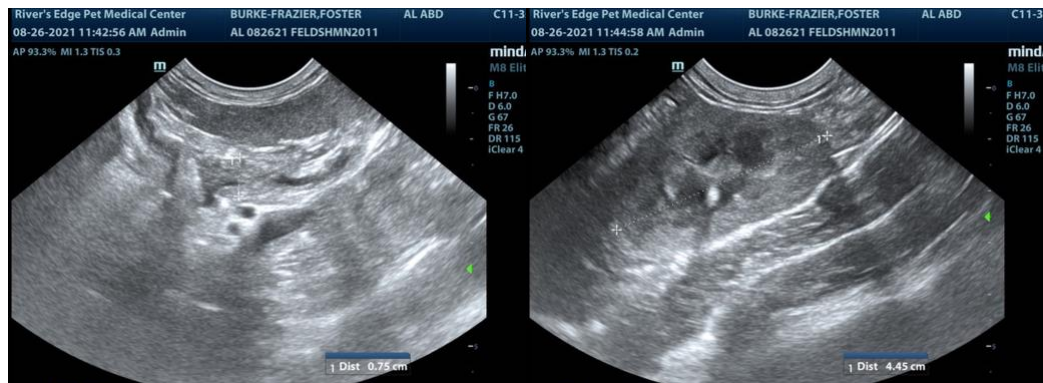
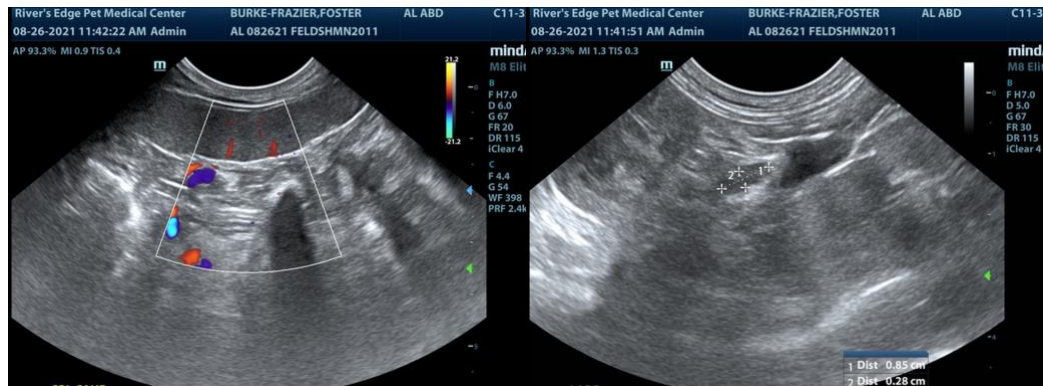
Dr. Bridget Hayes

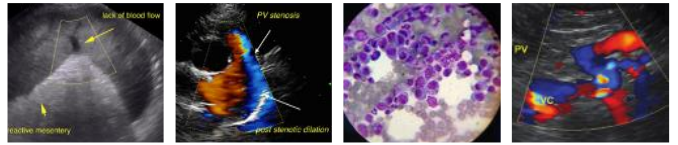
**INVOICE**

12764

**DATE**

8/26/21





**PATIENT**

Foster Burke-Frazier

**SPECIES**

Feline

**BREED**

DSH

**SEX**

Neutered Male

**AGE**

2011

**WEIGHT**

11.2 Pounds

**INTERPRETED BY**

Eric Lindquist, DMV  
DABVP, Cert. IVUSS

**IMAGING PERFORMED BY**

Amanda Crook-SDEP  
Certified Clinical  
Sonographer

**HOSPITAL NAME**

Rivers Edge PMC

**REFERRING VET**

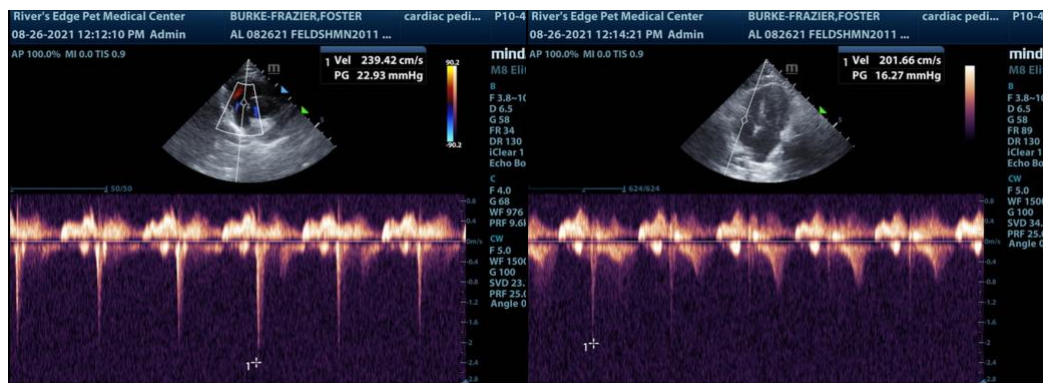
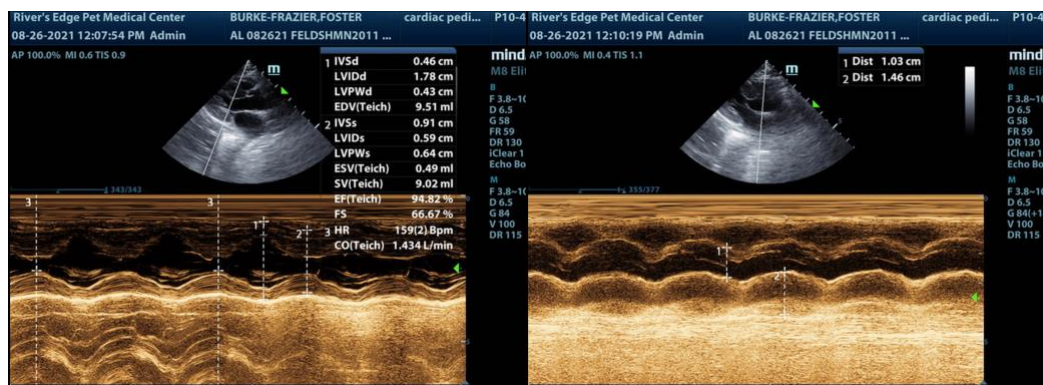
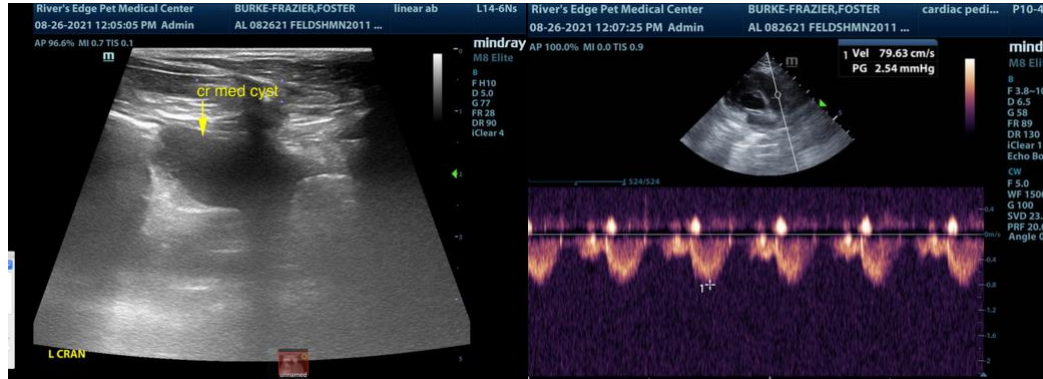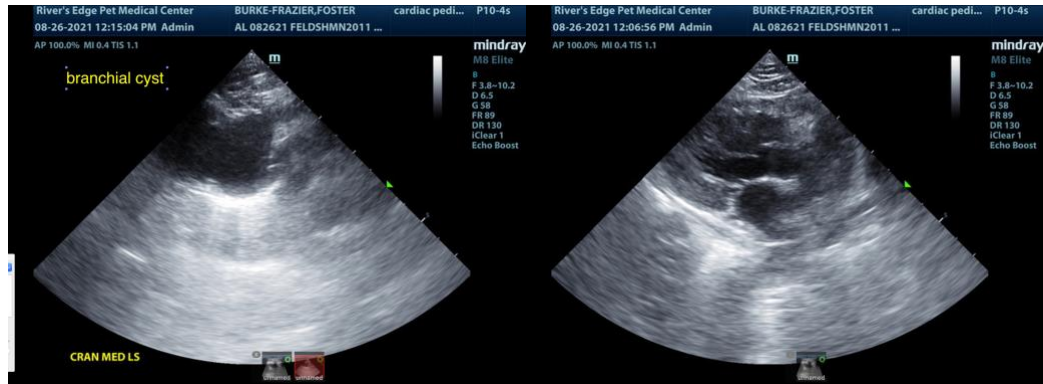
Dr. Bridget Hayes

**INVOICE**

12764

**DATE**

8/26/21





**PATIENT**

Foster Burke-Frazier

**The information and recommendations provided are based on the images presented by the referring veterinarian. No evaluation can be communicated regarding pathology that was not visible in the image/video clips provided.**

**SPECIES**

Feline

Thank you for this referral. If the clinical or image interpretation does not parallel your findings or if I can be of any further assistance please contact me.

**BREED**

DSH

**Eric Lindquist**, DMV, DABVP, Cert. IVUSS, CEO of SonoPath.com

info@SonoPath.com

**SEX**

Neutered Male

**AGE**

2011

**WEIGHT**

11.2 Pounds

**INTERPRETED BY**

Eric Lindquist, DMV  
DABVP, Cert. IVUSS

**IMAGING  
PERFORMED BY**

Amanda Crook-SDEP  
Certified Clinical  
Sonographer

**HOSPITAL NAME**

Rivers Edge PMC

**REFERRING VET**

Dr. Bridget Hayes

**INVOICE**

12764

**DATE**

8/26/21