



**PATIENT**

Buzz Mailhot

**PRESENTING CLINICAL SIGNS**

History: 3/6 murmur, cardiomegaly on rads; seen at ER for leg pain - presumed embolism. On clopidogrel 75 mg x 1/4 sid and buprenex  
Abnormal PE/Chem/CBC/UA Results: BNP abnormal

**SPECIES**

Feline

**ULTRASONOGRAPHIC EXAMINATION OF THE HEART**

The cardiac presentation presented moderately excessive septal and free wall thicknesses with normal contractility. Left ventricular internal diameter was normal. Severe left atrial enlargement was noted with mitral and tricuspid insufficiency. No pericardial or pleural effusion was noted. No clots were noted, however, some smoke was noted in the left atrium.

**BREED**

Domestic Shorthair

**SEX**

Neutered male

**AGE**

4 years

**WEIGHT**

lbs

**INTERPRETED BY**

Eric Lindquist, DMV  
DABVP, Cert. IVUSS

**IMAGING PERFORMED BY**

Diane McFadden, RVT

**HOSPITAL NAME**

Fredon AH

**INVOICE**

91504

**DATE**

8/26/21

FELINE CARDIAC PARAMETERS	BODY WEIGHT (kg)	HR (BPM)	IVSd (cm)	LVIDd (cm)	LVWd (cm)	FS (%)	EF (%)
NORMAL PARAMETER	-----	150-240	0.3-0.6	1.0-2.1	0.25-0.6	35-67	80-100
PATIENT		193	0.67	1.5	0.67	37	70
FELINE CARDIAC PARAMETERS	LA/AO (Boon)	LA/AO HEART BASE (Sisson)	LA 2D 4-chamber long axis AS to FW (Sisson) (cm)	LVOT VEL. (m/s)	RVOT VEL. (m/s)	IVRT (m/)	
NORMAL PARAMETER	<1.5	0.88-1.79	0.7-1.7	<1.6	<1.3	40-60	
PATIENT	2.21	2.4	2.37 max	1.01	1.0	NM	
Adapted from June Boon, Veterinary Echocardiography, 1998 Sisson D et al. JVIM 1991; 5: 232, Jacobs et al. Am J Vet Res 1985; 46:1705							

**ULTRASONOGRAPHIC FINDINGS**

Hypertrophic to unclassified cardiomyopathy with left-sided congestive heart failure.

**INTERPRETATION OF THE FINDINGS & FURTHER RECOMMENDATIONS**

I recommend triple therapy in this patient with Pimobendan off label at 0.3 mg/kg b.i.d., Lasix 12.5 mg b.i.d. reducing to minimal effective dose. Ace inhibitor can also be considered at 0.5 mg/kg s.i.d. Assessment of BUN, creatinine, USG, chest radiographs and blood pressure as well as clinical exam is ideal in 7-10 days. Basal respiratory rate should be <20/min. I recommend continuation of Plavix therapy. Recheck echocardiogram in 10-14 days assuming this patient is able to survive this current crisis. Guarded prognosis.



**PATIENT**

Buzz Mailhot

**SPECIES**

Feline

**BREED**

Domestic Shorthair

**SEX**

Neutered male

**AGE**

4 years

**WEIGHT**

lbs

**INTERPRETED BY**

Eric Lindquist, DMV  
DABVP, Cert. IVUSS

**IMAGING  
PERFORMED BY**

Diane McFadden, RVT

**HOSPITAL NAME**

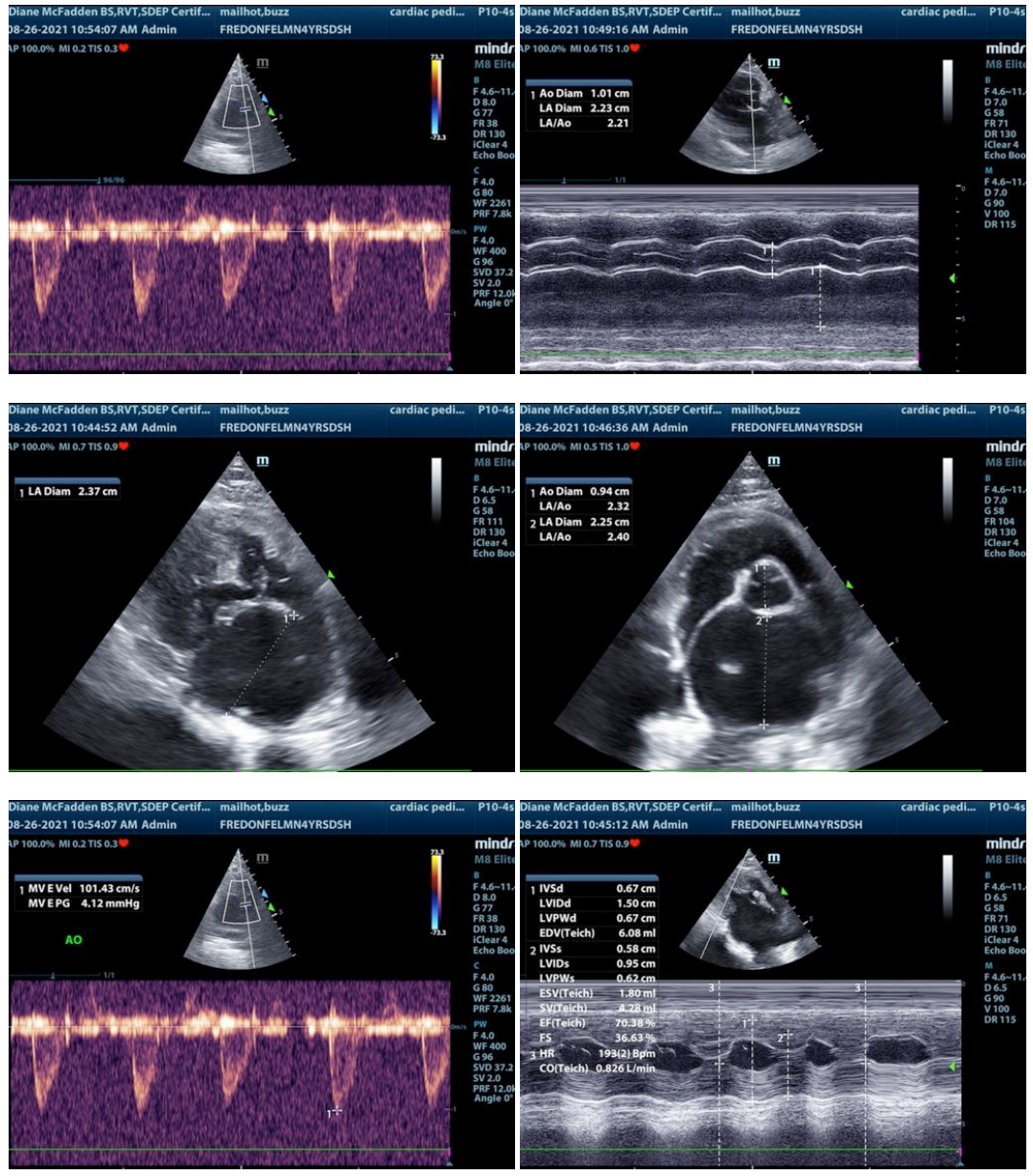
Fredon AH

**INVOICE**

91504

**DATE**

8/26/21



The information and recommendations provided are based on the images presented by the referring veterinarian. No evaluation can be communicated regarding pathology that was not visible in the image/video clips provided.

Thank you for this referral. If the clinical or image interpretation does not parallel your findings or if I can be of any further assistance please contact me.

Eric Lindquist, DMV, DABVP, Cert. IVUSS, CEO of SonoPath.com  
Info@SonoPath.com