



PATIENT

Dabo Riley

SPECIES

Canine

BREED

Boxer X

SEX

Neutered Male

AGE

2 Years

WEIGHT

74 Pounds

INTERPRETED BY

Eric Lindquist, DMV
DABVP, Cert. IVUSS

IMAGING PERFORMED BY

A.Rodriguez

HOSPITAL NAME

Foxfield VS

REFERRING VET

A.Rodriguez

INVOICE

12737

DATE

8/25/21

PRESENTING CLINICAL SIGNS

History: Vomiting and diarrhea.

Abnormal PE/Chem/CBC/UA Results: Pending

ULTRASONOGRAPHIC EXAMINATION OF THE ABDOMEN

Urinary System

The **urinary bladder**, trigone, and pelvic urethra presented normal thicknesses and normal tone. The ureters were not visible which is normal. No uroliths or sediment were visualized, and anechoic urine was present. No evidence of inflammatory or neoplastic changes were noted. Ureteral papillae were normal.

The **kidneys** revealed normal size and structure, corticomedullary definition and ratio for this age. The cortices presented largely uniform texture with normal echogenic relationship to liver and spleen. Medullary structure differed distinctly from the cortex and no evidence of pelvic dilation was present. The capsules were acceptably uniform without significant irregularities. The left kidney measured 5.64 cm. The right kidney measured 7.0 cm.

Adrenal Glands

Both **adrenal glands** were visualized and recognized as having normal shape, size, position and echogenicity for this breed. The phrenic vasculature, glandular echogenicity and detail were unremarkable. Capsule, cortex, and medullary definition were normal for this age patient. The left adrenal gland measured 3.28 cm x 0.52 cm. The right adrenal gland measured 3.02 cm x 0.71 cm.

Spleen

The **spleen** presented a smooth homogeneous parenchyma hyperechoic to liver and renal cortical parenchyma. The capsule was smooth without noticeable expansion or deviation from within the spleen or adjacent pathology. The splenic vasculature demonstrated normal volume without signs of congestion or thrombosis. No sonographic evidence of acute or chronic inflammatory, neoplastic, or infarctual changes were noted.

Liver

The **liver** images submitted revealed subjectively normal liver size, contour, and structure. Parenchymal echogenicity was naturally coarse and hypoechoic to the spleen. Vascular and biliary tracts were of normal volume with no evidence of congestion. The gallbladder presented acceptably thin walls with primarily anechoic content. The cystic and common bile ducts were normal. No pathological hepatic lymphadenopathy was evident. No overt structural evidence of inflammatory, infiltrative or regenerative pathology was evident.

Gastrointestinal

The **stomach** was empty. The pylorus was patent. No evidence of obstruction. Fluid filled cecum and colon noted continuing into the deep pelvic inlet.

Pancreas



PATIENT

Dabo Riley

The base and limbs of the **pancreas** were observed to be largely isoechoic to surrounding omental fat. Pancreatic duct and capsular contour were acceptably normal and parenchyma respected normal curvilinear patterns. No overt evidence of active inflammatory or neoplastic disease was noted.

SPECIES

Canine

Free Abdomen

The mesenteric **lymph node** presented normal length to width ratio with slight, swollen contour. There was no loss of parenchymal detail. This is most consistent with slight reactive lymphadenitis or lymphatic hyperplasia.

BREED

Boxer X

ULTRASONOGRAPHIC FINDINGS

- Resolving enteritis pattern
- Slightly reactive mesenteric lymph nodes

SEX

Neutered Male

INTERPRETATION OF THE FINDINGS & FURTHER RECOMMENDATIONS

No evidence of obstructive disease. Medical therapy recommended. I recommend a fresh fecal smear and fecal floatation analysis.

AGE

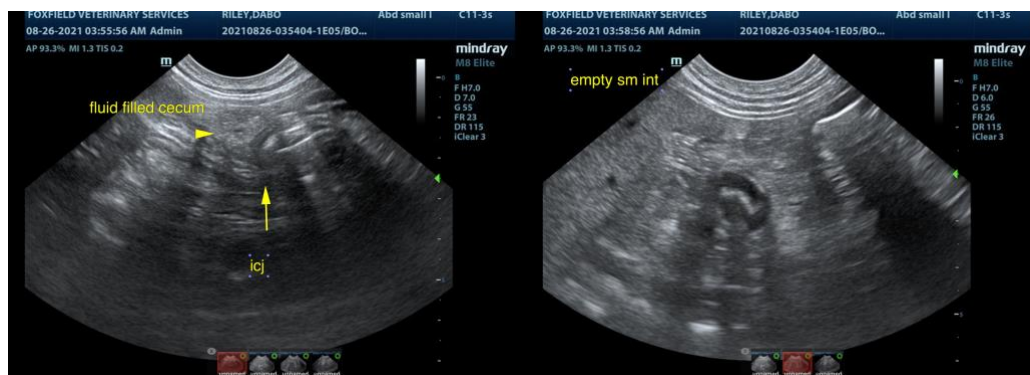2 Years

WEIGHT

74 Pounds

INTERPRETED BY

Eric Lindquist, DMV
DABVP, Cert. IVUSS

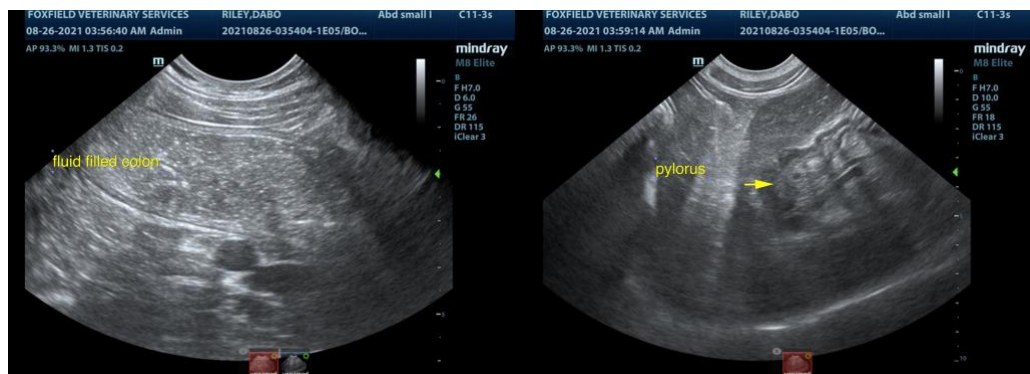


IMAGING PERFORMED BY

A.Rodriguez

HOSPITAL NAME

Foxfield VS



REFERRING VET

A.Rodriguez

INVOICE

12737

DATE

8/25/21



PATIENT

Dabo Riley

SPECIES

Canine

BREED

Boxer X

SEX

Neutered Male

AGE

2 Years

WEIGHT

74 Pounds

INTERPRETED BY

Eric Lindquist, DMV
DABVP, Cert. IVUSS

IMAGING PERFORMED BY

A.Rodriguez

HOSPITAL NAME

Foxfield VS

REFERRING VET

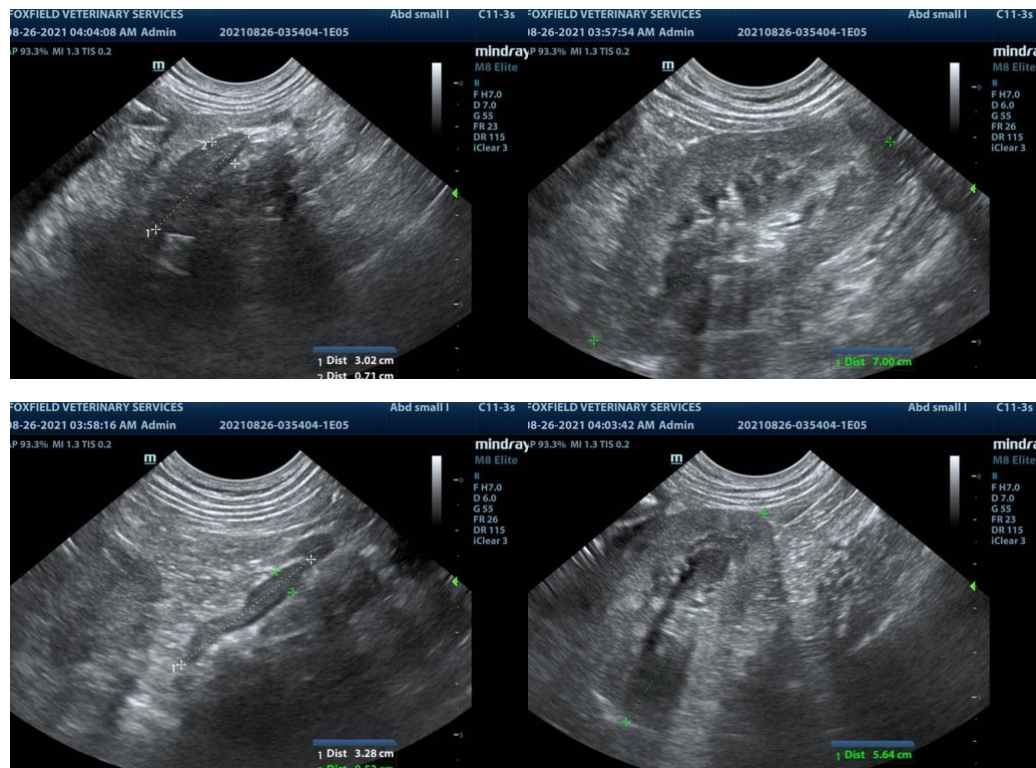
A.Rodriguez

INVOICE

12737

DATE

8/25/21



The information and recommendations provided are based on the images presented by the referring veterinarian. No evaluation can be communicated regarding pathology that was not visible in the image/video clips provided.

Thank you for this referral. If the clinical or image interpretation does not parallel your findings or if I can be of any further assistance please contact me.

Eric Lindquist, DMV, DABVP, Cert. IVUSS, CEO of SonoPath.com
info@SonoPath.com