



**PATIENT**

Spencer Corso

**PRESENTING CLINICAL SIGNS**

History: hepatic enlargement / grade 3 heart murmur / protein-losing nephropathy/ p has been on telmisarten and vetmedicine. blood work is normal

**SPECIES**

Canine

**ULTRASONOGRAPHIC EXAMINATION OF THE ABDOMEN**

**Urinary System**

**BREED**

Yorkshire Terrier

The **urinary bladder**, trigone, and pelvic urethra presented normal thicknesses and normal tone. The ureters were not visible which is normal. No uroliths or sediment were visualized and anechoic urine was present. No evidence of inflammatory or neoplastic changes was noted. Ureteral papillae were normal.

**SEX**

Neutered male

The **kidneys** presented a relatively uniform cortical hyperechogenicity when compared to the renal medulla, spleen and liver. No overt masses were noted. Corticomedullary definition was nebulous and the ratio favored the cortex slightly. The ureters were not visible and assumed to be normal. These changes are most consistent with chronic interstitial nephritis yet infiltrative disease could not be entirely ruled out without biopsy though neoplasia is not suspected. The right kidney measured 4.7 cm with corticomedullary mineralization, cortical infarcts and remodeling. The left kidney measured 3.8 cm.

**AGE**

11 years

**WEIGHT**

11 lbs

**Adrenal Glands**

Both **adrenal glands** were visualized and recognized as having largely normal shape, size, position and acceptable echogenicity for this age group and breed. Some heterogeneity was noted within the adrenal parenchyma without concerning capsular distortion. These changes are likely age related but should be monitored by sonogram should the patient be suspected of having adrenal disease. The left adrenal gland measured 0.45 cm at the caudal pole and 0.4 cm at the cranial pole. The right adrenal gland measured 0.57 cm.

**INTERPRETED BY**

Eric Lindquist, DMV  
DABVP, Cert. IVUSS

**IMAGING PERFORMED BY**

Dr. Han

**Spleen**

The **spleen** presented a smooth homogeneous parenchyma hyperechoic to liver and renal cortical parenchyma. The capsule was smooth without noticeable expansion or deviation from within the spleen or adjacent pathology. The splenic vasculature demonstrated normal volume without signs of congestion or thrombosis. No sonographic evidence of acute or chronic inflammatory, neoplastic, or infarctual changes was noted.

**HOSPITAL NAME**

Tenafly VC

**REFERRING VET**

Dr. Han

**Liver**

The **liver** images from right and left intercostal as well as subcostal views revealed subjectively normal liver size, contour, and structure. Some age-related parenchymal remodeling was noted but likely not clinically significant at this time. Vascular and biliary tracts were of normal volume and no evidence of congestion was noted. The gallbladder was mildly over distended with suspended and dependent debris, yet not to the level of emerging mucocele, yet sludge appears to be mildly excessive. No adjunctive inflammation was noted.

**INVOICE**

46758

**DATE**

8/24/23



## PATIENT

Spencer Corso

## SPECIES

Canine

## BREED

Yorkshire Terrier

## SEX

Neutered male

## AGE

11 years

## WEIGHT

11 lbs

## INTERPRETED BY

Eric Lindquist, DMV  
DABVP, Cert. IVUSS

## IMAGING PERFORMED BY

Dr. Han

## HOSPITAL NAME

Tenafly VC

## REFERRING VET

Dr. Han

## INVOICE

46758

## DATE

8/24/23

## Gastrointestinal

Examination of the **gastrointestinal tract** revealed a stomach and intestine free of stasis, of normal wall thickness, acceptable curvilinear mural detail, and peristaltic activity. Minor fluid filled gastric lumen was present. Small and large intestine demonstrated normal luminal chyme and stool consistency respectively. No obstructive or overt infiltrative disease was noted. No associated abnormal lymphatic activity was noted.

## Pancreas

The base and limbs of the **pancreas** were observed to be largely isoechoic to surrounding omental fat. Some parenchymal remodeling, however, with mild deviation from curvilinear normalcy was observed. Pancreatic duct and capsular irregularities were present consistent with age related changes. If pain upon imaging (+ Murphy sign) was present or if the patient is focally painful in subxiphoid palpation then low-grade smoldering chronic pancreatitis should be suspected.

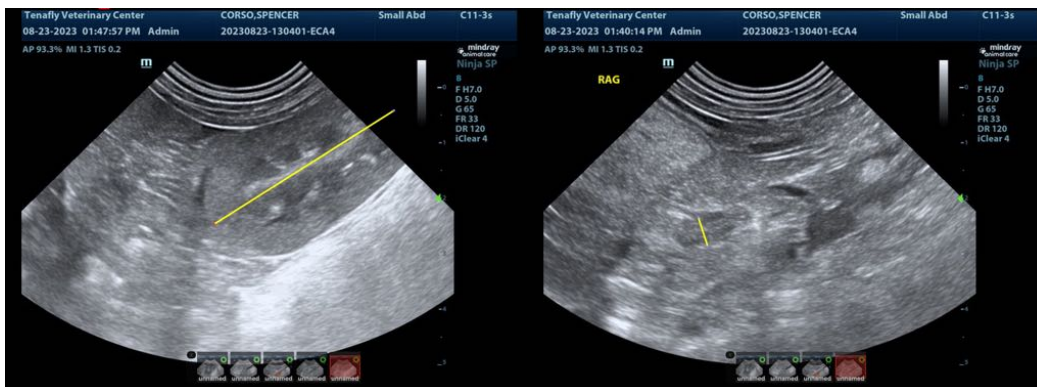
## ULTRASONOGRAPHIC FINDINGS

Geriatric abdomen.

Non-specific, chronic interstitial nephrosis renal pattern.

## INTERPRETATION OF THE FINDINGS & FURTHER RECOMMENDATIONS

There was no evidence of neoplasia. The liver measures normal in size.





**PATIENT**

Spencer Corso

**SPECIES**

Canine

**BREED**

Yorkshire Terrier

**SEX**

Neutered male

**AGE**

11 years

**WEIGHT**

11 lbs

**INTERPRETED BY**

Eric Lindquist, DMV  
DABVP, Cert. IVUSS

**IMAGING PERFORMED BY**

Dr. Han

**HOSPITAL NAME**

Tenafly VC

**REFERRING VET**

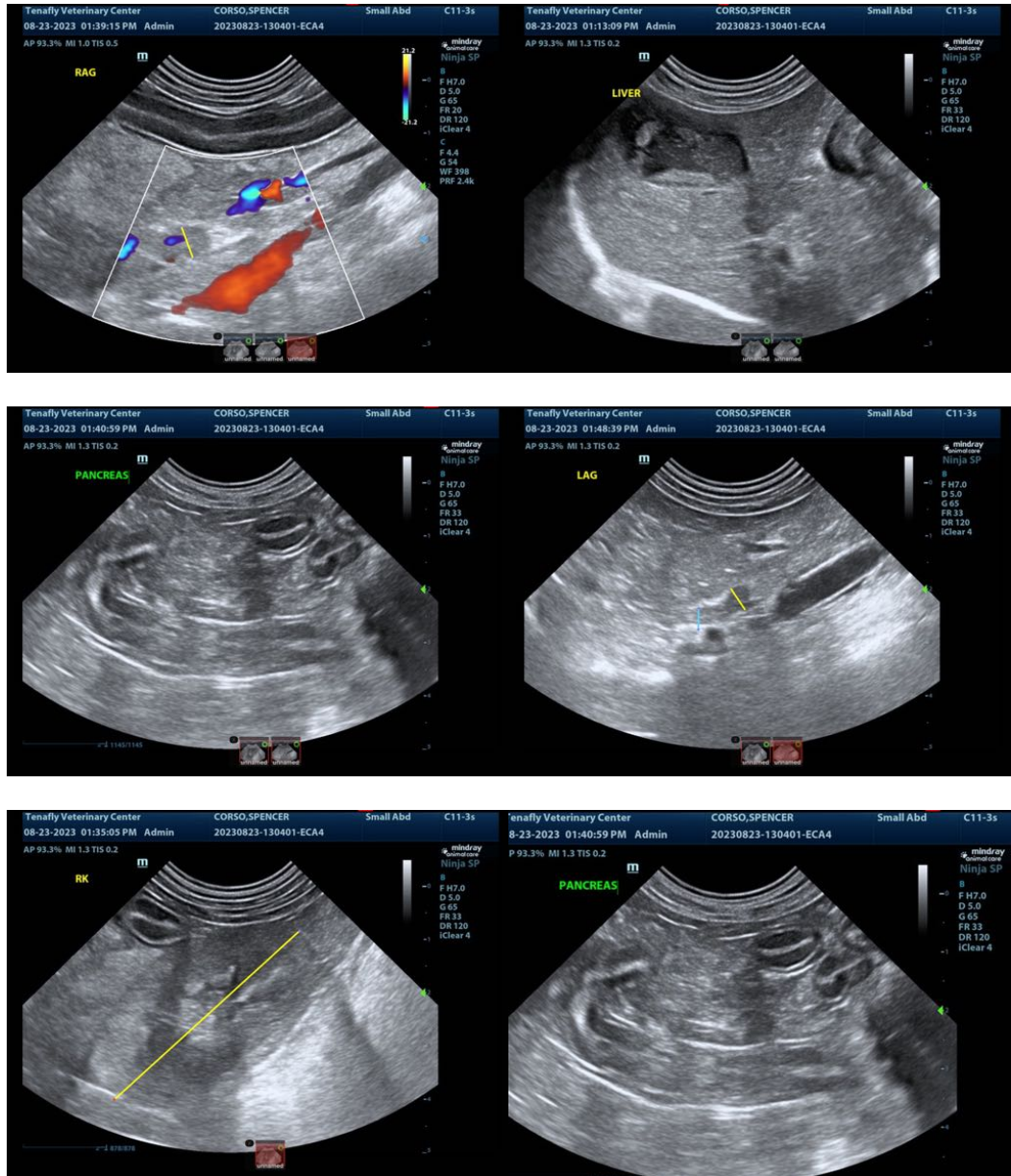
Dr. Han

**INVOICE**

46758

**DATE**

8/24/23



The information and recommendations provided are based on the images presented by the referring veterinarian/sonographer. No evaluation can be communicated regarding pathology that was not visible in the image/video clips provided.

Thank you for this referral. If the clinical or image interpretation does not parallel your findings or if I can be of any further assistance please contact me.

**Eric Lindquist**, DMV, DABVP, Cert. IVUSS, CEO of SonoPath.com  
info@SonoPath.com