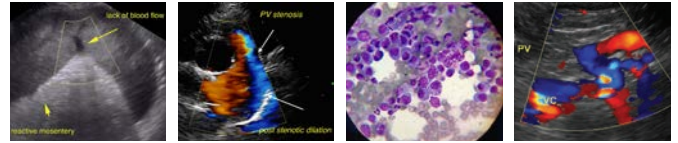


<b>PATIENT</b>	<b>PRESENTING CLINICAL SIGNS</b>
Scooter Thompson	Acute onset of abdominal pain becoming inappetent and recumbent and unable to rise.
<b>SPECIES</b>	Abnormal PE/Chem/CBC/UA Results: ALT greater than 10,000; GGT 442; BUN 39; SDMA mildly elevated. CBC - WBC elevated, neutrophilic leukocytosis, platelets normal, hem normal. Plain film radiographs cranial abdominal mass effect.
Canine	
<b>BREED</b>	<b>ULTRASONOGRAPHIC EXAMINATION OF THE ABDOMEN</b>
Jack Russell Terrier	<b>Urinary System</b>
<b>SEX</b>	The <b>urinary bladder</b> , trigone, and pelvic urethra presented normal thicknesses and normal tone. The ureters were not visible which is normal. No uroliths or sediment were visualized and anechoic urine was present. No evidence of inflammatory or neoplastic changes were noted. Ureteral papillae were normal. The pelvic urethra was imaged 2.0 cm beyond the cystourethral junction.
Neutered Male	
<b>AGE</b>	The <b>kidneys</b> revealed largely normal size and structure, corticomedullary definition and ratio (cortex 1/3 of medulla) were essentially maintained with some age-related loss of curvilinear patterns regarding the capsule and C/M junction. The cortices presented largely uniform texture with some increased echogenicity expected for his age patient. Medullary structure differed distinctly from that of the cortex and no evidence of pelvic dilation was present. Minor mineralization noted. The left kidney measured 4.6 cm. An anechoic cyst or nodule was noted in the right kidney at the dorsal cortex. The right kidney measured 4.4 cm.
13 Years	
<b>WEIGHT</b>	
17.3 Pounds	
<b>INTERPRETED BY</b>	<b>Adrenal Glands</b>
Eric Lindquist, DMV	The <b>left adrenal gland</b> was visualized and recognized as having normal shape, size, position and echogenicity for this breed. The phrenic vasculature, glandular echogenicity and detail were unremarkable. Capsule, cortex, and medullary definition were normal for this age patient. The left adrenal gland measured 0.63 cm.
DABVP, Cert. IVUSS	The <b>right adrenal gland</b> was mildly enlarged with nodular change at the cranial pole. Nodule measured 1.4 cm. The right adrenal gland measured 2.8 cm in length. No evidence of caval invasion.
<b>IMAGING PERFORMED BY</b>	
Harold Mike Beard	
<b>HOSPITAL NAME</b>	<b>Spleen</b>
Animal Care VC	The <b>spleen</b> presented a smooth homogeneous parenchyma hyperechoic to liver and renal cortical parenchyma. The capsule was smooth without noticeable expansion or deviation from within the spleen or adjacent pathology. The splenic vasculature demonstrated normal volume without signs of congestion or thrombosis. No sonographic evidence of acute or chronic inflammatory, neoplastic, or infarctual changes were noted.
<b>REFERRING VET</b>	
Dr. Spivey	
<b>INVOICE</b>	<b>Liver</b>
44926	The <b>liver</b> presented multiple expansive mixed hyperechoic masses occupying the left liver. A separate left-sided cyst or abscess noted, measuring approximately 2.0 cm. The right liver also presented an expansive mass, ill-defined, measuring approximately 6.0 cm. The gallbladder was unremarkable.
<b>DATE</b>	
8/24/23	<b>Gastrointestinal</b>
	Examination of the <b>gastrointestinal tract</b> revealed a stomach and intestine free of stasis, of normal wall thickness, acceptable curvilinear mural detail, and peristaltic activity. Small and large intestine



**PATIENT**

Scooter Thompson

demonstrated normal luminal chyme and stool consistency respectively. No obstructive or overt infiltrative disease was noted. No associated abnormal lymphatic activity was noted.

**SPECIES**

Canine

**Pancreas**

The base and limbs of the **pancreas** were observed to be largely isoechoic to surrounding omental fat. Pancreatic duct and capsular contour were acceptably normal and parenchyma respected normal curvilinear patterns. No overt evidence of active inflammatory or neoplastic disease was noted.

**BREED**

Jack Russell Terrier

**ULTRASONOGRAPHIC FINDINGS**

**SEX**

Neutered Male

- Multicentric hepatic neoplasia with concurrent abscess or cyst
- Nodular right adrenal gland
- Age related renal changes with mineralization

**AGE**

13 Years

**INTERPRETATION OF THE FINDINGS & FURTHER RECOMMENDATIONS**

The pathology does not appear resectable. Coagulation panel and FNA of the various hepatic presentations and cystic structure could all be considered for further definition, yet prognosis is poor. Likely carcinoma.

**WEIGHT**

17.3 Pounds

**INTERPRETED BY**

Eric Lindquist, DMV

DABVP, Cert. IVUSS

**IMAGING PERFORMED BY**

Harold Mike Beard

**HOSPITAL NAME**

Animal Care VC

**REFERRING VET**

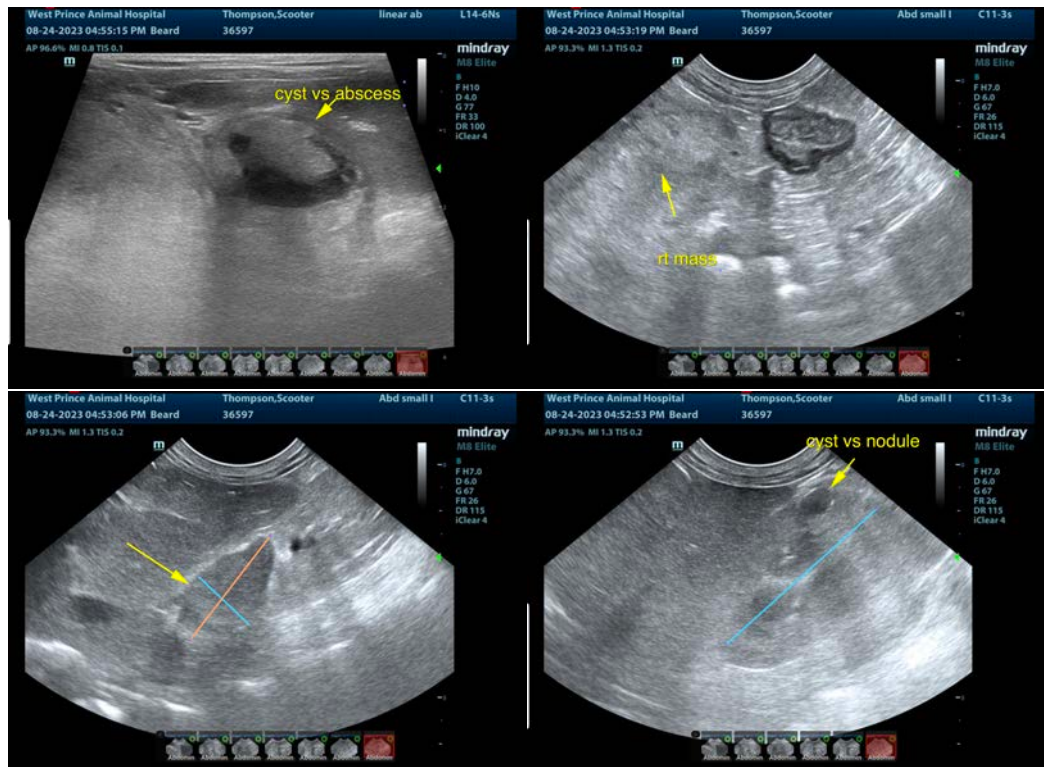
Dr. Spivey

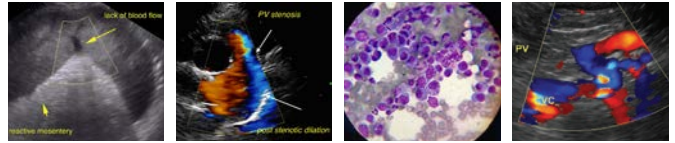
**INVOICE**

44926

**DATE**

8/24/23





**PATIENT**

Scooter Thompson

**SPECIES**

Canine

**BREED**

Jack Russell Terrier

**SEX**

Neutered Male

**AGE**

13 Years

**WEIGHT**

17.3 Pounds

**INTERPRETED BY**

Eric Lindquist, DMV

DABVP, Cert. IVUSS

**IMAGING PERFORMED BY**

Harold Mike Beard

**HOSPITAL NAME**

Animal Care VC

**REFERRING VET**

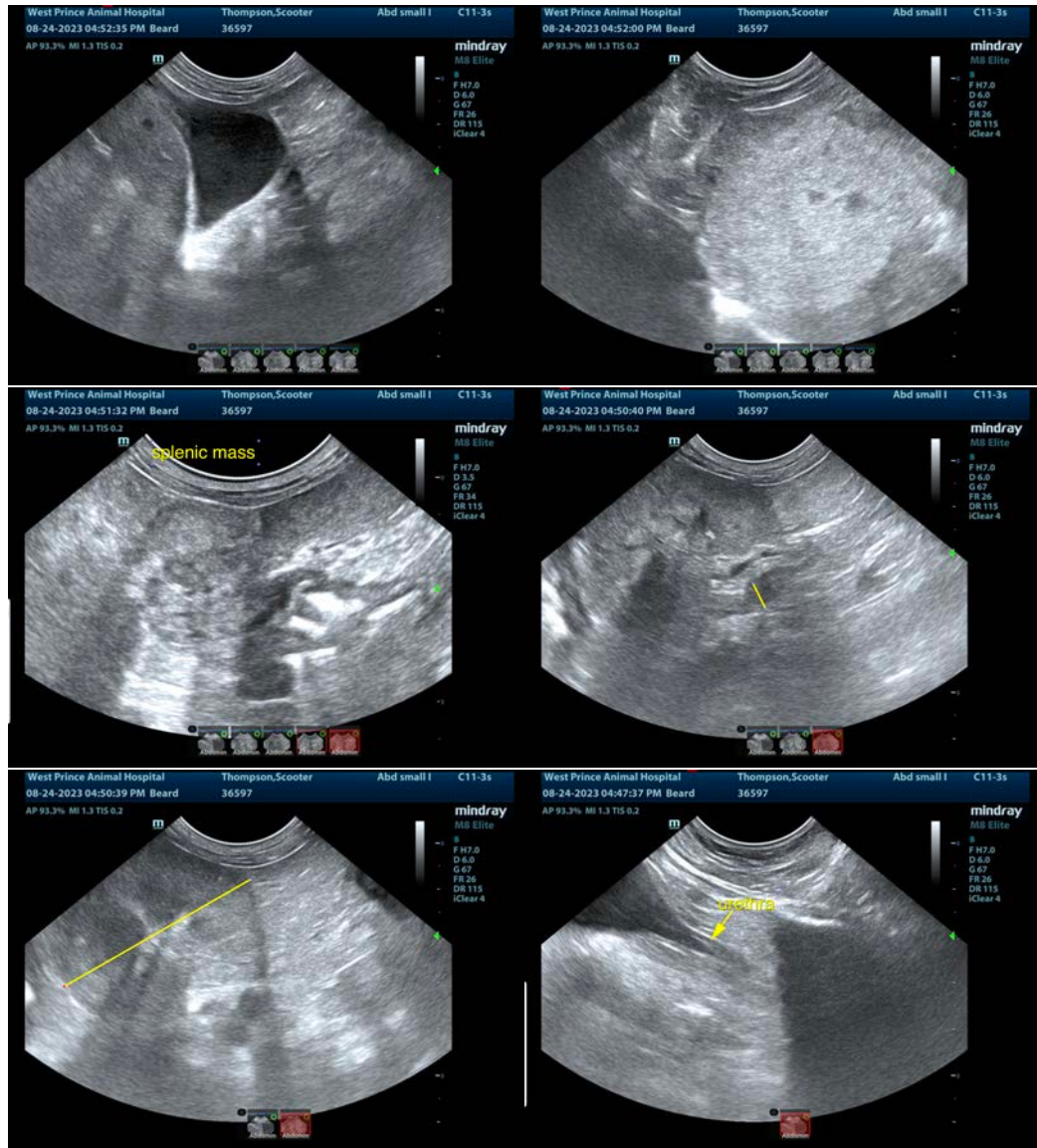
Dr. Spivey

**INVOICE**

44926

**DATE**

8/24/23

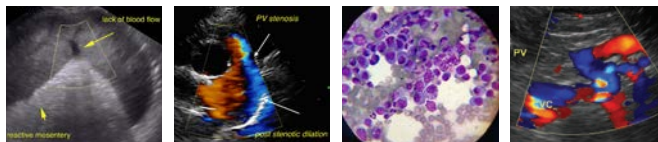


The information and recommendations provided are based on the images presented by the referring veterinarian/sonographer. No evaluation can be communicated regarding pathology that was not visible in the image/video clips provided.

Thank you for this referral. If the clinical or image interpretation does not parallel your findings or if I can be of any further assistance please contact me.

Eric Lindquist, DMV, DABVP, Cert. IVUSS, CEO of SonoPath.com

[info@SonoPath.com](mailto:info@SonoPath.com)



**PATIENT**

Scooter Thompson

**Hepatic Masses, Biliary Adenoma, and Biliary Adenocarcinoma**

**SPECIES**

Canine

<http://www.sonopath.com/HepaticMasses>

**BREED**

Jack Russell Terrier

**SEX**

Neutered Male

**AGE**

13 Years

**WEIGHT**

17.3 Pounds

**Description:** Hepatocellular carcinoma typically manifests in the liver's left lateral lobes, yet may cross over to the right lobes should it derive from the hilus. These masses often present cavitating, necrotic cores that are difficult to distinguish from hepatic abscesses. Vascular channels may also be involved, and bile duct obstruction is often present. Older felines often present solitary or multiple fluid-filled cysts within the hepatic parenchyma. The latter are typically benign cystadenomas and should be differentiated from: cystic adenocarcinoma; hepatic lymphoma (usually diffusely hyperechoic +/- FIV/FelV association); metastatic neoplasia (diffuse hyper- to hypoechoic nodules secondary to mammary adenocarcinoma, splenic hemangiosarcoma, or pancreatic or intestinal adenocarcinoma); benign nodular hyperplasia (accompanied by minimal to no symptoms); hepatic cirrhosis (regenerative nodules); or rare carcinoids, fibrosarcomas, leiomyosarcomas, and osteosarcomas.

**INTERPRETED BY**

Eric Lindquist, DMV

DABVP, Cert. IVUSS

**Clinical Signs:** Possible clinical signs and physical exam findings include cranial abdominal organomegaly, sudden collapse associated with mass rupture, vomiting, ascites, jaundice (severe cases), and hypoglycemia secondary to a paraneoplastic syndrome. Sepsis and fever associated with secondary abscessation of the mass may also occur. Cats usually present with anorexia and lethargy.

**IMAGING PERFORMED BY**

Harold Mike Beard

**Diagnostics:** Routine biochemical analysis primarily shows liver enzyme elevation (i.e., ALT for cellular necrosis; SAP for hepatic congestion; elevated bilirubin for stasis/obstruction; bile acids > 75-100uM/L for significant function impairment). Staging of the disease with 3-view thoracic radiographs is essential, as is conducting a CBC, serum biochemistry, urinalysis, as well as abdominal and possibly also thoracic ultrasounds in order to provide the owner with adequate and well-informed options. Surgical and oncological referral is recommended after a coagulation panel has been assessed and ultrasound-guided biopsies of both normal and pathological tissue have been performed such that the disease is adequately characterized. In cases where surgical resection is impossible, direct chemoembolization of the tumor blood supply could be considered; however, this procedure is only performed at specific tertiary referral locations. Placement of palliative stents into the caudal vena cava (CVC) can be considered as well if compression by an unresectable tumor causes excessive ascitic fluid accumulation. Serum alpha-fetoprotein (AFP) has been shown to reemerge in dogs with malignant hepatobiliary adenocarcinoma. Ultrasound is important to localize the mass in relation to the portal hilus and gallbladder. The portal vein, CVC, aorta, gallbladder, and bile duct should all be identified with respect to the location of the mass to determine resectability. Ultrasound also allows for an examination of possible metastatic sites in the abdomen and, to some degree, in the thorax.

**HOSPITAL NAME**

Animal Care VC

**REFERRING VET**

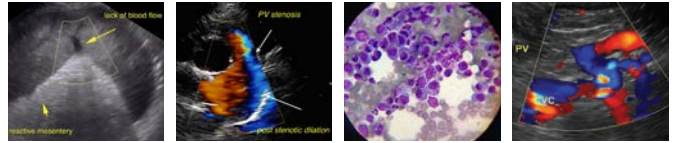
Dr. Spivey

**INVOICE**

44926

**DATE**

8/24/23



**PATIENT**

Scooter Thompson

**SPECIES**

Canine

**BREED**

Jack Russell Terrier

**SEX**

Neutered Male

**AGE**

13 Years

**WEIGHT**

17.3 Pounds

**INTERPRETED BY**

Eric Lindquist, DMV

DABVP, Cert. IVUSS

**IMAGING PERFORMED BY**

Harold Mike Beard

**HOSPITAL NAME**

Animal Care VC

**REFERRING VET**

Dr. Spivey

**INVOICE**

44926

**DATE**

8/24/23

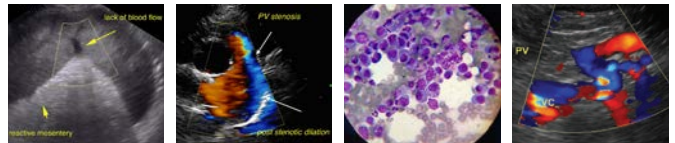
**Treatment:** Hepatic adenoma, hepatoma, and adenocarcinoma are usually amenable to surgical resection via hepatic lobectomy should the pathology be isolated to single-lobe progression. Multi-lobar presentation may be amenable to lobectomy and debulking; this will be determined further during surgical consultation. These tumors tend to displace unaffected parenchyma, allowing for relatively straightforward surgical resection. Up to 80% of the liver can be removed without long-term functional deficits. Blood transfusions may be necessary during surgery. The development and implementation of the LDS™ stapler has helped to streamline the procedure. Most carcinomas have metastasized by the time of diagnosis yet tend to be slow-growing; thus, it may be possible for a certain quality of life to be attained via surgical resection. Hepatic hemangiosarcoma has usually metastasized at the time of diagnosis and carries a much poorer prognosis. Surgical resection and chemotherapy are recommended, but considered by many to be an “aggressive” approach.

Preliminary trials have shown that gemcitabine is well tolerated and yields good responses in cases of hepatic as well as pancreatic, colonic, and gastric carcinomas. Myelosuppression, however, remains the key issue. Doxorubicin, cyclophosphamide, and fluorouracil combinations have also proven fruitful.

Nonsteroidal anti-inflammatory drugs (NSAIDs) have been demonstrated to have an anti-neoplastic effect due to their inhibition of COX-2 in certain tumor cells. The end product of the cyclooxygenase cascade is prostaglandin E2, which, when expressed in tumor cell lines—and not expressed in normal cells of that particular cell line—results in inhibited apoptosis, immunosuppression, and increased angiogenesis, proliferation, and invasiveness. Inappropriate increases in COX-2 expression have been documented in certain neoplasias, including squamous cell carcinoma, mammary carcinomas, prostatic carcinoma, malignant melanoma, and transitional cell carcinoma.

Metronomic chemotherapy is currently being investigated and compared to traditional chemotherapy protocols; it is thought to be at least as effective as the latter with substantially less toxic side effects. Metronomic chemotherapy is the practice of uninterrupted administration of low-dose cytotoxic drugs at regular and frequent intervals, as opposed to high-dose, shorter-term protocols characteristic of traditional chemotherapeutic practices. The lower dose allows for long-term administration without toxic side effects, and has been postulated as providing longer remission intervals. Moreover, it has the benefit of minimizing the intervals between drug regimens—the period during which tumor cells may repopulate the area—as well as the chance of developing multi-drug resistant genes. Metronomic chemotherapy has been used successfully in human patients who have undergone previous chemotherapy administration. It is thought to destroy endothelial cells, thereby retarding angiogenesis and targeting regulatory T cells. To date, there have only been a few small clinical trials in veterinary patients, and these have focused on animals that have hemangiosarcoma and soft tissue sarcomas.

**Conclusion:** With respect to hepatic neoplasia, many surgical and chemotherapeutic options exist; however, it is best to consult with a local board certified oncologist who can help determine the best course of action.



**PATIENT**

Scooter Thompson

**SPECIES**

Canine

**BREED**

Jack Russell Terrier

**SEX**

Neutered Male

**AGE**

13 Years

**WEIGHT**

17.3 Pounds

**INTERPRETED BY**

Eric Lindquist, DMV  
DABVP, Cert. IVUSS

**IMAGING  
PERFORMED BY**

Harold Mike Beard

**HOSPITAL NAME**

Animal Care VC

**REFERRING VET**

Dr. Spivey

**INVOICE**

44926

**DATE**

8/24/23

**References:**

Biller BJ. Teaching T cells to target tumors: towards the design of more effective cancer vaccines. Proceedings from the American College of Veterinary Internal Medicine Forum, Denver, CO, June 15-18, 2011.

Biller BJ, Guth A, Burton JH, Dow SW. Decreased ratio of CD8+ T cells to regulatory T cells associated with decreased survival in dogs with osteosarcoma. *J Vet Intern Med* 2010;24(5):1118-23.

Elmslie RE, Glawe P, Dow SW. Metronomic therapy with cyclophosphamide and piroxicam effectively delays tumor recurrence in dogs with incompletely resected soft tissue sarcomas. *J Vet Intern Med* 2008;22(6):1373-79.

Lana S, U'Ren L, Plaza S, et al. Continuous low-dose oral chemotherapy for adjuvant therapy of splenic hemangiosarcoma in dogs. *J Vet Intern Med* 2007;21(4):764-69.

Milner RJ. Do NSAIDs make a difference in cancer? Proceedings from the American College of Veterinary Internal Medicine Forum, Denver, CO, June 15-18, 2011.