

PATIENT

Archer Hendricks

SPECIES

Canine

BREED

Great Dane

SEX

Neutered Male

AGE

6 Years 8 Months

WEIGHT

137

INTERPRETED BY

Eric Lindquist, DMV

DABVP, Cert. IVUSS

IMAGING PERFORMED BY

Cathy Carter

HOSPITAL NAME

Willamette VH

REFERRING VET

Dr. Roberta Porter

INVOICE

44925

DATE

8/24/23

PRESENTING CLINICAL SIGNS

Hx of cystine urolithiasis and cystotomy one month ago at another clinic. He has been dribbling urine since. Presented here one week ago with hematuria and dribbling. U/A -UTI- treated at rDVM with TMS. Hematuria resolved. Still dribbling urine. Targeted U/S here, urinary bladder very full. Attempted to place urinary catheter 12f. Hard obstruction at 25cm

Abnormal PE/Chem/CBC/UA Results: Globulin 4 g/dL, urine culture pending

LIMITED ULTRASONOGRAPHIC EXAMINATION

The **urinary bladder** presented some dependent and suspended debris and a minor amount of sand.

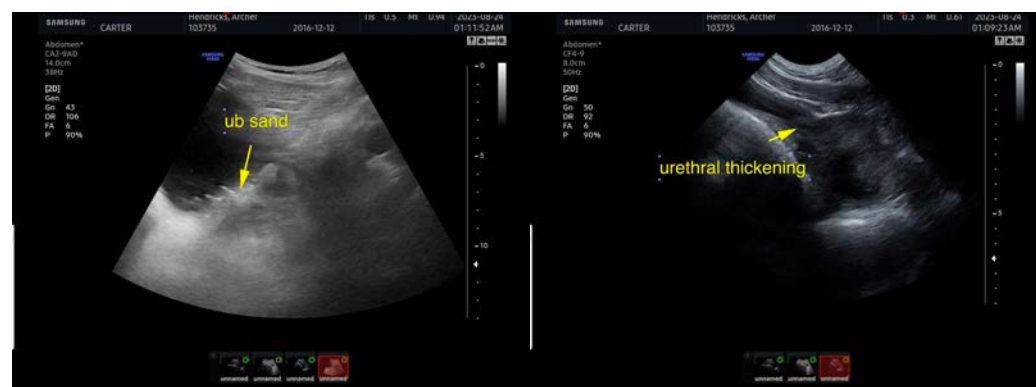The **prostate** was enlarged with a 2.0 cm mildly echogenic cyst. If the patient was neutered recently, then this may be residual abscess. However, underlying carcinoma is also possible. There is a minor potential for tumor trailing if carcinoma is present upon FNA. Proximal pre-prostatic urethral thickening noted.

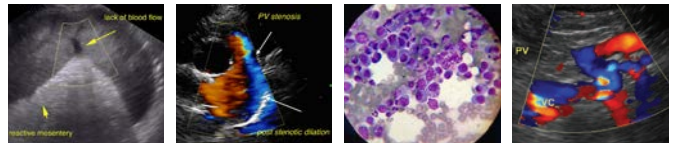
ULTRASONOGRAPHIC FINDINGS

- Enlarged prostate with cyst or abscess with mild pre-prostatic urethral thickening
- Urinary bladder debris and sand

INTERPRETATION OF THE FINDINGS & FURTHER RECOMMENDATIONS

Ultrasound guided FNA of the prostate and drainage and culture of the cystic component recommended. Prognosis is guarded. Possible carcinoma versus residual abscessation from prior pathology.





PATIENT

Archer Hendricks

SPECIES

Canine

BREED

Great Dane

SEX

Neutered Male

AGE

6 Years 8 Months

WEIGHT

137

INTERPRETED BY

Eric Lindquist, DMV
DABVP, Cert. IVUSS

IMAGING PERFORMED BY

Cathy Carter

HOSPITAL NAME

Willamette VH

REFERRING VET

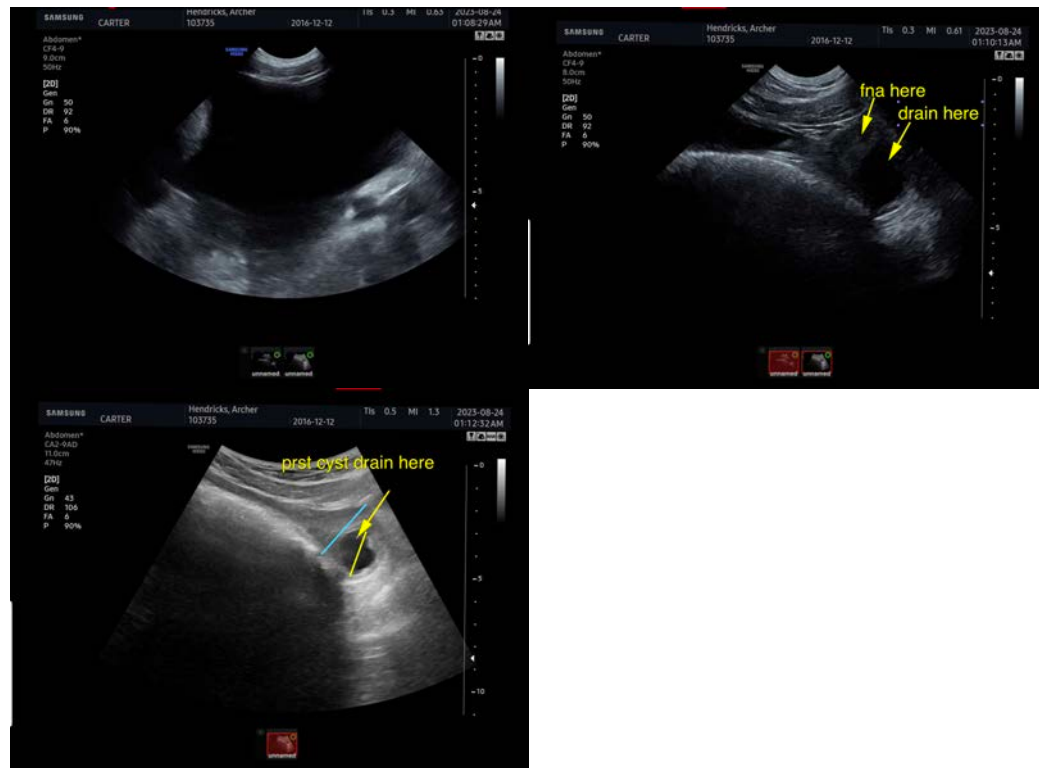
Dr. Roberta Porter

INVOICE

44925

DATE

8/24/23



The information and recommendations provided are based on the images presented by the referring veterinarian/sonographer. No evaluation can be communicated regarding pathology that was not visible in the image/video clips provided.

Thank you for this referral. If the clinical or image interpretation does not parallel your findings or if I can be of any further assistance please contact me.

Eric Lindquist, DMV, DABVP, Cert. IVUSS, CEO of SonoPath.com

info@SonoPath.com