



PATIENT

Pepper Joseph

PRESENTING CLINICAL SIGNS

History: chronic fb/pancreatitis

SPECIES

Canine

ULTRASONOGRAPHIC EXAMINATION OF THE ABDOMEN

Urinary System

BREED

Pit Mix

The **urinary bladder**, trigone, and pelvic urethra presented normal thicknesses and normal tone. The ureters were not visible which is normal. No uroliths or sediment were visualized and anechoic urine was present. No evidence of inflammatory or neoplastic changes was noted. Ureteral papillae were normal.

SEX

Spayed female

The **kidneys** revealed largely normal size and structure, corticomedullary definition and ratio (cortex 1/3 of medulla) were essentially maintained with some age-related loss of curvilinear patterns regarding the capsule and C/M junction. The cortices presented largely uniform texture with some increased echogenicity expected for his age patient. Medullary structure differed distinctly from that of the cortex and no evidence of pelvic dilation was present. The right kidney measured 5.22 cm. The left kidney measured 5.5 cm.

AGE

8 years

WEIGHT

51.5 lbs

Adrenal Glands

Both **adrenal glands** were visualized and recognized as having normal shape, size, position and echogenicity for this breed. The phrenic vasculature, glandular echogenicity and detail were unremarkable. Capsule, cortex, and medullary definition were normal for this age patient. The left adrenal gland measured 2.57 x 0.71 cm at the caudal pole and 0.62 cm at the cranial pole. The right adrenal gland measured 2.58 x 1.32 cm at the cranial pole and 0.73 cm at the caudal pole.

INTERPRETED BY

Eric Lindquist, DMV
DABVP, Cert. IVUS

IMAGING PERFORMED BY

Jenn

Spleen

The **spleen** presented a smooth homogeneous parenchyma hyperechoic to liver and renal cortical parenchyma. The capsule was smooth without noticeable expansion or deviation from within the spleen or adjacent pathology. The splenic vasculature demonstrated normal volume without signs of congestion or thrombosis. No sonographic evidence of acute or chronic inflammatory, neoplastic, or infarctual changes was noted.

HOSPITAL NAME

Rockaway AH

REFERRING VET

Dr. Maniar

Liver

The **liver** images submitted revealed subjectively normal liver size, contour, and structure. Parenchymal echogenicity was naturally coarse and hypoechoic to the spleen. Vascular and biliary tracts were of normal volume with no evidence of congestion. The gallbladder presented acceptably thin walls with primarily anechoic content. The cystic and common bile ducts were normal. No pathological hepatic lymphadenopathy was evident. No overt structural evidence of inflammatory, infiltrative or regenerative pathology was evident.

INVOICE

32514

DATE

8/23/22



PATIENT

Gastrointestinal

Pepper Joseph

The **stomach** revealed a persistent gastric foreign body that measured 6.0 cm. This is consistent with hard ball or similar material. The small intestines and colon were unremarkable.

SPECIES

Canine

Pancreas

BREED

Pit Mix

The base and limbs of the **pancreas** were observed to be largely isoechoic to surrounding omental fat. Pancreatic duct and capsular contour were acceptably normal and parenchyma respected normal curvilinear patterns. No overt evidence of active inflammatory or neoplastic disease was noted.

SEX

Spayed female

ULTRASONOGRAPHIC FINDINGS

Gastric foreign body.

AGE

8 years

INTERPRETATION OF THE FINDINGS & FURTHER RECOMMENDATIONS

Gastrotomy is indicated in this patient along with biopsies to rule out underlying disease. Structurally the GI tract appears unremarkable other than the gastric foreign body.

WEIGHT

51.5 lbs

INTERPRETED BY

Eric Lindquist, DMV
DABVP, Cert. IVUSS

IMAGING PERFORMED BY

Jenn

HOSPITAL NAME

Rockaway AH

REFERRING VET

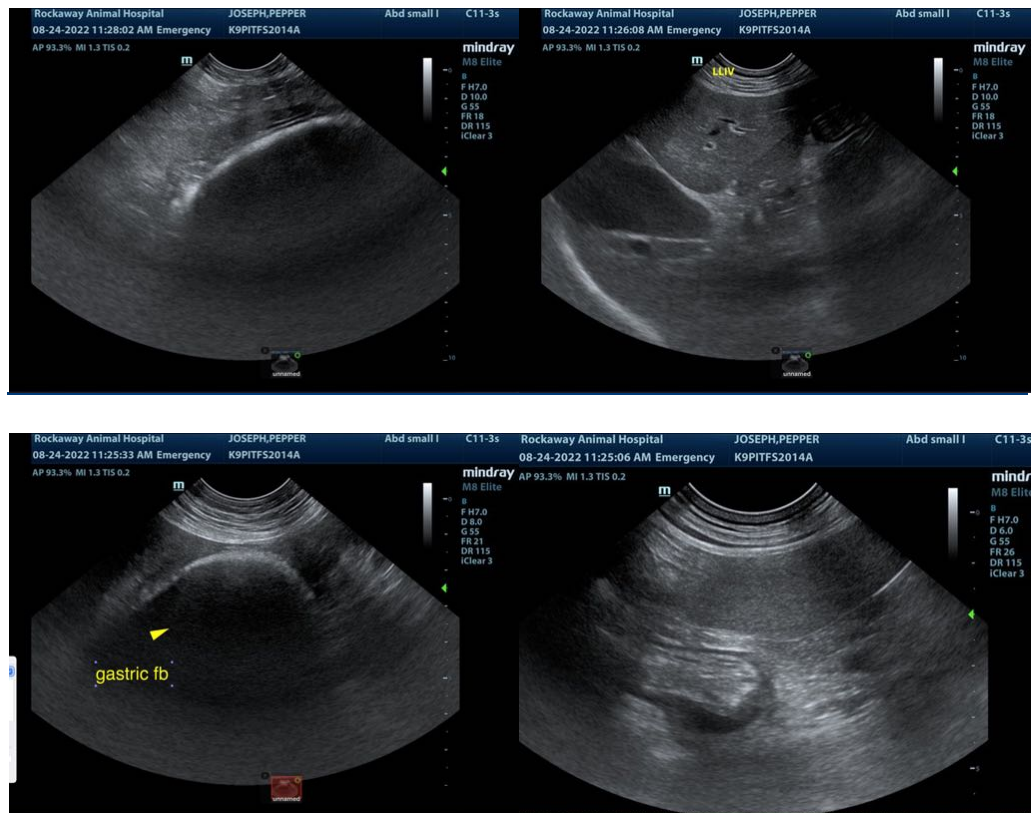
Dr. Maniar

INVOICE

32514

DATE

8/23/22





PATIENT

Pepper Joseph

SPECIES

Canine

BREED

Pit Mix

SEX

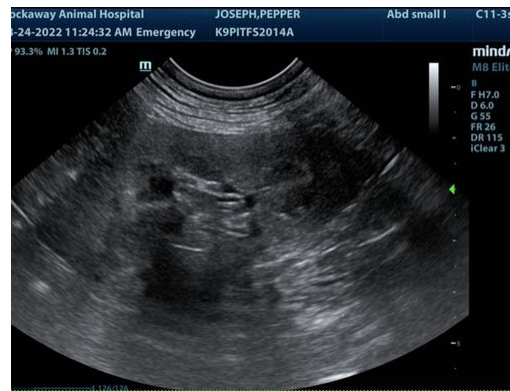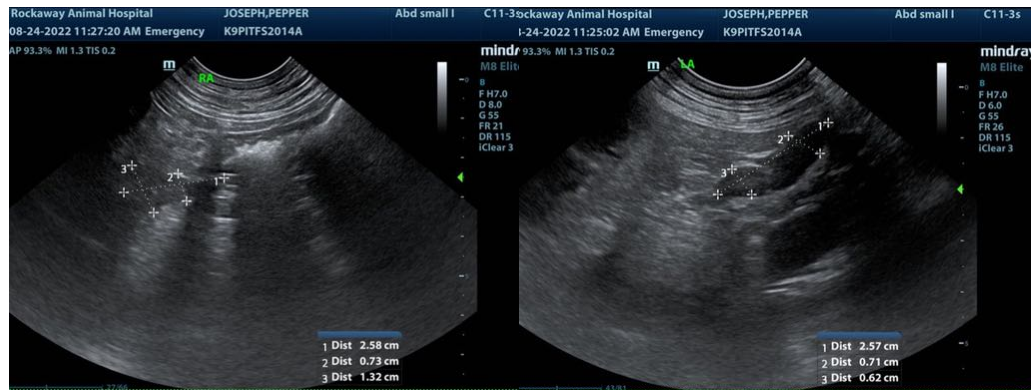
Spayed female

AGE

8 years

WEIGHT

51.5 lbs



INTERPRETED BY

Eric Lindquist, DMV
DABVP, Cert. IVUSS

IMAGING PERFORMED BY

Jenn

HOSPITAL NAME

Rockaway AH

REFERRING VET

Dr. Maniar

INVOICE

32514

DATE

8/23/22

The information and recommendations provided are based on the images presented by the referring veterinarian/sonographer. No evaluation can be communicated regarding pathology that was not visible in the image/video clips provided.

Thank you for this referral. If the clinical or image interpretation does not parallel your findings or if I can be of any further assistance please contact me.

Eric Lindquist, DMV, DABVP, Cert. IVUSS, CEO of SonoPath.com
info@SonoPath.com