


PATIENT PRESENTING CLINICAL SIGNS

Sugar Lehnert Ascites, lethargy, heart murmur.

SPECIES ULTRASONOGRAPHIC EXAMINATION OF THE HEART

Canine

Cardiac presentation in this patient presented severe volume overload and chronic left atrial enlargement with mitral valve prolapse. Severe mitral and tricuspid insufficiency was noted with pulmonary hypertension. Tricuspid insufficiency measured 5.37 m/sec and mitral insufficiency velocity measured 6.0 m/sec. Periodic arrhythmia was noted during the exam. There was no pericardial or pleural effusion was noted. The contractility appeared adequate with mild ventricular overload.

BREED

Shih Tzu

SEX

Female

AGE

10 years

INTERPRETED BY

 Eric Lindquist, DMV
 DABVP, Cert. IVUSS

IMAGING PERFORMED BY

 Eric Lindquist, DMV
 DABVP, Cert. IVUSS

CANINE	MR	TR	LA/AO	LA/AO	FS	EF	EPSS
CARDIAC PARAMETERS	VMAX (m/s)	VMAX (m/s)	(Boon method)	(Heart Base; Swe)	(%)	(%)	(cm)
NORMAL PARAMETER	4.5-5.5	<2.7	1.3	<1.6	28-40	40-100	<0.6
PATIENT	6.0	5.37	1.6		46	79	NM
CANINE	HR	AV	PV	BODY WEIGHT	LA	LVIDd	LVIDs
CARDIAC PARAMETERS	(BPM)	VMAX (m/s)	MAX (m/s)	(kg)	2D short axis Base view (cm)	Avg; 2D and m-mode short axis (cm)	Avg; 2D and m-mode short axis (cm)
NORMAL PARAMETER	50-100	0.7-1.7	0.7-1.6				
PATIENT	153	1.1	0.5		4.79 max	3.02	

HOSPITAL NAME

Byram

ULTRASONOGRAPHIC FINDINGS

Advanced stage C1 valvular disease with mitral prolapse.

REFERRING VET

Dr. Abdul-Chani

Chronic left atrial enlargement.

Left and right sided heart failure.

INVOICE

91438

INTERPRETATION OF THE FINDINGS & FURTHER RECOMMENDATIONS
DATE

8/24/21

I recommend adding Pimobendan at 0.3 mg/kg b.i.d., ace inhibitor at 0.5 mg/kg s.i.d. progressing to b.i.d. and Spironolactone at 1-2 mg/kg b.i.d. to the current Lasix dose. Blood pressure measurements are warranted. EKG is warranted ideally. Recheck echocardiogram is recommended in 2 weeks with potential addition of Sildenafil depending upon response to first level medications. Very guarded prognosis. The patient is at risk for sudden death.



PATIENT

Sugar Lehnert

SPECIES

Canine

BREED

Shih Tzu

SEX

Female

AGE

10 years

INTERPRETED BY

Eric Lindquist, DMV
DABVP, Cert. IVUSS

IMAGING PERFORMED BY

Eric Lindquist, DMV
DABVP, Cert. IVUSS

HOSPITAL NAME

Byram

REFERRING VET

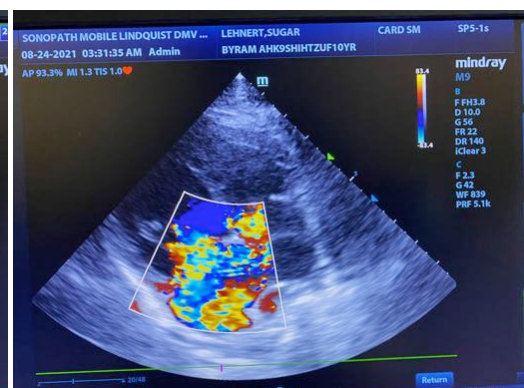
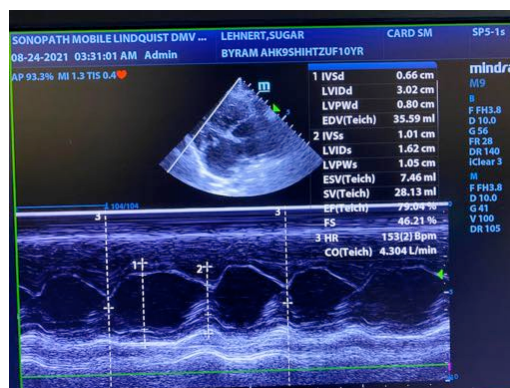
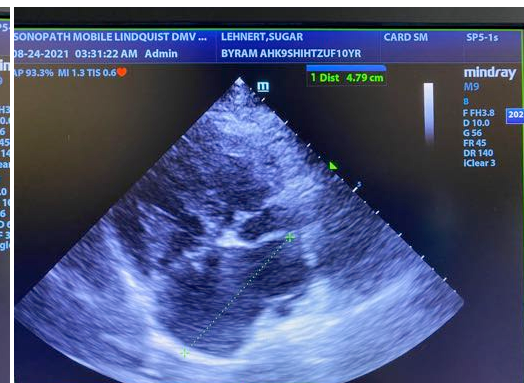
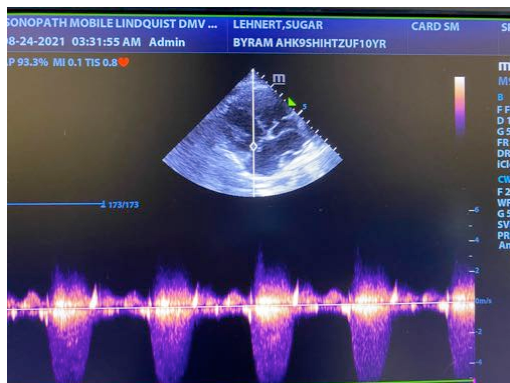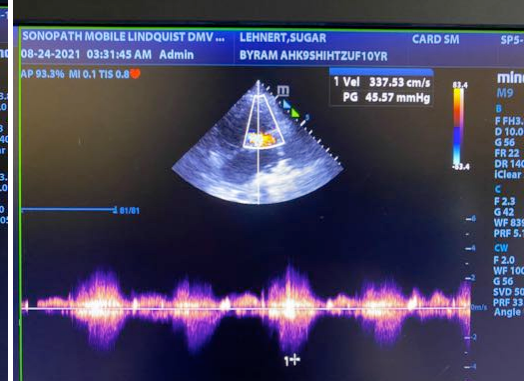
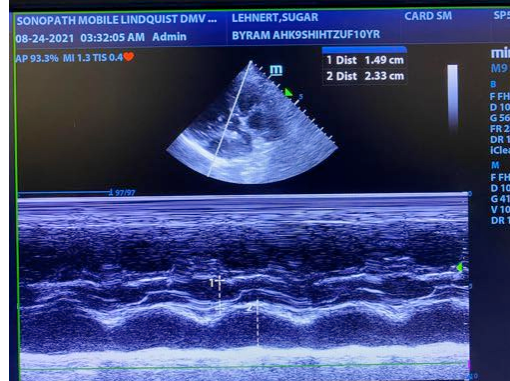
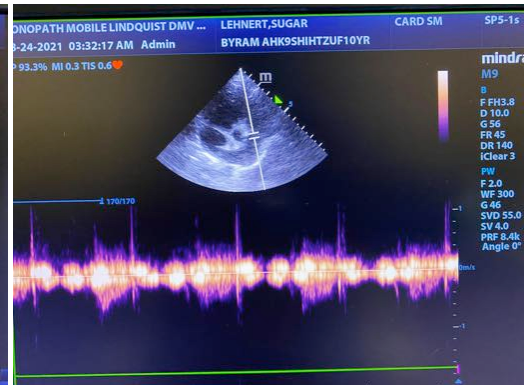
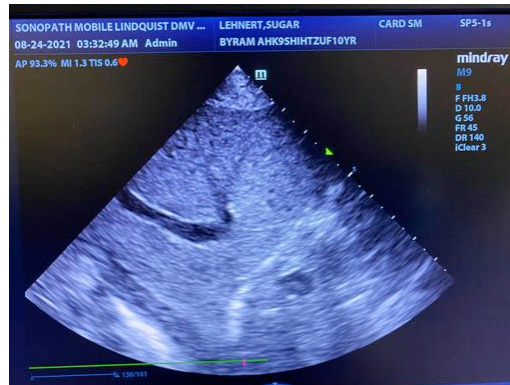Dr. Abdul-Chani

INVOICE

91438

DATE

8/24/21





PATIENT

Sugar Lehnert

The information and recommendations provided are based on the images presented by the referring veterinarian. No evaluation can be communicated regarding pathology that was not visible in the image/video clips provided.

SPECIES

Canine

Thank you for this referral. If the clinical or image interpretation does not parallel your findings or if I can be of any further assistance please contact me.

BREED

Shih Tzu

Eric Lindquist, DMV, DABVP, Cert. IVUSS, CEO of SonoPath.com
Info@SonoPath.com

SEX

Female

AGE

10 years

INTERPRETED BY

Eric Lindquist, DMV
DABVP, Cert. IVUSS

**IMAGING
PERFORMED BY**

Eric Lindquist, DMV
DABVP, Cert. IVUSS

HOSPITAL NAME

Byram

REFERRING VET

Dr. Abdul-Chani

INVOICE

91438

DATE

8/24/21