
PATIENT PRESENTING CLINICAL SIGNS

Rikki Yachiw Follow up US. About the same at home. Currently being treated with Clopidogrel 75mg - 1/4 SID, Lasix 12.5mg BID, Pimobendan 1.25mg BID. On Tobradex for his eyes as well. Previous US July 8, 2021
 Abnormal PE/Chem/CBC/UA Results: n/a

SPECIES

Feline

ULTRASONOGRAPHIC EXAMINATION OF THE HEART
BREED
 Exotic Shorthair

SEX

Neutered Male

AGE

11 Years

WEIGHT

3.15 kg

FELINE CARDIAC PARAMETERS	BODY WEIGHT (kg)	HR (BPM)	IVSd (cm)	LVIDd (cm)	LVWd (cm)	FS (%)	EF (%)
NORMAL PARAMETER	-----	150-240	0.3-0.6	1.0-2.1	0.25-0.6	35-67	80-100
PATIENT		NM	0.51	1.57	0.6	33	66
FELINE CARDIAC PARAMETERS	LA/AO (Boon)	LA/AO HEART BASE (Sisson)	LA 2D 4-chamber long axis AS to FW (Sisson) (cm)	LVOT VEL. (m/s)	RVOT VEL. (m/s)	IVRT (m/)	
NORMAL PARAMETER	<1.5	0.88-1.79	0.7-1.7	<1.6	<1.3	40-60	
PATIENT	2.3	2.5		0.80	0.50	NM	
Adapted from June Boon, Veterinary Echocardiography, 1998 Sisson D et al. JVIM 1991; 5: 232, Jacobs et al. Am J Vet Res 1985; 46:1705							

INTERPRETED BY

 Eric Lindquist, DMV
 DABVP, Cert. IVUSS

IMAGING PERFORMED BY

Crystal Hill

HOSPITAL NAME

Hartzel AH

REFERRING VET

Dr. Hobbs

INVOICE

24882

DATE

8/24/21

Cardiac Presentation

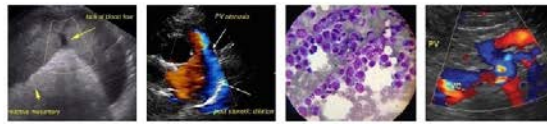
The cardiac presentation presented persistent severe volume overload of the right and left atria with smoke in the left atrium. Hypocontractility noted with the left ventricular free wall. Septal free wall thickness were upper limits of normal. Mitral and tricuspid insufficiency noted. No pericardial or pleural effusion noted. A moderate amount of myocardial remodeling present. Trace amount of pericardial effusion noted without pleural effusion. Some lung rockets were present, suggestive for alveolar disease

ULTRASONOGRAPHIC FINDINGS

- Unclassified cardiomyopathy with bilateral atrial enlargement (severe)

INTERPRETATION OF THE FINDINGS & FURTHER RECOMMENDATIONS

Recommend continuation of the current protocol with Lasix and Pimobendan as well as Clopidogrel. Recommend adding ACE inhibitor if the patient will tolerate it at, 0.5 mg/kg SID of Enalapril or Benazepril. Prognosis is guarded to poor long-term. However, some quality of life may still be available.



PATIENT

Rikki Yachiw

SPECIES

Feline

BREED

Exotic Shorthair

SEX

Neutered Male

AGE

11 Years

WEIGHT

3.15 kg

INTERPRETED BY

Eric Lindquist, DMV
 DABVP, Cert. IVUSS

**IMAGING
 PERFORMED BY**

Crystal Hill

HOSPITAL NAME

Hartzel AH

REFERRING VET

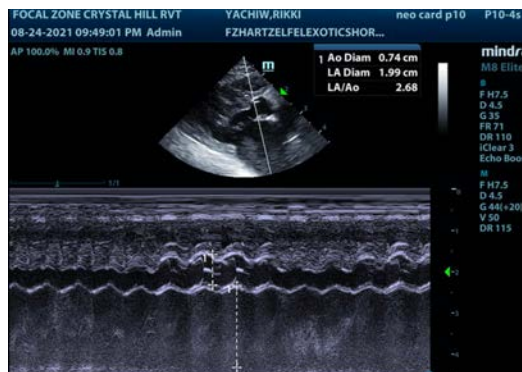
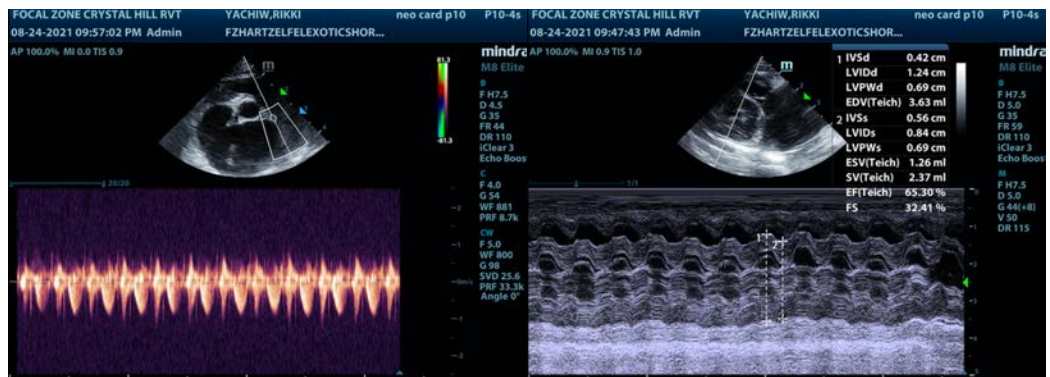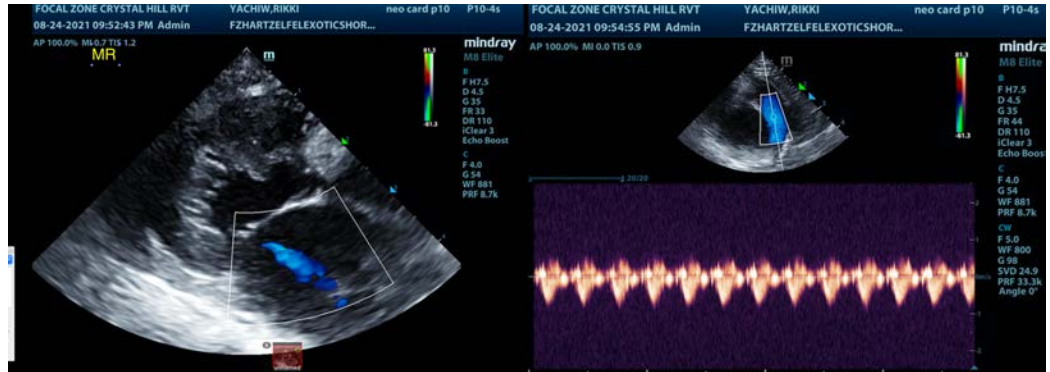
Dr. Hobbs

INVOICE

24882

DATE

8/24/21



The information and recommendations provided are based on the images presented by the referring veterinarian. No evaluation can be communicated regarding pathology that was not visible in the image/video clips provided.

Thank you for this referral. If the clinical or image interpretation does not parallel your findings or if I can be of any further assistance please contact me.

Eric Lindquist, DMV, DABVP, Cert. IVUSS, CEO of SonoPath.com
 Eric.Lindquist@SonoPath.com