



PATIENT PRESENTING CLINICAL SIGNS

Pindari McCollum Low cholesterol, elevated ALT and mild leukocytosis. blood work will be emailed.

SPECIES ULTRASONOGRAPHIC EXAMINATION OF THE ABDOMEN

Reptile Urinary System

The **urinary bladder** revealed a calculus measuring approximately 3.0 mm. Some suspended debris was noted as well.

BREED The **kidneys** were uniform. No evidence of pathology.

Bearded Dragon

Adrenal Glands

SEX The **adrenal glands** were not visualized.

Intact Male

Spleen

The **spleen** presented a smooth homogeneous parenchyma hyperechoic to liver and renal cortical parenchyma. The capsule was smooth without noticeable expansion or deviation from within the spleen or adjacent pathology. The splenic vasculature demonstrated normal volume without signs of congestion or thrombosis. No sonographic evidence of acute or chronic inflammatory, neoplastic, or infarctual changes were noted.

AGE

4 Years

WEIGHT

1 Pound

Liver

The **liver** was largely uniform. The gallbladder measured approximately 1.5 cm x 1.0 cm with a mild amount of debris and biliary sand, non-obstructive at the time of the sonogram.

INTERPRETED BY

Eric Lindquist, DMV,
DABVP, Cert. IVUSS

Gastrointestinal

The **stomach** presented a moderate amount of ingesta, consistent with post-prandial presentation. The small intestine was largely empty. Some shadowing material was noted in the stomach.

IMAGING PERFORMED BY

Heidi Putnam

Pancreas

The base and limbs of the **pancreas** were observed to be largely isoechoic to surrounding omental fat. Pancreatic duct and capsular contour were acceptably normal and parenchyma respected normal curvilinear patterns. No overt evidence of active inflammatory or neoplastic disease was noted.

HOSPITAL NAME

Santa Clara AH

Free Abdomen

A trace amount of free fluid was noted, likely physiologic for this species.

REFERRING VET

Dr. Zulaf

Rapid view of the heart revealed normal contractility and volume.

ULTRASONOGRAPHIC FINDINGS

- Bladder concretion – non-obstructive
- Minor biliary sand
- Unremarkable abdomen otherwise

DATE

8/24/21

INVOICE

24881



PATIENT

Pindari McCollum

INTERPRETATION OF THE FINDINGS & FURTHER RECOMMENDATIONS

No obvious evidence of neoplasia. Nutritional history should be considered given the minor amount of biliary sand present.

SPECIES

Reptile

BREED

Bearded Dragon

SEX

Intact Male

AGE

4 Years

WEIGHT

1 Pound

INTERPRETED BY

Eric Lindquist, DMV,
DABVP, Cert. IVUSS

IMAGING PERFORMED BY

Heidi Putnam

HOSPITAL NAME

Santa Clara AH

REFERRING VET

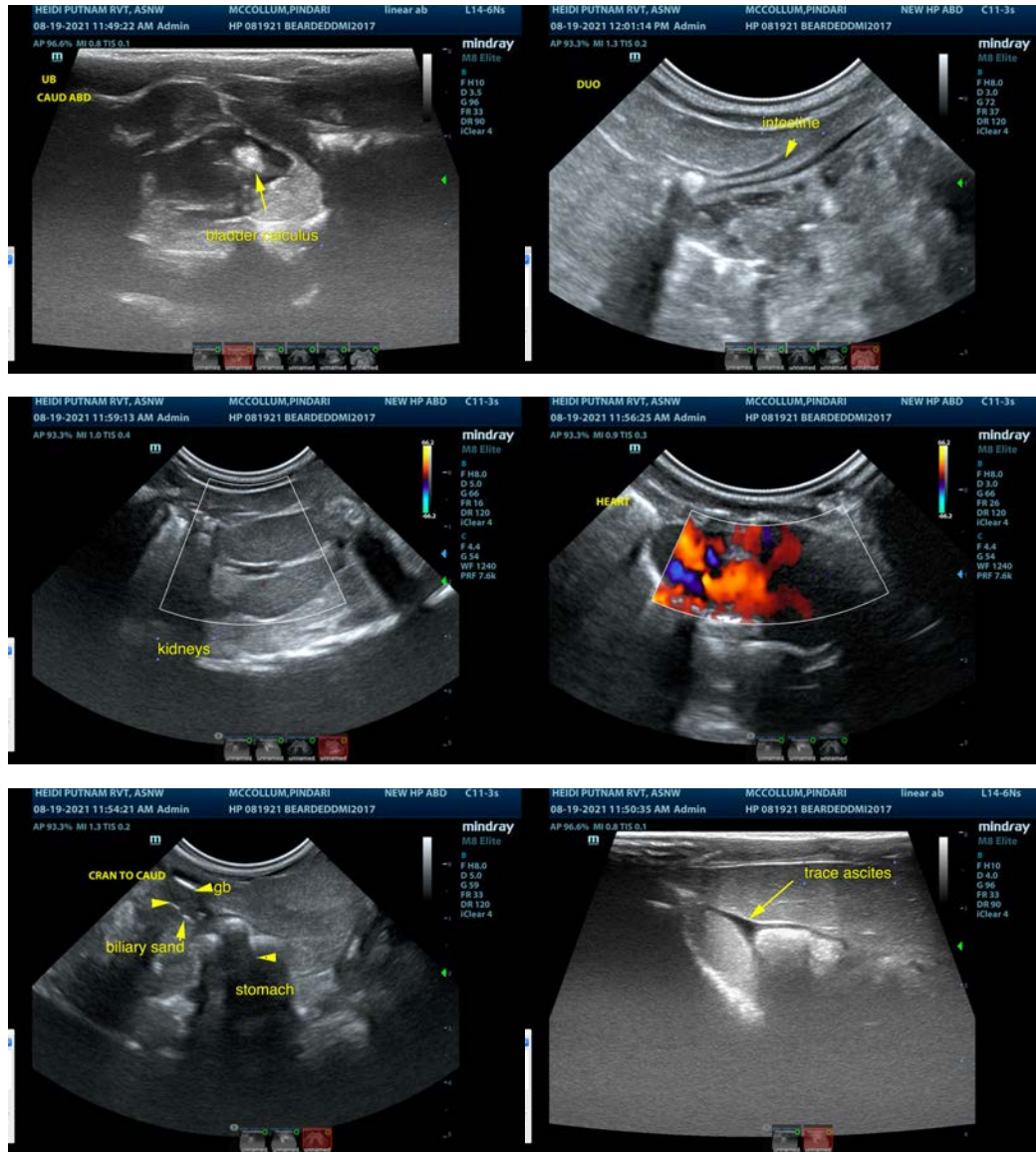
Dr. Zulaf

DATE

8/24/21

INVOICE

24881





PATIENT

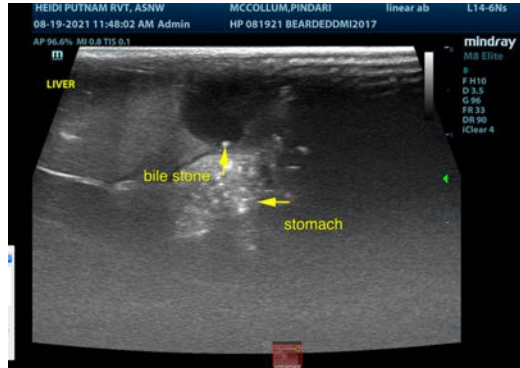Pindari McCollum

SPECIES

Reptile

BREED

Bearded Dragon



SEX

Intact Male

AGE

4 Years

WEIGHT

1 Pound

The information and recommendations provided are based on the images presented by the referring veterinarian. No evaluation can be communicated regarding pathology that was not visible in the image/video clips provided.

Thank you for this referral. If the clinical or image interpretation does not parallel your findings or if I can be of any further assistance please contact me.

Eric Lindquist, DMV, DABVP, Cert. IVUSS

CEO of Sonopath.com

Eric.Lindquist@SonoPath.com

INTERPRETED BY

Eric Lindquist, DMV, DABVP, Cert. IVUSS

IMAGING PERFORMED BY

Heidi Putnam

HOSPITAL NAME

Santa Clara AH

REFERRING VET

Dr. Zulaf

DATE

8/24/21

INVOICE

24881