



PATIENT

Ozer Bernheim

PRESENTING CLINICAL SIGNS

History: Chronic soft stools. R/O-IBD/IBS, etc.

SPECIES

Canine

ULTRASONOGRAPHIC EXAMINATION OF THE ABDOMEN

Urinary System

The **urinary bladder**, trigone, and pelvic urethra presented normal thicknesses and normal tone. The ureters were not visible which is normal. No uroliths or sediment were visualized and anechoic urine was present. No evidence of inflammatory or neoplastic changes was noted. Ureteral papillae were normal.

BREED

Yorkshire Terrier

The residual prostate was uniform and measured 0.4 cm.

SEX

Neutered male

The **kidneys** revealed largely normal size and structure, corticomedullary definition and ratio (cortex 1/3 of medulla) were essentially maintained with some age-related loss of curvilinear patterns regarding the capsule and C/M junction. The cortices presented largely uniform texture with some increased echogenicity expected for this age patient. Medullary structure differed distinctly from that of the cortex and no evidence of pelvic dilation was present. The right kidney measured 2.93 cm. The left kidney measured 2.84 cm.

AGE

10 years

WEIGHT

6.38 lbs

Adrenal Glands

Both **adrenal glands** were visualized and recognized as having normal shape, size, position and echogenicity for this breed. The phrenic vasculature, glandular echogenicity and detail were unremarkable. Capsule, cortex, and medullary definition were normal for this age patient. The right adrenal gland measured 1.0 x 0.53 cm at the caudal pole and 0.55 cm at the cranial pole. The left adrenal gland measured 1.33 x 0.44 cm at the caudal pole and 0.58 cm at the cranial pole.

INTERPRETED BY

Eric Lindquist, DMV
DABVP, Cert. IVUSS

Spleen

The **spleen** presented a smooth homogeneous parenchyma hyperechoic to liver and renal cortical parenchyma. The capsule was smooth without noticeable expansion or deviation from within the spleen or adjacent pathology. The splenic vasculature demonstrated normal volume without signs of congestion or thrombosis. No sonographic evidence of acute or chronic inflammatory, neoplastic, or infarctual changes was noted.

IMAGING PERFORMED BY

Kelly Vazquez, CVT

HOSPITAL NAME

New Bridge VH

Liver

The **liver** was slightly subnormal in size, yet had uniform parenchyma and vascularity. The gallbladder and common bile duct were unremarkable.

REFERRING VET

Dr. Glennon

INVOICE

91454

Gastrointestinal

Examination of the **gastrointestinal tract** revealed a stomach and intestine free of stasis, of normal wall thickness, acceptable curvilinear mural detail, and peristaltic activity. Small and large intestine demonstrated normal luminal chyme and stool consistency respectively. No obstructive or overt infiltrative disease was noted. No associated abnormal lymphatic activity was noted.

DATE

8/24/21



PATIENT

Pancreas

Ozer Bernheim

The base and limbs of the **pancreas** were observed to be largely isoechoic to surrounding omental fat. Some parenchymal remodeling, however, with mild deviation from curvilinear normalcy was observed. Pancreatic duct and capsular irregularities were present consistent with age related changes. If pain upon imaging (+ Murphy sign) was present or if the patient is focally painful in subxiphoid palpation then low-grade smoldering chronic pancreatitis should be suspected.

SPECIES

Canine

BREED

ULTRASONOGRAPHIC FINDINGS

Yorkshire Terrier

Minor microhepatica.

SEX

Age related renal and pancreatic changes.

Neutered male

INTERPRETATION OF THE FINDINGS & FURTHER RECOMMENDATIONS

AGE

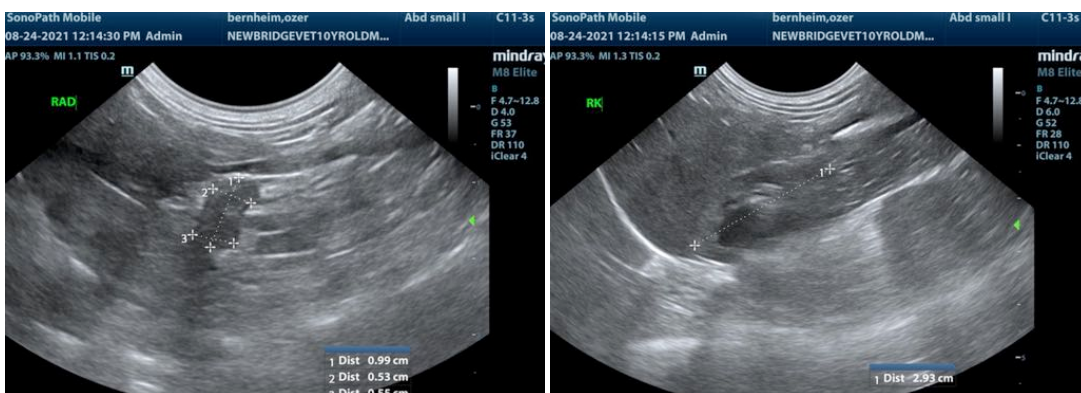
There was no evidence of significant disease. Dietary indiscretion, food intolerance/indiscretion, structurally insignificant inflammatory bowel or occult parasitism and occult Addison's are all potentials.

WEIGHT

6.38 lbs

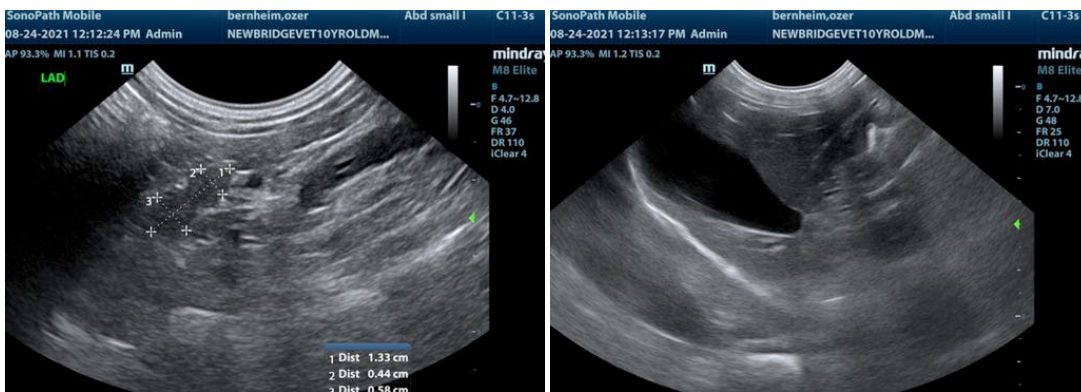
INTERPRETED BY

Eric Lindquist, DMV
DABVP, Cert. IVUSS



IMAGING PERFORMED BY

Kelly Vazquez , CVT



HOSPITAL NAME

New Bridge VH

REFERRING VET

Dr. Glennon

INVOICE

91454

DATE

8/24/21



PATIENT

Ozer Bernheim

SPECIES

Canine

BREED

Yorkshire Terrier

SEX

Neutered male

AGE

10 years

WEIGHT

6.38 lbs

INTERPRETED BY

Eric Lindquist, DMV
DABVP, Cert. IVUSS

**IMAGING
PERFORMED BY**

Kelly Vazquez, CVT

HOSPITAL NAME

New Bridge VH

REFERRING VET

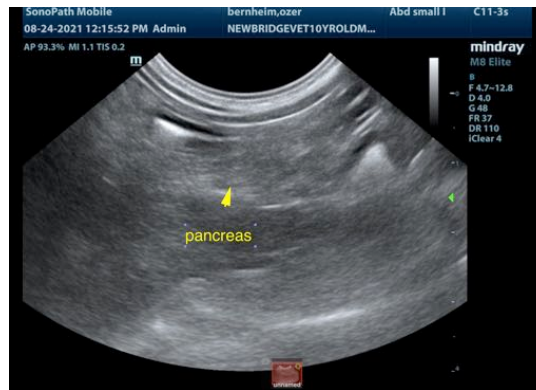
Dr. Glennon

INVOICE

91454

DATE

8/24/21



The information and recommendations provided are based on the images presented by the referring veterinarian. No evaluation can be communicated regarding pathology that was not visible in the image/video clips provided.

Thank you for this referral. If the clinical or image interpretation does not parallel your findings or if I can be of any further assistance please contact me.

Eric Lindquist, DMV, DABVP, Cert. IVUSS, CEO of SonoPath.com
info@SonoPath.com