

**DATE**

8/24/21

PRESENTING CLINICAL SIGNS

History: Elevated kidney values, clinically normal.

Current Medications: No current medications.

Lab Results: BUN 59 8/2/21.

PATIENT

Freddy Lenna

Radiographs: Not provided by the veterinarian.

Date of Previous IntraPet Ultrasound: No previous IntraPet scans.

Sedation: Sedation not required for scan.

Stat Report: STAT report not requested by the veterinarian.

SPECIES

Ferret

ULTRASONOGRAPHIC EXAMINATION OF THE ABDOMEN**Urinary System**

The **urinary bladder**, trigone, and pelvic urethra presented normal thicknesses and normal tone. The ureters were not visible which is normal. No uroliths or sediment were visualized and anechoic urine was present. No evidence of inflammatory or neoplastic changes was noted. Ureteral papillae were normal.

SEX

Neutered male

The **kidneys** were both thickened with irregular cortices and loss of corticomedullary definition. The kidneys were mildly subnormal in size with irregular contour and irregular, deviated renal pelvises with cortical infarcts and remodeling. The right kidney measured 2.79 cm. The left kidney measured 2.39 cm. Blood flow to the kidneys was subnormal.

AGE

1/19/19

Adrenal Glands

Both **adrenal glands** were visualized and recognized as having normal shape, size, position and echogenicity for this breed. The phrenic vasculature, glandular echogenicity and detail were unremarkable. Capsule, cortex, and medullary definition were normal for this age patient.

WEIGHT

1.1 kg

INTERPRETED BYEric Lindquist, DMV
DABVP, Cert. IVUSS**Spleen**

The **spleen** presented a smooth homogeneous parenchyma hyperechoic to liver and renal cortical parenchyma. The capsule was smooth without noticeable expansion or deviation from within the spleen or adjacent pathology. The splenic vasculature demonstrated normal volume without signs of congestion or thrombosis. No sonographic evidence of acute or chronic inflammatory, neoplastic, or infarctual changes was noted.

HOSPITAL NAME

Warm and Fuzzy VC

Liver

The **liver** images submitted revealed subjectively normal liver size, contour, and structure. Parenchymal echogenicity was naturally coarse and hypoechoic to the spleen. Vascular and biliary tracts were of normal volume with no evidence of congestion. The gallbladder presented acceptably thin walls with primarily anechoic content. The cystic and common bile ducts were normal. No pathological hepatic lymphadenopathy was evident. No overt structural evidence of inflammatory, infiltrative or regenerative pathology was evident.

REFERRING VET

Dr. Urie

INVOICE

91468

Gastrointestinal

Examination of the **gastrointestinal tract** revealed a stomach and intestine free of stasis, of normal wall thickness, acceptable curvilinear mural detail, and peristaltic activity. Small and large intestine demonstrated normal luminal chyme and stool consistency respectively. No obstructive or overt infiltrative disease was noted. No associated abnormal lymphatic activity was noted.

Pancreas

The base and limbs of the **pancreas** were observed to be largely isoechoic to surrounding omental fat. Pancreatic duct and capsular contour were acceptably normal and parenchyma respected normal curvilinear patterns. No overt evidence of active inflammatory or neoplastic disease was noted.

Free Abdomen

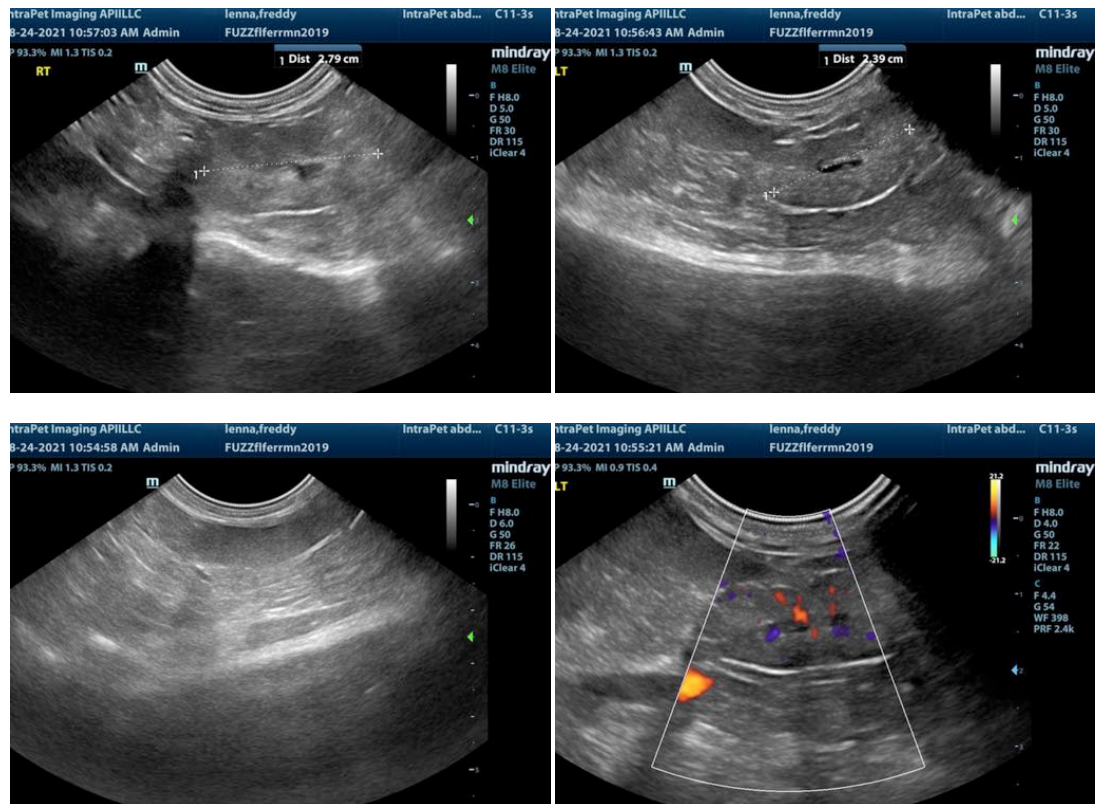
A trace amount of ascites was noted, yet the cause is unclear given the elevated globulins.

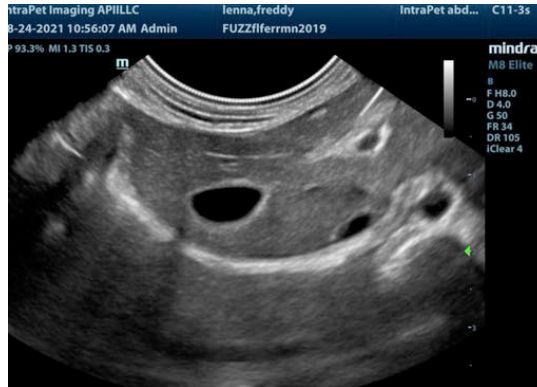ULTRASONOGRAPHIC FINDINGS

Significant, degenerative renal changes with a potential for primary renal dysplasia given the pattern. Otherwise, unremarkable abdomen.

INTERPRETATION OF THE FINDINGS & FURTHER RECOMMENDATIONS

Renal biopsy would be necessary for further definition. Full urinary work-up would be warranted. Creatinine should be monitored carefully as well as urine specific gravity and inflammatory sediment. Underlying chronic infectious disease should be considered. Long term prognosis is very guarded from the renal standpoint.





The information and recommendations provided are based on the images presented by the referring veterinarian. No evaluation can be communicated regarding pathology that was not visible in the image/video clips provided.

Thank you for this referral. If the clinical or image interpretation does not parallel your findings or if I can be of any further assistance please contact me.

Eric Lindquist, DMV, DABVP, Cert. IVUSS, CEO of SonoPath.com
Eric.Lindquist@SonoPath.com