



**PATIENT PRESENTING CLINICAL SIGNS**

Charlie Trubly History: Elevated kidney values. R/O chronic renal disease.

**SPECIES ULTRASONOGRAPHIC EXAMINATION OF THE ABDOMEN**

Canine **Urinary System**

**BREED**

Brittany Spaniel

The **urinary bladder**, trigone, and pelvic urethra presented normal thicknesses and normal tone. The ureters were not visible which is normal. No uroliths or sediment were visualized and anechoic urine was present. No evidence of inflammatory or neoplastic changes was noted. Ureteral papillae were normal.

**SEX**

Neutered male

The residual prostate is uniform and measured 0.97 cm.

The **kidneys** revealed moderate degenerative changes with increased cortical echogenicity that was non-specific. The kidneys are relatively normal in size. There were areas of cortical collapse noted. The renal pelvises were slightly dilated. The left kidney measured 5.68 cm.

**AGE**

10 years

**Adrenal Glands**

**WEIGHT**

51 lbs

Both **adrenal glands** were visualized and recognized as having normal shape, size, position and echogenicity for this breed. The phrenic vasculature, glandular echogenicity and detail were unremarkable. Capsule, cortex, and medullary definition were normal for this age patient. The right adrenal gland measured 1.28 x 0.48 cm at the caudal pole and 0.78 cm at the cranial pole. The left adrenal gland measured 2.19 x 0.63 cm at the caudal pole and 0.5 cm at the cranial pole.

**INTERPRETED BY**

Eric Lindquist, DMV  
DABVP, Cert. IVUSS

**Spleen**

**IMAGING PERFORMED BY**

Kelly Vazquez, CVT

The **spleen** presented a smooth homogeneous parenchyma hyperechoic to liver and renal cortical parenchyma. The capsule was smooth without noticeable expansion or deviation from within the spleen or adjacent pathology. The splenic vasculature demonstrated normal volume without signs of congestion or thrombosis. No sonographic evidence of acute or chronic inflammatory, neoplastic, or infarctual changes was noted.

**HOSPITAL NAME**

New Bridge VP

**Liver**

**REFERRING VET**

Dr. Glennon

The **liver** revealed coarse architecture with increased portal markings and hypoechoic nodular changes. The largest nodule measured 1.93 cm. Increased portal markings were noted. The gallbladder and common bile duct were unremarkable.

**INVOICE**

91456

**Gastrointestinal**

**DATE**

8/24/21

Examination of the **gastrointestinal tract** revealed a stomach and intestine free of stasis, of normal wall thickness, acceptable curvilinear mural detail, and peristaltic activity. Small and large intestine demonstrated normal luminal chyme and stool consistency respectively. No obstructive or overt infiltrative disease was noted. No associated abnormal lymphatic activity was noted.



**PATIENT**

**Pancreas**

Charlie Trubly

The base and limbs of the **pancreas** were observed to be largely isoechoic to surrounding omental fat. Pancreatic duct and capsular contour were acceptably normal and parenchyma respected normal curvilinear patterns. No overt evidence of active inflammatory or neoplastic disease was noted.

**SPECIES**

Canine

**ULTRASONOGRAPHIC FINDINGS**

**BREED**

Non-specific, moderate, chronic degenerative renal disease.

Brittany Spaniel

**INTERPRETATION OF THE FINDINGS & FURTHER RECOMMENDATIONS**

**SEX**

Blood pressure measurements, 72 hour IV fluid protocol, Leptospirosis titers +/- urine culture would all be indicated if inflammatory sediment is present in the urine.

Neutered male

**AGE**

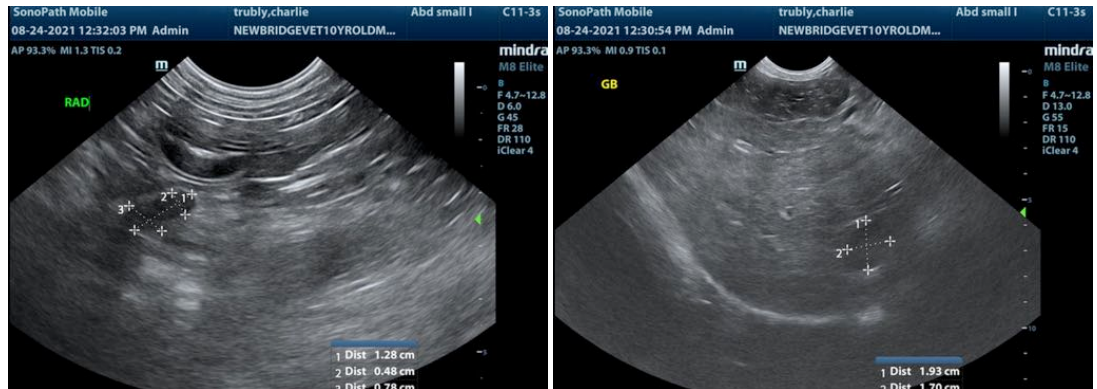
10 years

**WEIGHT**

51 lbs

**INTERPRETED BY**

Eric Lindquist, DMV  
DABVP, Cert. IVUSS



**IMAGING PERFORMED BY**

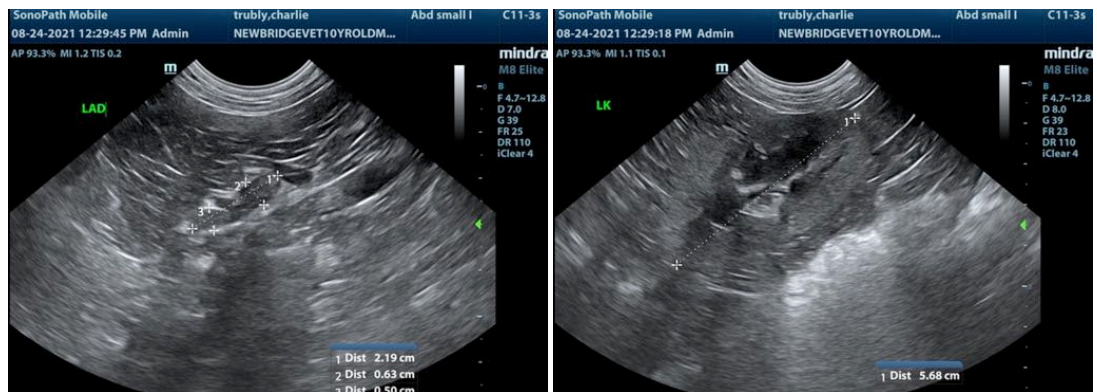
Kelly Vazquez, CVT

**HOSPITAL NAME**

New Bridge VP

**REFERRING VET**

Dr. Glennon

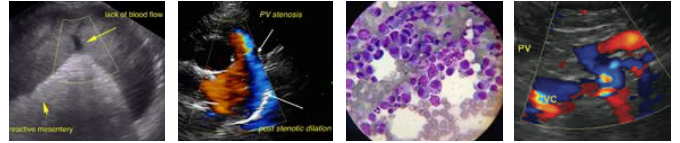


**INVOICE**

91456

**DATE**

8/24/21



**PATIENT**

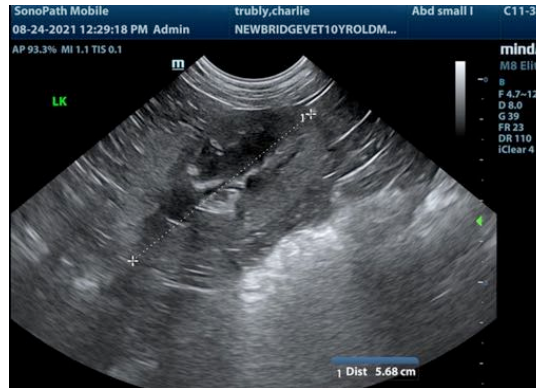Charlie Trubly

**SPECIES**

Canine

**BREED**

Brittany Spaniel



**SEX**

Neutered male

The information and recommendations provided are based on the images presented by the referring veterinarian. No evaluation can be communicated regarding pathology that was not visible in the image/video clips provided.

**AGE**

10 years

Thank you for this referral. If the clinical or image interpretation does not parallel your findings or if I can be of any further assistance please contact me.

**Eric Lindquist, DMV, DABVP, Cert. IVUSS, CEO of SonoPath.com**  
info@SonoPath.com

**WEIGHT**

51 lbs

**INTERPRETED BY**

Eric Lindquist, DMV  
DABVP, Cert. IVUSS

**IMAGING PERFORMED BY**

Kelly Vazquez, CVT

**HOSPITAL NAME**

New Bridge VP

**REFERRING VET**

Dr. Glennon

**INVOICE**

91456

**DATE**

8/24/21