



PATIENT PRESENTING CLINICAL SIGNS

Albert Dragosh Chronic nasal discharge. Grade II/VI heart murmur. Hypertension.

SPECIES ULTRASONOGRAPHIC EXAMINATION OF THE HEART

Feline

BREED

Domestic Shorthair

SEX

Neutered male

AGE

13 years

The echocardiogram in this patient demonstrated normal **left atrial** size and structure with no evidence of “smoke” or thrombi. The cranial and caudal **mitral valve** leaflets appeared mildly thickened with some insufficiency noted on Doppler. The **left ventricle** presented excessive free wall and septal thicknesses with hypertrophic thicknesses compared to normal for this species. The **myocardium** presented essentially normal echogenicity without immediate signs of fibrotic or ischemic disease. **Contractility** of the ventricular walls was considered excessive for this patient evidenced by the elevated fractional shortening measurement. The **left ventricular outflow** tract demonstrated turbulent laminar flow. Subjective assessment of the **right atrium** and auricle revealed normal size, structure and content. No evidence of masses was noted. **Tricuspid** valvular assessment demonstrated linear morphology. The **right ventricle** was of normal size with normal chordae structure, myocardial echogenicity and thickness. **Pulmonic** tract assessment revealed normal valve structure, laminar flow, and diameter. No visible **pericardial** or free pleura fluid was noted. No echographically detectable evidence of infiltrative disease was visible. The **mediastinum** was free of masses in the visible window.

INTERPRETED BY

Eric Lindquist, DMV DABVP, Cert. IVUSS

IMAGING PERFORMED BY

Eric Lindquist, DMV DABVP, Cert. IVUSS

HOSPITAL NAME

Franklin Lakes AH

REFERRING VET

Dr. Ward

INVOICE

91434

DATE

8/24/21

FELINE CARDIAC PARAMETERS	BODY WEIGHT (kg)	HR (BPM)	IVSd (cm)	LVIDd (cm)	LVWd (cm)	FS (%)	EF (%)
NORMAL PARAMETER	-----	150-240	0.3-0.6	1.0-2.1	0.25-0.6	35-67	80-100
PATIENT		2.03	0.64	1.31	0.82	63	94
FELINE CARDIAC PARAMETERS	LA/AO (Boon)	LA/AO HEART BASE (Sisson)	LA 2D 4-chamber long axis AS to FW (Sisson) (cm)	LVOT VEL. (m/s)	RVOT VEL. (m/s)	IVRT (m/)	
NORMAL PARAMETER	<1.5	0.88-1.79	0.7-1.7	<1.6	<1.3	40-60	
PATIENT	1.25	1.15	1.3	2.0	0.83	NM	
Adapted from June Boon, Veterinary Echocardiography, 1998 Sisson D et al. JVIM 1991; 5: 232, Jacobs et al. Am J Vet Res 1985; 46:1705							



PATIENT

ULTRASONOGRAPHIC EXAMINATION OF THE ABDOMEN

Albert Dragosh

Urinary System

SPECIES

The **urinary bladder**, trigone, and pelvic urethra presented normal thicknesses and normal tone. The ureters were not visible which is normal. No uroliths or sediment were visualized and anechoic urine was present. No evidence of inflammatory or neoplastic changes was noted. Ureteral papillae were normal.

Feline

BREED

The **kidneys** were subnormal in size with infarcts and remodeling. The left kidney measured 2.87 cm. The right kidney measured 3.2 cm.

Domestic Shorthair

SEX

Adrenal Glands

Neutered male

Both **adrenal glands** were visualized and recognized as having normal shape, size, position and echogenicity for this breed. The phrenic vasculature, glandular echogenicity and detail were unremarkable. Capsule, cortex, and medullary definition were normal for this age patient. The left adrenal gland measured 0.4 cm. The right adrenal gland measured 0.4 cm.

AGE

13 years

INTERPRETED BY

Spleen

Eric Lindquist, DMV
DABVP, Cert. IVUSS

The **spleen** presented a smooth homogeneous parenchyma hyperechoic to liver and renal cortical parenchyma. The capsule was smooth without noticeable expansion or deviation from within the spleen or adjacent pathology. The splenic vasculature demonstrated normal volume without signs of congestion or thrombosis. No sonographic evidence of acute or chronic inflammatory, neoplastic, or infarctual changes was noted.

IMAGING PERFORMED BY

Eric Lindquist, DMV
DABVP, Cert. IVUSS

HOSPITAL NAME

Liver

Franklin Lakes AH

The **liver** images submitted revealed subjectively normal liver size, contour, and structure. Parenchymal echogenicity was naturally coarse and hypoechoic to the spleen. Vascular and biliary tracts were of normal volume with no evidence of congestion. The gallbladder presented acceptably thin walls with primarily anechoic content. The cystic and common bile ducts were normal. No pathological hepatic lymphadenopathy was evident. No overt structural evidence of inflammatory, infiltrative or regenerative pathology was evident.

REFERRING VET

Dr. Ward

INVOICE

Gastrointestinal

91434

Examination of the **gastrointestinal tract** revealed a stomach and intestine free of stasis, of normal wall thickness, acceptable curvilinear mural detail, and peristaltic activity. Small and large intestine demonstrated normal luminal chyme and stool consistency respectively. No obstructive or overt infiltrative disease was noted. No associated abnormal lymphatic activity was noted.

DATE

8/24/21



PATIENT

Pancreas

Albert Dragosh

The base and limbs of the **pancreas** were observed to be largely isoechoic to surrounding omental fat. Pancreatic duct and capsular contour were acceptably normal and parenchyma respected normal curvilinear patterns. No overt evidence of active inflammatory or neoplastic disease was noted.

SPECIES

Feline

ULTRASONOGRAPHIC FINDINGS

BREED

Moderate degenerative renal changes with infarcts. This is likely the source of hypertension in this patient.

Domestic Shorthair

Left ventricular hypertrophy with mitral insufficiency, consistent with hypertrophic cardiomyopathy or hypertensive cardiomyopathy.

SEX

Neutered male

INTERPRETATION OF THE FINDINGS & FURTHER RECOMMENDATIONS

AGE

13 years

No treatment is recommended at this time. Renal support protocol is indicated. Primary respiratory protocol is recommended given the radiographic findings, chronic bronchial disease and excessive thoracic fat.

INTERPRETED BY

Eric Lindquist, DMV
DABVP, Cert. IVUSS

IMAGING PERFORMED BY

Eric Lindquist, DMV
DABVP, Cert. IVUSS

HOSPITAL NAME

Franklin Lakes AH

REFERRING VET

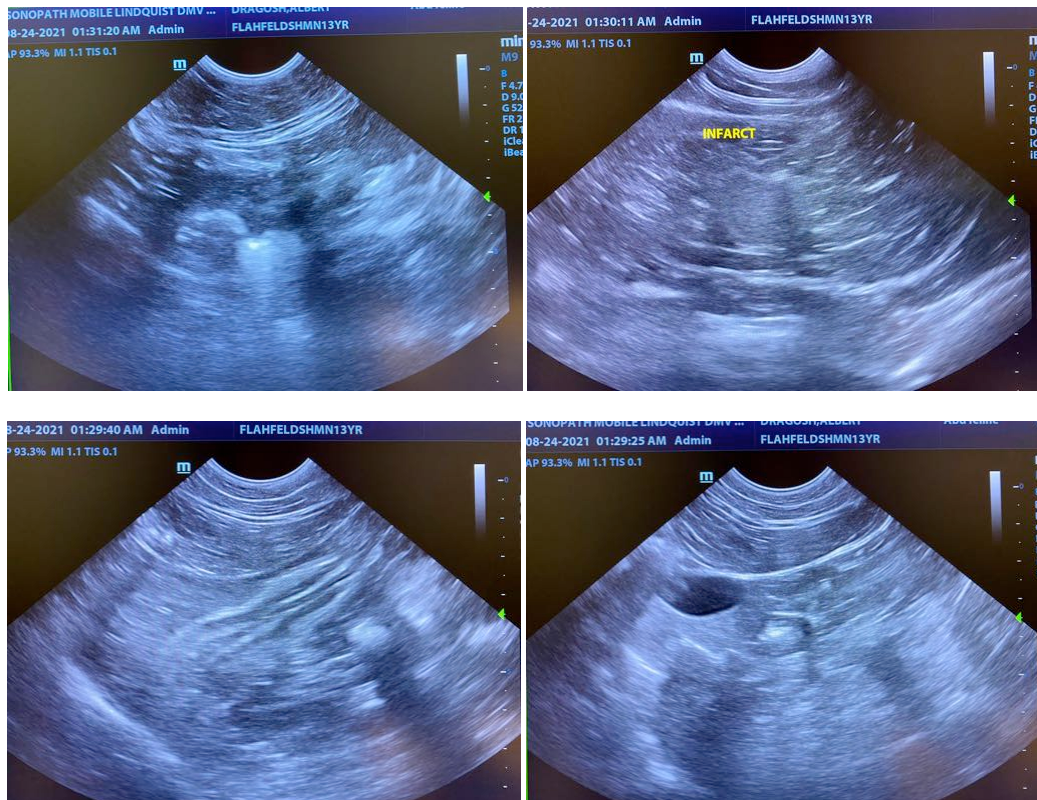
Dr. Ward

INVOICE

91434

DATE

8/24/21





PATIENT

Albert Dragosh

SPECIES

Feline

BREED

Domestic Shorthair

SEX

Neutered male

AGE

13 years

INTERPRETED BY

Eric Lindquist, DMV
DABVP, Cert. IVUSS

IMAGING PERFORMED BY

Eric Lindquist, DMV
DABVP, Cert. IVUSS

HOSPITAL NAME

Franklin Lakes AH

REFERRING VET

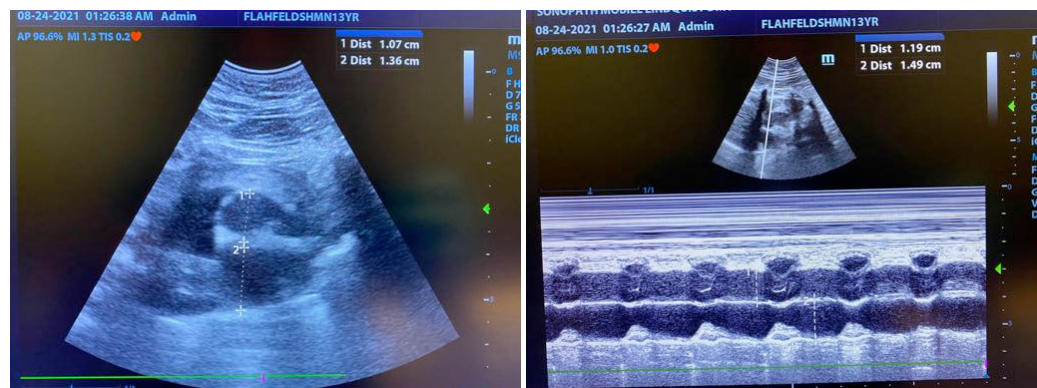
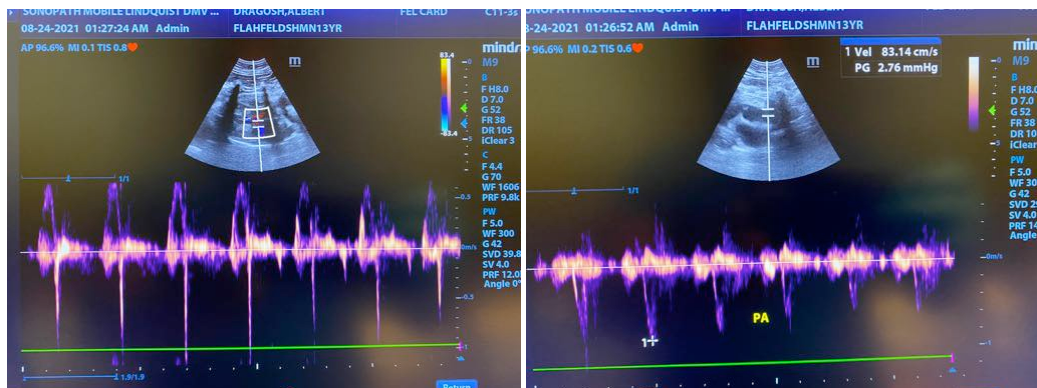
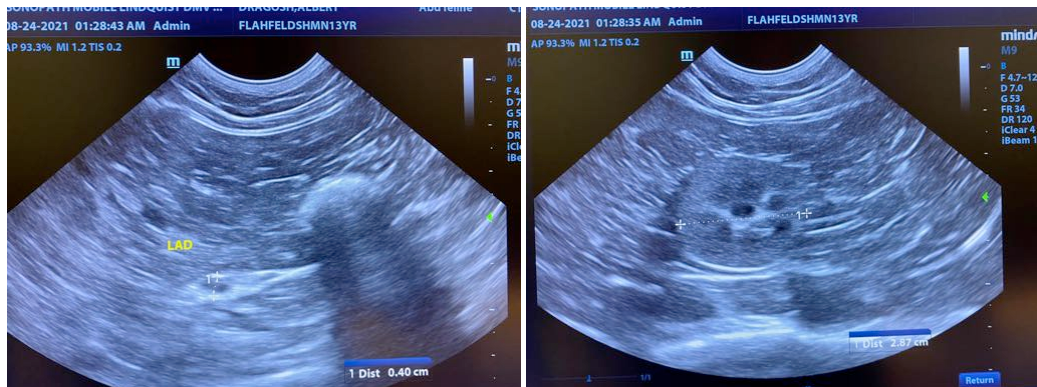
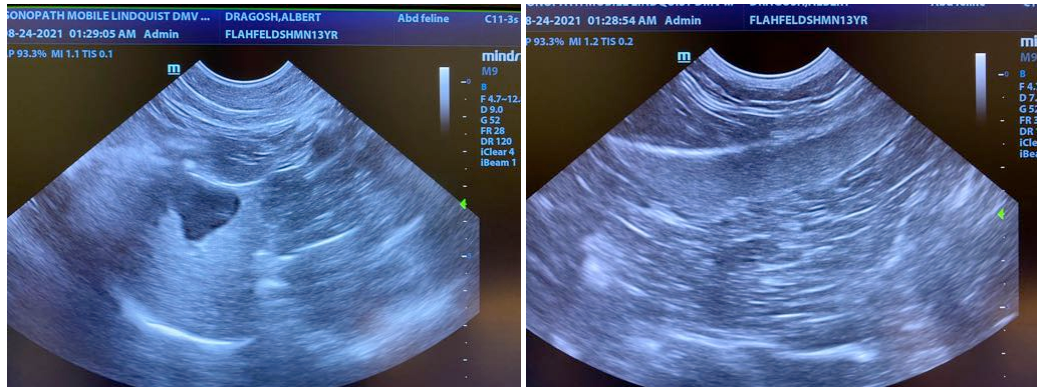
Dr. Ward

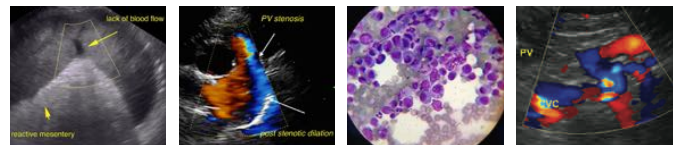
INVOICE

91434

DATE

8/24/21





PATIENT

Albert Dragosh

SPECIES

Feline

BREED

Domestic Shorthair

SEX

Neutered male

AGE

13 years

INTERPRETED BY

Eric Lindquist, DMV
DABVP, Cert. IVUSS

IMAGING PERFORMED BY

Eric Lindquist, DMV
DABVP, Cert. IVUSS

HOSPITAL NAME

Franklin Lakes AH

REFERRING VET

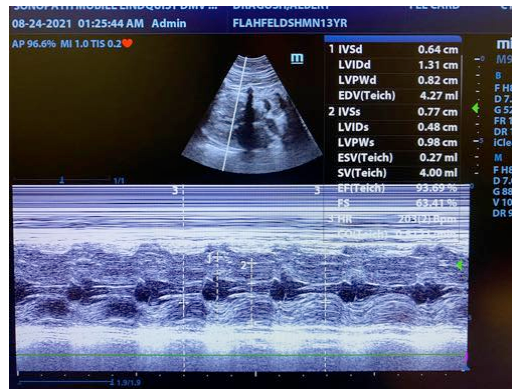
Dr. Ward

INVOICE

91434

DATE

8/24/21




The information and recommendations provided are based on the images presented by the referring veterinarian. No evaluation can be communicated regarding pathology that was not visible in the image/video clips provided.

Thank you for this referral. If the clinical or image interpretation does not parallel your findings or if I can be of any further assistance please contact me.

Eric Lindquist, DMV, DABVP, Cert. IVUSS, CEO of SonoPath.com

Info@SonoPath.com



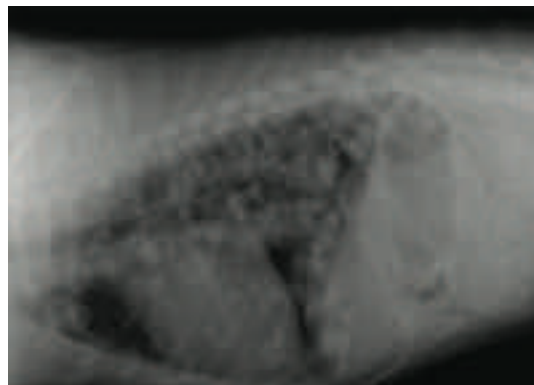
The following is an applicable excerpt from the *Curbside Guide to Diagnosis & Treatment of Sonographic Disease* offered by [SonoPath.com](http://sonopath.com) Lindquist, Frank, Lobetti, and Modler.

An essential quick guide for every general practitioner and sonographer.

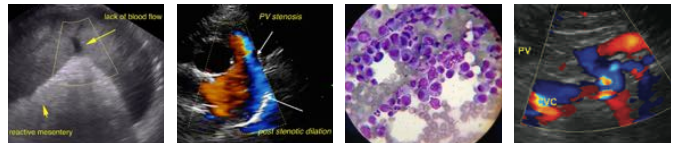
<https://sonopath.com/products/curbside-guide-editing-due-release-12012015>

Respiratory Disease in Dogs and Cats

<http://www.sonopath.com/Respiratory>



Right lateral view of the thorax in a dog with lung metastases. Note the presence of multifocal interstitial nodules of varying size and the expanded lung fields.



PATIENT

Albert Dragosh

SPECIES

Feline

BREED

Domestic Shorthair

SEX

Neutered male

AGE

13 years

INTERPRETED BY

Eric Lindquist, DMV
DABVP, Cert. IVUSS

IMAGING PERFORMED BY

Eric Lindquist, DMV
DABVP, Cert. IVUSS

HOSPITAL NAME

Franklin Lakes AH

REFERRING VET

Dr. Ward

INVOICE

91434

DATE

8/24/21

Description: Infections, allergies, parasites, foreign bodies, fungi, or neoplasia can all cause respiratory disease. Efficacious therapy maximizes the precise targeting of the causative agent and minimizes the suppression of the body's own defense mechanisms (i.e., mucociliary activity, bronchus-associated lymph tissue and reflexes). Therefore, respiratory therapy is most effective if it is determined based on cytology and culture and sensitivity results obtained from a bronchoalveolar lavage (BAL) or a transtracheal wash. If lung consolidations are imaged sonographically, ultrasound-guided FNA or even core biopsy may be performed. The BAL or transtracheal wash results will also dictate the level of therapy needed to control or resolve the pathology. If the patient is in acute respiratory distress, stabilization is vital before any attempt is made to obtain cytology and culture samples.

Acute Respiratory Distress Syndrome (ARDS) must be kept in mind in cases of acute respiratory distress, which sometimes mimics congestive heart failure (CHF) in dogs and causes non-cardiogenic pulmonary edema. The following risk factors have been identified for ARDS:

Direct Pulmonary Injury:

- Microbial pneumonia
- Aspiration pneumonia
- Strangulation
- Hyperoxia
- Sepsis
- Parvovirus
- Paraquat poisoning
- Shock
- Trauma
- Bee envenomation

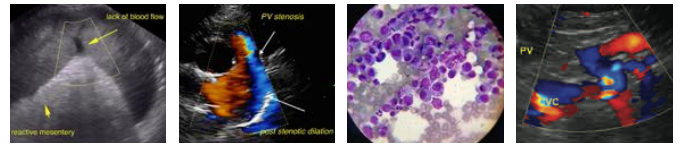
Indirect Pulmonary Injury:

- Parasitic pneumonitis
- Smoke inhalation
- Pulmonary contusions
- Lung lobe torsion
- Babesiosis
- SIRS
- Pancreatitis
- Gastric and splenic torsion
- Multiple transfusions
- Disseminated intravascular coagulation

Pulmonary thromboembolic disease should also be considered in older patients that have predisposing underlying diseases, such as Cushing's syndrome, diabetes, protein-losing disease, neoplasia, pulmonary hypertension, congestive cardiac disease, chronic infectious disease, and so forth. Clinical signs may initiate with minor unexplained tachypnea and restlessness or persistent "allergic"-type coughs (especially those that present at night), and can progress to fulminant respiratory distress and rapid right heart enlargement due to ensuing pulmonary hypertension. (See the chapter on "Right Heart Disease" for further details regarding this phenomenon.)

Clinical Signs: Clinical signs can vary and will depend on the underlying etiology. A cough may be productive or non-productive, and increased effort may be noted upon inspiration, expiration, or both. Crackles, wheezes, rales, and pleural rubs may also be heard over various lung fields.

Diagnostics: Nasal swabs are of no value as they do little more than identify normal flora; however, tissue scrapings provide information that is more meaningful. In cases of primary bacterial infection, culture and sensitivity results derived from BAL samples will usually reveal heavy growth of pathogenic bacteria; light to moderate growth generally reveals normal bacterial flora. Typically, the normal cytologic population is comprised of 70-80% monocytes. An elevated lymphocyte presence may be indicative of lymphoma and can be followed up with PCR testing of the lavage fluid. One should consider



PATIENT

Albert Dragosh

the location of infiltrates on the thoracic radiographs as well as the level of culture growth in order to determine which antibiotics to prescribe. Fungal organisms are commonly missed on transtracheal washes but usually found upon BAL. When faced with chronic nasal discharge in cats, it can be helpful to conduct fungal serology (*Cryptococcus* spp. is often found); however, false positive results are common, especially in cases of *Histoplasma* and *Blastomycosis*.

SPECIES

Feline

Treatment: Therapy is directed at controlling secretions with antibiotics and steroids, as justified by culture and sensitivity and cytology results, respectively. Respiratory diseases are often complicated by secondary bacterial infection. Gram-positive organisms inhabit the upper airways, whereas gram-negative organisms reside in the lower airway tissues in minimally oxygenated environments. Given the presence of the blood-bronchus barrier, many systemic antibiotics do not reach the therapeutic concentrations necessary to be effective against the etiologic or complicating organism. For example, only 4% of amoxicillin given parenterally ever reaches bronchial secretions, whereas gentamicin provides 25% penetration. Therefore, aerosol or intratracheal injection (diluted in 2 ml saline) therapy for 3-5 days initially, followed by systemic treatment, is the best approach for moderate to severe diseases affecting the bronchial tree. Cytology results may justify a tapering prednisone protocol (0.5 mg/kg PO BID, with appropriate tapering after the abatement of symptoms). Excessive mast cells, lymphocytes, and/or plasma cells may justify cortisone therapy. Alternatively, cyclosporin can be considered to inhibit infiltrates in poorly responsive cases. Hypoallergenic dietary trials are justified if an allergic etiology is a concern. A non-productive cough can be treated with hydrocodone (0.22mg/kg PO Q4-6hr, as needed). Productive coughs require percussion therapy along with bronchodilators, such as albuterol (20ug/kg PO BID x 5d) for dogs or terbutaline for cats (0.625 mg PO BID-TID or 0.01 mg/kg SQ in a crisis). Bronchodilators are indicated if crackles, elongated expiratory time and effort, tracheal collapse, flattened diaphragm, or cough are present. Non-generic extended-release theophylline (10 mg/kg PO BID) is the most effective given that dosages and release pharmacodynamics are product specific. Cyproheptadine can also be used in cats as a bronchodilator, as it interferes with smooth muscle contraction. For best penetration into the lung parenchyma, bronchodilators and steroid nebulizers should be used.

BREED

Domestic Shorthair

SEX

Neutered male

AGE

13 years

INTERPRETED BY

Eric Lindquist, DMV
DABVP, Cert. IVUSS

IMAGING PERFORMED BY

Eric Lindquist, DMV
DABVP, Cert. IVUSS

HOSPITAL NAME

Franklin Lakes AH

REFERRING VET

Dr. Ward

INVOICE

91434

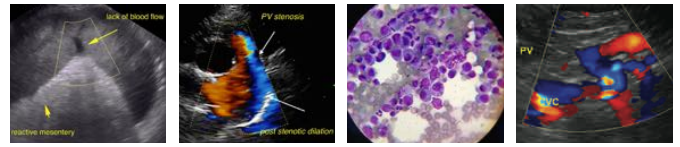
DATE

8/24/21

Treatment of feline asthma depends on the stage of the disease. In an acute crisis, use epinephrine ([1:1000] 0.1-0.2 ml IV or SQ). A shock dose of a steroid, such as prednisolone, can also be given (2-4 mg/kg PO Q24hr, which can be tapered from 1.0 to 0.5 mg/kg PO Q48hr once signs are under control). Chronic management should include a bronchodilator, such as theophylline extended-release or terbutaline, at the doses outlined above. Cyproheptadine, a serotonin inhibitor, can also be given (2 mg PO Q24hr). Alternatively, the leukotriene inhibitor zafirlukast (Accolate) can be given at 5-10 mg PO Q12-24hr as maintenance, although this medication requires 2-3 weeks to reach efficacy.

Chronic rhinitis cases in cats typically respond best to doxycycline (10 mg/kg PO Q24hr), which is a best first choice against primary bacterial pathogens. Quinolones (enrofloxacin at 5 mg/kg/day), chloramphenicol (10 mg/kg PO BID), or azithromycin (10 mg/kg PO BID x 5d then PO Q72hr for 3 weeks) can be used for resistant cases. Feline herpes virus or calicivirus are often primary culprits with secondary pathogens. Pasteurella and mycoplasma live in low-oxygen tissue under the mucosal surfaces in the nose and mouth, and often grow secondarily on virally induced lesions. Clindamycin (10 mg/kg PO Q24hr), Clavamox (62.5 mg/cat PO BID), and metronidazole (15 mg/kg PO BID; also an anti-inflammatory) are prudent choices if these organisms are suspected. Resistant viral infections can be treated with lysine (125-250 mg per cat PO BID), alpha interferon (30 IU Q24hr, part in the nostril diluted in saline and the remainder given orally), or famciclovir (31.25 mg/kg PO BID for 14 days) can be attempted as viral modulators. Initial studies with famciclovir are promising; however, data with respect to long-term use have yet to be established. As a last resort, piroxicam (0.3 mg/kg PO Q24hr in liquid form) can be given as an immune modulator.

Summary of Therapeutic Options for Respiratory Disease



PATIENT

Albert Dragosh

SPECIES

Feline

BREED

Domestic Shorthair

SEX

Neutered male

AGE

13 years

INTERPRETED BY

Eric Lindquist, DMV
DABVP, Cert. IVUSS

IMAGING PERFORMED BY

Eric Lindquist, DMV
DABVP, Cert. IVUSS

HOSPITAL NAME

Franklin Lakes AH

REFERRING VET

Dr. Ward

INVOICE

91434

DATE

8/24/21

1. Bronchodilators

The use of bronchodilators in various disease states is based on the assumption that clinically significant bronchoconstriction exists. Although this has been shown in a small proportion of dogs with inflammatory bronchopulmonary disease, it is significant in cats where bronchoconstriction is a frequent feature of inflammatory bronchial disease. Because the signs of bronchoconstriction can dominate the clinical syndrome, feline inflammatory airway disease is frequently referred to as "feline asthma." This disease should not be thought of simply as reversible airway obstruction or "irritable airways," but instead understood as an inflammatory disease that can yield bronchial hyperreactivity and bronchospasm.

Bronchial tone is mediated by three neuroendocrine systems:

- The parasympathetic system, which is the dominant efferent pathway, provides the baseline tone of mild bronchoconstriction that characterizes the normal respiratory tract.
- The sympathetic system mediates these inherent bronchoconstrictive effects through β_2 -adrenergic-mediated bronchodilation and α_1 -mediated bronchoconstriction, and possibly via α_2 -mediated reduction of parasympathetic bronchoconstriction.
- The non-adrenergic, non-cholinergic (NANC) system mediates bronchodilation through various neurotransmitters, such as vasoactive intestinal peptides.

a) Adrenergic agonists

All adrenergic agonists have variable α and β receptor affinity. Non-selective β receptor agonists, such as isoprenaline, or mixed α and β receptor agonists, such as adrenaline, are more likely to produce cardiovascular side effects than similarly administered selective β agonists. Consequently, drugs with preferential affinity for β_2 receptors are likely to provide more effective bronchodilation with fewer side effects. The two β_2 agonists used in small animals are terbutaline and albuterol.

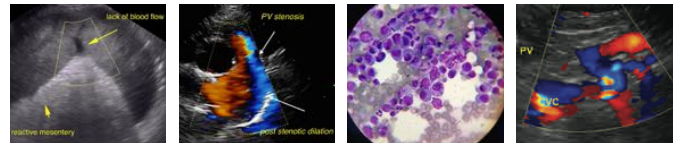
Terbutaline

Terbutaline is a selective β_2 receptor agonist that promotes the relaxation of smooth muscle found principally in bronchial, vascular, and uterine tissues. **Dogs:** 1.25-5 mg/dog PO BID-TID or 0.01 mg IM/SC Q4hr. **Cats:** 0.312-1.25 mg/cat PO BID-TID or 0.015 mg/kg IM/SC Q4hr.

Albuterol

Albuterol is a selective β_2 receptor agonist with pharmacological properties similar to terbutaline. The drug should be given for 5 days, and if there has been no improvement or adverse effects, the dose can be increased. For animals that only respond to a higher dose, the dose should be reduced to the lowest effective dose, as determined for each patient. Albuterol and prednisolone act synergistically to produce bronchodilation in response to a standard bronchoconstriction stimulus. Thus, concurrent glucocorticoid therapy may be worth considering in patients proving refractory to albuterol's bronchodilatory effects. **Dogs and cats:** 0.05 mg/kg (50 mcg/kg) PO BID-TID or inhaled via a pediatric aerochamber or AeroKat® inhaler.

b) Methylxanthines



PATIENT

Albert Dragosh

SPECIES

Feline

BREED

Domestic Shorthair

SEX

Neutered male

AGE

13 years

INTERPRETED BY

Eric Lindquist, DMV
DABVP, Cert. IVUSS

IMAGING PERFORMED BY

Eric Lindquist, DMV
DABVP, Cert. IVUSS

HOSPITAL NAME

Franklin Lakes AH

REFERRING VET

Dr. Ward

INVOICE

91434

DATE

8/24/21

Methylxanthines modulate respiratory function by being adenosine receptor antagonists, inhibiting phosphodiesterase, interfering with calcium mobilization, and suppressing the release of histamine. The net result is bronchodilation of both large and small airways, inhibition of mast cell degranulation, increased mucociliary clearance, and decreased work associated with breathing. The most common drug used is aminophylline. **Dogs:** 9-11 mg/kg IM/PO TID-QID or slow IV (diluted) for emergency bronchodilation. **Cats:** 6.6 mg/kg PO Q12hr or 2-5 mg/kg slow IV (diluted) for emergency bronchodilation.

c) Anticholinergics

Anticholinergics compete with acetylcholine at muscarinic sites and antagonize vagally mediated bronchoconstriction in the respiratory tract. Despite this, they are generally not clinically effective due to their non-selective interaction with different muscarinic receptors and their side effects.

d) Atropine

The primary indication for atropine use in small animals is to produce bronchodilation in acutely dyspneic animals. It is the treatment of choice for life-threatening respiratory distress induced by anticholinesterases.

2. Disruption of Mucous Clearance

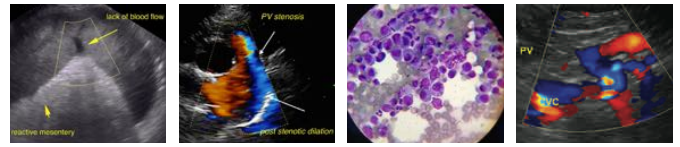
In respiratory disease, mucous undergoes a physical change and becomes extremely viscous, affecting ciliary function. When effective mucous clearance ceases, there is an accumulation of mucous and the following occurs:

- Reduced airway diameter.
- Compromised penetration of antibiotics and host defense mechanisms at the site of infection.
- Worsening of the cough.
- Bacterial colonization.
- Reduced humidification of inspired air and trapping of foreign particles. Decreased protection of mucoid surfaces from dehydration and injury from physical, chemical, and infectious agents.

Treatment is aimed at optimizing the mucociliary escalator by altering mucous production and its viscosity, and enhancing ciliary action. Mucolytics are used to break down and decrease the viscosity of mucous, whereas expectorants promote an increase in the volume and a decreased viscosity of bronchial secretions. Ciliary activity can be improved using β -receptor agonists and methylxanthine derivatives.

a) Rehydration

Animals with lung disease are frequently dehydrated because of decreased water intake and increased fluid loss due to pyrexia and polypnea, which contributes to increased mucus viscosity. Water and saline solutions can be used to liquefy hyperviscous mucous and can be administered orally or via parenteral fluids, inhalation (steam vapour), or saline aerosols (nebulisation).



PATIENT

Albert Dragosh

b) Mucolytic drugs

SPECIES

Feline

The viscosity of pulmonary mucus secretions depends on the concentrations of mucoproteins and presence of DNA. Although mucoprotein is the main determinant of viscosity in normal mucus, in cases of purulent inflammation, the concentration of DNA increases due to increased cellular debris, which contributes to an increased mucoid viscosity. Mucolytic drugs break down the disulfide bonds of mucoproteins, resulting in a decrease in viscosity.

BREED

Domestic Shorthair

c) Acetylcysteine

SEX

Neutered male

Acetylcysteine reduces the viscosity of both purulent and non-purulent secretions by virtue of its free sulphhydryl group, which reduces the disulphide linkages in mucoproteins. The latter are thought to be at least partly responsible for the particularly viscid nature of respiratory mucus. The mucolytic activity of acetylcysteine is unaltered by the presence of DNA and increases with rising pH levels. Acetylcysteine can be given by aerosol or orally; however, administration by aerosol may cause bronchospasm, ciliary inhibition, and severe coughing. Nebulize as a 2% solution over 30-60 minutes or instill directly into the trachea (1-2 ml of a 20% solution).

AGE

13 years

d) Bromohexine

INTERPRETED BY

Eric Lindquist, DMV
DABVP, Cert. IVUSS

Bromohexine increases mucus viscosity by increasing lysosomal activity. This increased lysosomal activity enhances hydrolysis of acid mucopolysaccharide polymers, which contributes significantly to normal mucus viscosity. In purulent bronchial inflammation, bronchial mucus viscosity is more dependent upon the presence of large amounts of DNA fibres. As bromohexine does not affect these DNA fibres, its mucolytic action is limited in these situations. At high doses, it can act as an antitussive and will increase the concentration of tetracyclines, sulphonamides, and erythromycin in the bronchial mucous.

IMAGING PERFORMED BY

Eric Lindquist, DMV
DABVP, Cert. IVUSS

HOSPITAL NAME

Franklin Lakes AH

e) Decongestants

Decongestants reduce the production and accumulation of inflammatory edema in the nasal passages, but are seldom used in veterinary practice. Drugs, such as adrenaline and phenylephrine, are applied topically. The major side effect is a rebound phenomenon; relapse is likely once the effect of the decongestant has worn off.

REFERRING VET

Dr. Ward

f) Expectorants

INVOICE

91434

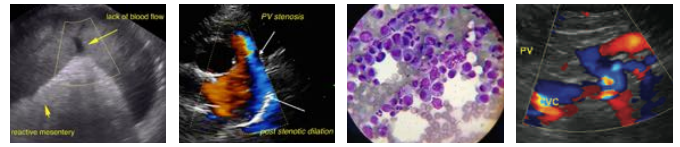
Expectorants promote the removal of secretions from the respiratory tree by increasing the volume and reducing the viscosity of respiratory secretions; however, overall, they only make a slight contribution to therapeutic success. Steam, volatile oils, and iodine preparations can all act as expectorants.

DATE

8/24/21

3. Coughing

The cough reflex is complex, involving the central and peripheral nervous system as well as the smooth muscle of the bronchial tree. It has been suggested that irritation of the bronchial mucosa causes bronchoconstriction, which in turn stimulates cough receptors located within the tracheobronchial tree.



PATIENT

Albert Dragosh

Afferent conduction from these receptors occurs via the vagus nerve and likely travels to multiple centers within the medulla that are distinct from the actual respiratory center.

SPECIES

Feline

Almost all respiratory tract disorders involving the large and small airways result in coughing. The latter can be viewed as a protective physiological process that helps to clear viscid secretions produced by chronic airway inflammation. Because prolonged contact between inflammatory mediators in the mucus and epithelial cells perpetuates inflammation, any form of cough suppression needs to be implemented cautiously. If coughing persists once the primary disease has been addressed, then suppression may be desirable, as chronic coughing tends to promote airway inflammation, which increases the risk of a vicious cough cycle that can lead to further mucosal irritation and perpetuate coughing. Additionally, chronic coughing of any kind will increase the risk of irreversible emphysema. Consequently, cough suppression may be particularly helpful in certain situations. Perhaps the most common condition where cough suppression plays an integral part in successful management is dynamic airway disease.

BREED

Domestic Shorthair

SEX

Neutered male

AGE

13 years

It is also important to differentiate between a productive cough and a non-productive cough. A productive cough is a protective reflex that removes secretions from the lungs, which may otherwise become congested with mucous plugs that can become sites for infection and disturb effective gas exchange. This type of cough should not be suppressed and may be encouraged with expectorants. A non-productive cough, particularly if it is chronic and continuous, may itself cause chronic respiratory parenchymal changes, such as emphysema and fibrosis. It is also distressing and exhausting to the animal and may irritate the owner. Non-productive coughs may be treated with cough suppressants.

INTERPRETED BY

Eric Lindquist, DMV
DABVP, Cert. IVUSS

IMAGING PERFORMED BY

Eric Lindquist, DMV
DABVP, Cert. IVUSS

Coughing can be treated by:

- Removing the irritant using mucolytics and expectorants.
- Blocking peripheral receptors to induce bronchodilation.
- Blocking the cough center in the medulla.

HOSPITAL NAME

Franklin Lakes AH

Typically, drugs that are used to suppress coughing are categorized as opioid or non-opioid antitussive agents.

REFERRING VET

Dr. Ward

a) Non-opioid antitussives

INVOICE

Dextromethorphan

91434

Dextromethorphan is a synthetic cough suppressant that acts centrally to elevate the cough threshold but does not have addictive, analgesic, or sedative effects. At normal doses, it does not produce respiratory depression or inhibit ciliary activity. Its antitussive effects may persist for up to 5 hours.

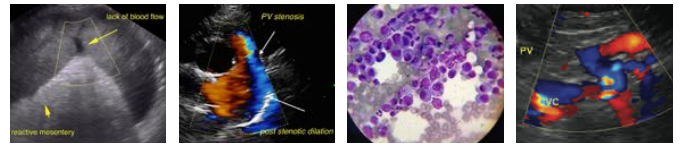
DATE

Dogs only: 0.1-0.2 mg/kg up to 4 times daily.

8/24/21

b) Opioid antitussives

Codeine phosphate



PATIENT

Albert Dragosh

Due to reduced first-pass hepatic metabolism, codeine has a high oral-parenteral potency for an opioid. Oral administration of codeine provides approximately 60% of its parenteral efficacy. Often the dose may need to be increased to achieve a satisfactory effect.

SPECIES

Feline

Hydrocodone

Hydrocodone exhibits the same properties of other opiate agonists but has increased antitussive properties compared to codeine. The mechanism of this effect appears to be a direct suppression of the cough center within the medulla. Hydrocodone may also reduce respiratory mucosal secretions through undetermined mechanisms. **Dogs:** 0.22 mg/kg PO Q6hr. The antitussive effect generally lasts between 6-12 hours. **Cats:** 1.25–5 mg per cat PO Q12hr (ensure no combination with acetaminophen).

BREED

Domestic Shorthair

SEX

Neutered male

Dihydrocodeine

Dihydrocodeine also acts centrally to raise the cough threshold. It is marketed as an elixir, which is relatively palatable and well absorbed. **Dogs:** 1.1-2.2 mg/kg PO Q6hr.

AGE

13 years

Butorphanol

Butorphanol is an effective antitussive and analgesic. In dogs, it has been shown to elevate the CNS respiratory centre threshold to CO₂, but unlike other opioid agonists, it does not suppress respiratory centre sensitivity. Butorphanol is well absorbed orally; however, a significant first-pass effect occurs, resulting in less than 20% of the drug appearing in the systemic circulation. **Dogs:** 0.05-0.1 mg/kg IV/IM/SC or 0.5-1 mg/kg PO TID-QID. **Cats:** 0.2-0.5 mg/kg IV/IM/SC.

INTERPRETED BY

Eric Lindquist, DMV
DABVP, Cert. IVUSS

IMAGING PERFORMED BY

Eric Lindquist, DMV
DABVP, Cert. IVUSS

Diphenoxylate

Diphenoxylate is an opioid agonist traditionally used as an anti-diarrheal agent; however, it also has potent antitussive effects and presumably acts through direct suppression of the cough center.

HOSPITAL NAME

Franklin Lakes AH

4. Inflammation and Pain

REFERRING VET

Dr. Ward

In most respiratory diseases, arachidonic acid is released from reactive cells during tissue inflammation and is converted into a number of derivatives. Among them are prostaglandins and leukotrienes, which are powerful endogenous bronchoconstrictors.

INVOICE

91434

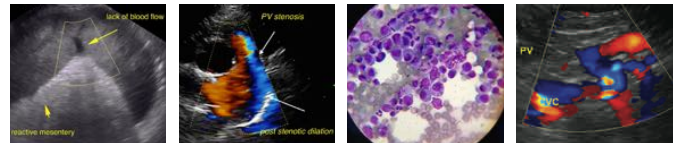
a) Corticosteroids

Glucocorticoids induce the formation of lipocortins in cells containing glucocorticoid receptors. These lipocortins then inhibit phospholipase A2, which is responsible for the mobilization of arachidonic acid from membrane lipids. Corticosteroids are therefore effective in preventing the bronchoconstriction often associated with inflammatory conditions.

DATE

8/24/21

Indications for the use of corticosteroids include rhinitis, laryngitis, bronchitis, and allergic lung disease. Inhaled steroids are the standard of care for humans with asthma and can be used with an equal success



PATIENT

Albert Dragosh

rate in the treatment of dogs and cats with respiratory diseases. Budesonide, flunisolide, and fluticasone are all options. **Dogs:** 110 mcg PO BID for dogs that weigh less than 20 kg and 220 mcg PO BID for those that weigh more than 20 kg. **Cats:** 20-50 mcg/kg PO Q6-8hr (maximum 100 mcg/kg PO Q6hr). These drugs are administered using a spacer (pediatric aerochamber or AeroKat® inhaler).

SPECIES

Feline

b) Antihistamines

Histamine released due to inflammation or hypersensitivity reactions results in the contraction of bronchial smooth muscle via H₁ receptors in dogs. In cats, however, it causes the relaxation of respiratory smooth muscle by stimulating both H₁ and H₂ receptors. Antihistamines counter bronchoconstriction and will often help to control coughing in dogs.

BREED

Domestic Shorthair

SEX

Neutered male

Diphenhydramine

Diphenhydramine reduces the bronchoconstriction, production of secretions, and respiratory irritation due to its local anesthetic effect; it also has a strong sedative effect.

AGE

13 years

c) Nonsteroidal anti-inflammatory drugs (NSAIDs)

INTERPRETED BY

Eric Lindquist, DMV
DABVP, Cert. IVUSS

NSAIDs inhibit the metabolism of arachidonic acid at one or more steps, limiting the production of the inflammatory mediators, prostaglandins, and thromboxane. They have a limiting action on inflammation and have potent analgesic and antipyretic effects. Yet, because they inhibit the COX enzyme system, shunting towards the LOX pathway occurs, which promotes the formation of leukotrienes; the latter are potent bronchoconstrictors.

IMAGING PERFORMED BY

Eric Lindquist, DMV
DABVP, Cert. IVUSS

Bacterial infections

Bacterial infections of the respiratory system are a common occurrence in dogs, but less so in cats. They often transpire after the pulmonary defense mechanisms have been compromised by one of the following: aspiration of foreign material; chronic bronchial disease; foreign bodies; or viral diseases. The organisms that most commonly cause pneumonia in dogs include: *Pasteurella multocida*, *Streptococcus* spp., *Staphylococcus* spp., *Pseudomonas*, *Escherichia coli*, *Klebsiella* spp., and *Bordetella bronchiseptica*.

HOSPITAL NAME

Franklin Lakes AH

REFERRING VET

Dr. Ward

Ideally, the selection of antibiotics should be based on bacterial culture and sensitivity testing; however, empirical or initial antibiotic selection can be based on an examination of the tracheal wash. The identification of cocci usually indicates a streptococci or staphylococci, which are gram-positive and often susceptible to amoxicillin, potentiated sulphonamides, and cephalosporins. Bacterial rods are usually gram-negative bacteria and suitable antibiotics include potentiated sulphonamides, gentamicin, amikacin, and fluoroquinolones. In cases where it is not possible to identify the bacteria, antibiotics should be selected to cover both gram-negative and gram-positive possibilities, such as penicillin with gentamicin and potentiated penicillins (amoxicillin with clavulanic acid).

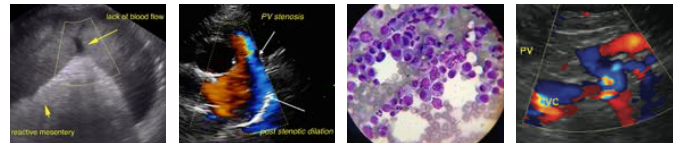
INVOICE

91434

DATE

8/24/21

Concentrations of antibiotics within the pulmonary parenchyma tend to correlate well with serum concentrations. Some antibiotics, such as fluoroquinolones, will result in concentrations in the lungs that are 4-5 times higher than those found in the serum. In most infections, the routine administration of



PATIENT

Albert Dragosh

appropriate antibiotics is adequate to achieve a therapeutic response; however, in severe cases, antibiotics should be administered intravenously for the first 3-7 days. Therapy should be administered for 4-8 weeks, ideally 1-2 weeks after resolution of the condition.

SPECIES

Feline

BREED

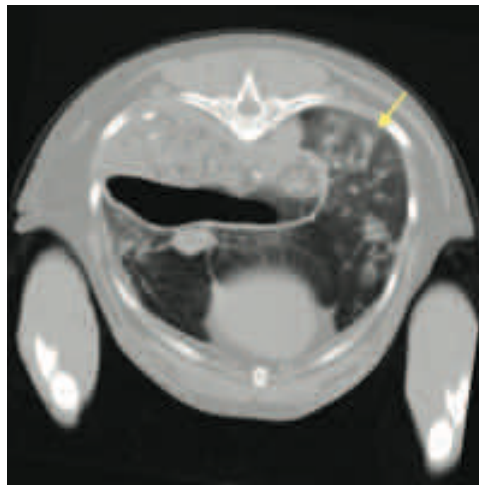
Domestic Shorthair

SEX

Neutered male

AGE

13 years



Transverse computed tomographic image of the chest in a cat with chronic bronchopneumonia. Multifocal bronchial wall thickening with peribronchial interstitial infiltrate is seen (arrow). Note the cortication of the lung lobes indicating pleural fibrosis. The esophagus is dilated with food and gas as a sequel to general anesthesia with gastroesophageal reflux.

INTERPRETED BY

Eric Lindquist, DMV
DABVP, Cert. IVUSS

IMAGING PERFORMED BY

Eric Lindquist, DMV
DABVP, Cert. IVUSS

HOSPITAL NAME

Franklin Lakes AH

REFERRING VET

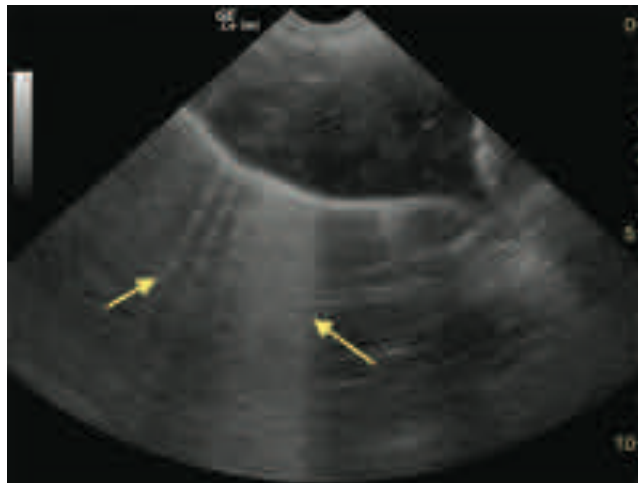Dr. Ward

INVOICE

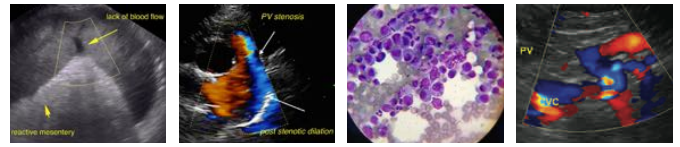
91434

DATE

8/24/21



Subphoidal transdiaphragmatic scan of the lung in a dog. The liver is seen in the near field. "Comet tail" (small arrow) or "shower curtain" (large arrow) artifacts originating from the lung surface deep to the diaphragm indicate the presence of multifocal interstitial pulmonary infiltrate as may be seen with pulmonary metastases, pulmonary thromboemboli and other. These lesions can often be seen sonographically before radiographic detection in some cases with increased clinical significance when an elevated resting respiratory rate (> 35 RPM) is present.



PATIENT

Albert Dragosh

SPECIES

Feline

BREED

Domestic Shorthair

SEX

Neutered male

AGE

13 years

INTERPRETED BY

Eric Lindquist, DMV
DABVP, Cert. IVUSS

IMAGING PERFORMED BY

Eric Lindquist, DMV
DABVP, Cert. IVUSS

HOSPITAL NAME

Franklin Lakes AH

REFERRING VET

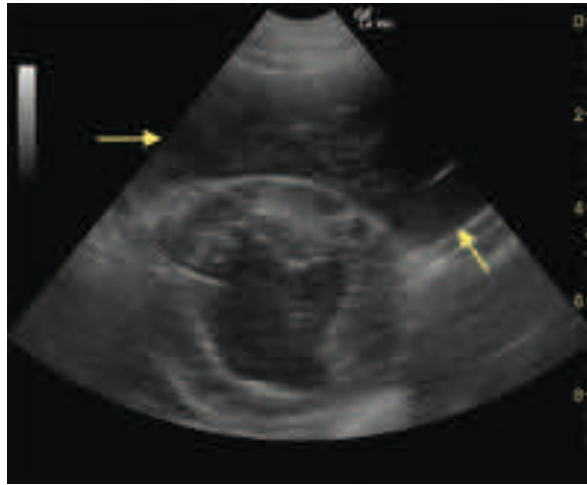
Dr. Ward

INVOICE

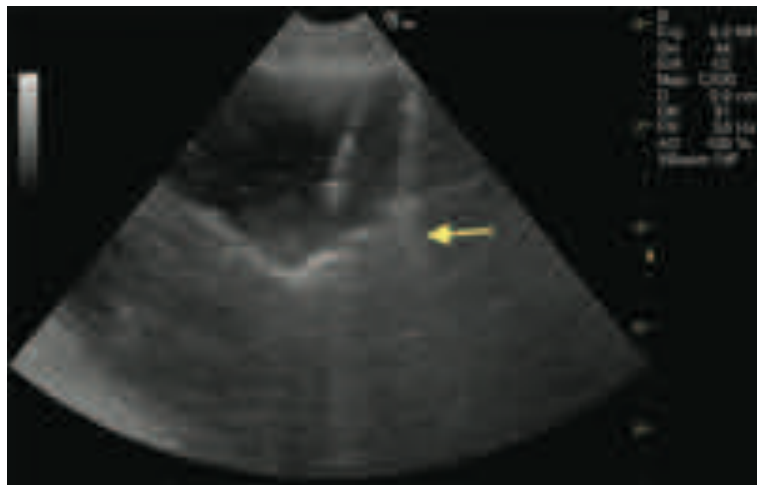91434

DATE

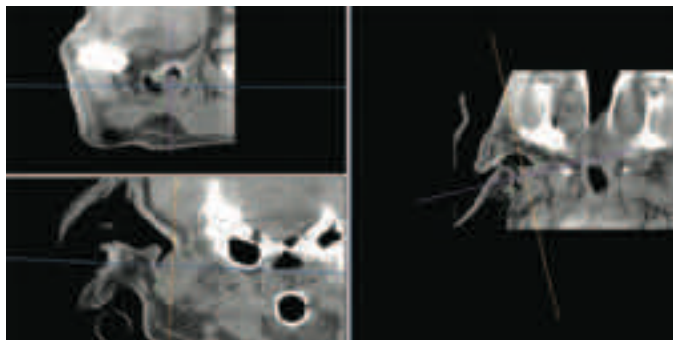
8/24/21



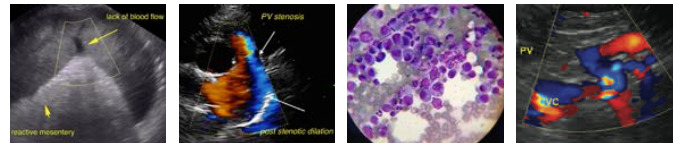
Intercostal scan of the chest in a dog with a histiocytic sarcoma within the left cranial lung lobe (arrows). Note the lack of aeration within the pulmonary parenchyma which enables penetration of ultrasound waves through the entire lung lobe. The heart is seen deep to the lung lobe in short axis. The neoplastic infiltrate has led to volume increase within the affected lobe.



Intercostal scan of the lung of the same dog as in previous image during ultrasound guided biopsy of the lung. The hyperechoic core biopsy needle is seen within the tumor tissue. Development of a relevant pneumothorax is rare in dogs when the needle tract does not interfere with aerated lung tissue. Note the peripheral echogenic aeration of the mass margins (arrow) indicative of lung tissue origin.



7-year-old MN Cocker Spaniel with a history of ear infections and upper respiratory disease. The computed tomographic findings are compatible with a neoplastic mass lesion within the right external auditory canal (arrows) and mild reactive lymphadenopathy. Differential diagnosis includes an inflammatory polyp next to various types of mesenchymal and epithelial soft tissue neoplasia. CT



PATIENT

Albert Dragosh

Images: Vimago by Epica Medical International

SPECIES

Feline

BREED

Domestic Shorthair

SEX

Neutered male

AGE

13 years

INTERPRETED BY

Eric Lindquist, DMV
DABVP, Cert. IVUSS

IMAGING PERFORMED BY

Eric Lindquist, DMV
DABVP, Cert. IVUSS

HOSPITAL NAME

Franklin Lakes AH

REFERRING VET

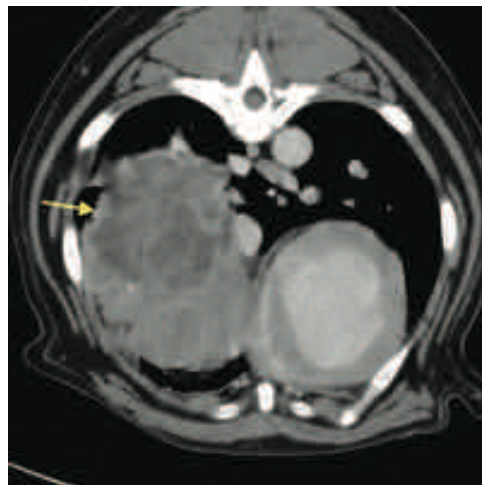Dr. Ward

INVOICE

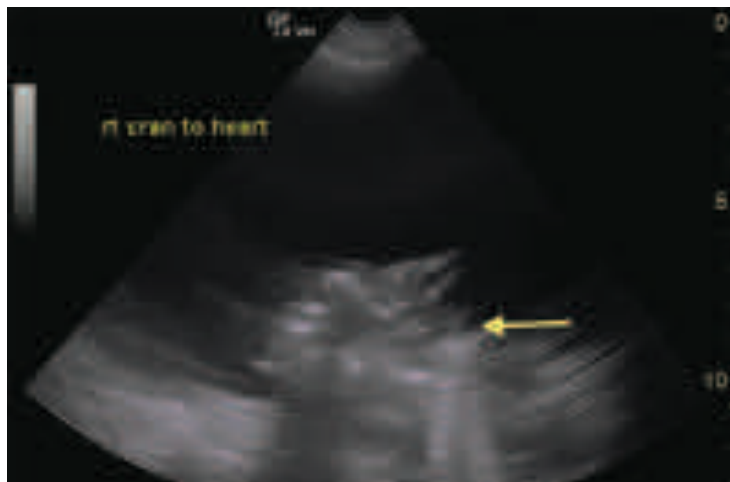91434

DATE

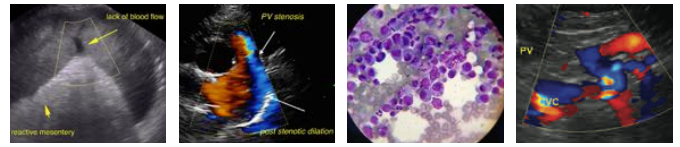
8/24/21



Transverse post contrast computed tomographic image of a dog with a pulmonary histiocytic sarcoma (arrow). Note the large space occupying lesion with heterogenous contrast enhancement within the right middle lung lobe. Also note the mass effect recognized by a significant mediastinal shift and leftward displacement of the caudal vena cava. CT Image courtesy of Nele Ondreka DipDECVDI, Giessen, Germany



Right parasternal intercostal scan of the pleural cavity in a dog with a lung mass. The lung lobes are retracted from the chest wall. Note the uneven surface (arrow) and irregular displacement of air by the neoplastic infiltrate within the lung. A large amount of anechoic pleural effusion is present compatible with carcinomatosis.



PATIENT

Albert Dragosh

SPECIES

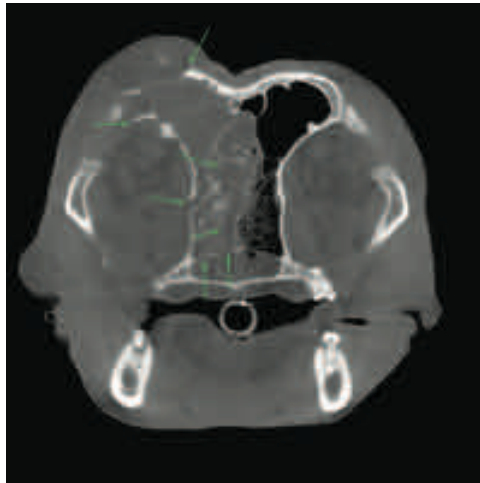Feline

BREED

Domestic Shorthair

SEX

Neutered male



The computed tomographic findings of a Geriatric Boxer dog with chronic nasal discharge are compatible with a malignant nasal soft tissue neoplasia with infiltrative growth and aggressive bone destruction. Likely differential diagnoses include adenocarcinoma, squamous cell carcinoma, lymphosarcoma, melanoma, fibrosarcoma and other. Complete resection unfortunately is not an option. CT Images: Vimago by Epica Medical International

AGE

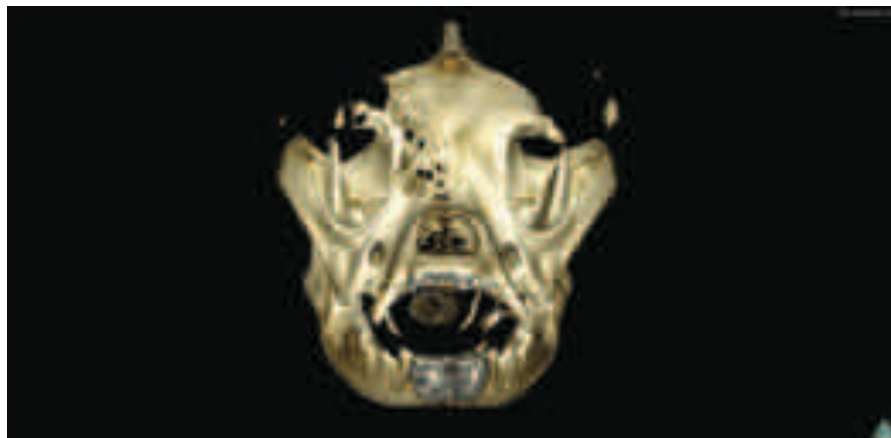13 years

INTERPRETED BY

Eric Lindquist, DMV
DABVP, Cert. IVUSS

IMAGING PERFORMED BY

Eric Lindquist, DMV
DABVP, Cert. IVUSS



3D rendering of the aggressive nasal mass noted in the prior image. CT Images: Vimago by Epica Medical International

HOSPITAL NAME

Franklin Lakes AH

REFERRING VET

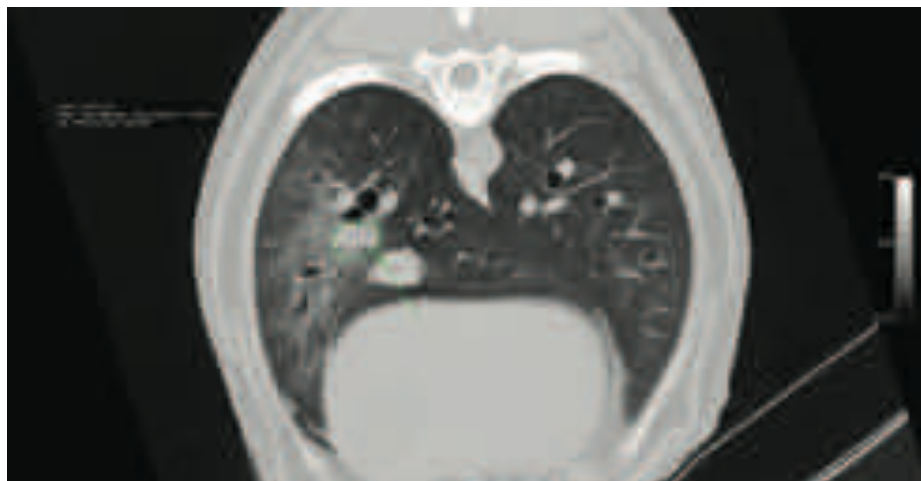Dr. Ward

INVOICE

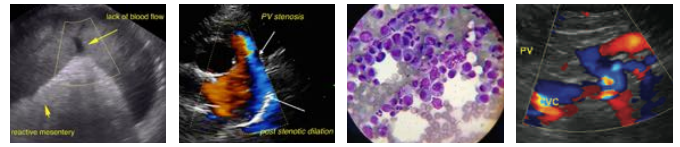
91434

DATE

8/24/21



Transverse CT view of the thorax level with the caudal lung lobes in a dog with inhalational pneumonia and grass awn migration. Note the focal hyperattenuating alveolar infiltrate ventral to the significantly dilated bronchus (arrow). The wide extent of the inflammatory changes is indicated by a diffuse



PATIENT

Albert Dragosh

SPECIES

Feline

BREED

Domestic Shorthair

SEX

Neutered male

AGE

13 years

INTERPRETED BY

Eric Lindquist, DMV
DABVP, Cert. IVUSS

**IMAGING
PERFORMED BY**

Eric Lindquist, DMV
DABVP, Cert. IVUSS

HOSPITAL NAME

Franklin Lakes AH

REFERRING VET

Dr. Ward

INVOICE

91434

DATE

8/24/21

interstitial ground glass opacity, bronchial widening and wall thickening ventrally within the right caudal lobe. CT Image courtesy of Nele Ondreka DipDECVDI, Giessen, Germany

References:

Cohn LA, Reiner CR. Respiratory defenses in health and disease. *Vet Clin North Am Small Anim Pract* 2007;37:845-60.

Epstein SE, Mellema MS, Hopper K. Airway microbial culture and susceptibility patterns in dogs and cats with respiratory disease of varying severity. *J Vet Emerg Crit Care* 2010;20:587-94.

Hackett, TB. Canine respiratory emergencies. Proceedings from the Western Veterinary Conference: Emergency and Critical Care, Las Vegas, NV, February 19-23, 2012.

Johnson LR, Queen EV, Vernau W, et al. Microbiologic and cytologic assessment of bronchoalveolar lavage fluid from dogs with lower respiratory tract infection: 105 cases (2001-2011). *J Vet Intern Med* 2013;27:259-67.

Maggs DJ. Antiviral therapy for feline herpes virus infections. *Vet Clin North Am Small Anim Pract* 2010;40:1055-62.

Miller CJ. Approach to the respiratory patient. *Vet Clin North Am Small Anim Pract* 2007;37:861-78.

Rozanski EA, Bach JF, Shaw SP. Advances in respiratory therapy. *Vet Clin North Am Small Anim Pract* 2007;37:963-74.

Rozanski E, Chan DL. Approach to the patient with respiratory distress. *Vet Clin North Am Small Anim Pract* 2005;35:307-17.

Sumner C, Rozanski E. Management of respiratory emergencies in small animals. *Vet Clin North Am Small Anim Pract* 2013;43:799-815.