



PATIENT

Sofi Louise Terrwilliger

SPECIES

Canine

BREED

Standard Poodle

SEX

Spayed female

AGE

7 years

WEIGHT

39 lbs

INTERPRETED BY

Eric Lindquist, DMV
DABVP, Cert. IVUSS

IMAGING PERFORMED BY

JK

HOSPITAL NAME

Hamburg VC

REFERRING VET

Dr. Martens

INVOICE

46736

DATE

8/23/23

PRESENTING CLINICAL SIGNS

History: History of stomach issues. Uncomfortable after eating. Gassy, On HP diet. No vomiting or diarrhea

Abnormal PE/Chem/CBC/UA Results: Blood normal

ULTRASONOGRAPHIC EXAMINATION OF THE ABDOMEN

Urinary System

The **urinary bladder**, trigone, and pelvic urethra presented normal thicknesses and normal tone. The ureters were not visible which is normal. No uroliths or sediment were visualized and anechoic urine was present. No evidence of inflammatory or neoplastic changes was noted. Ureteral papillae were normal.

The **kidneys** revealed normal size and structure, corticomedullary definition and ratio for this age. The cortices presented largely uniform texture with normal echogenic relationship to liver and spleen. Medullary structure differed distinctly from the cortex and no evidence of pelvic dilation was present. The capsules were acceptably uniform without significant irregularities. The left kidney measured 5.7 cm. The right kidney measured 6.3 cm.

Adrenal Glands

Both **adrenal glands** were not visualized.

Spleen

The **spleen** presented a smooth homogeneous parenchyma hyperechoic to liver and renal cortical parenchyma. The capsule was smooth without noticeable expansion or deviation from within the spleen or adjacent pathology. The splenic vasculature demonstrated normal volume without signs of congestion or thrombosis. No sonographic evidence of acute or chronic inflammatory, neoplastic, or infarctual changes was noted.

Liver

The **liver** images submitted revealed subjectively normal liver size, contour, and structure. Parenchymal echogenicity was naturally coarse and hypoechoic to the spleen. Vascular and biliary tracts were of normal volume with no evidence of congestion. The gallbladder presented acceptably thin walls with primarily anechoic content. The cystic and common bile ducts were normal. No pathological hepatic lymphadenopathy was evident. No overt structural evidence of inflammatory, infiltrative or regenerative pathology was evident.

Gastrointestinal

Examination of the **gastrointestinal tract** revealed a stomach and intestine free of stasis, of normal wall thickness, acceptable curvilinear mural detail, and peristaltic activity. Small and large intestine



PATIENT

Sofi Louise Terrwilliger

demonstrated normal luminal chyme and stool consistency respectively. No obstructive or overt infiltrative disease was noted. No associated abnormal lymphatic activity was noted.

SPECIES

Canine

Pancreas

The base and limbs of the **pancreas** were observed to be largely isoechoic to surrounding omental fat. Pancreatic duct and capsular contour were acceptably normal and parenchyma respected normal curvilinear patterns. No overt evidence of active inflammatory or neoplastic disease was noted.

BREED

Standard Poodle

ULTRASONOGRAPHIC FINDINGS

Structurally unremarkable abdomen.

SEX

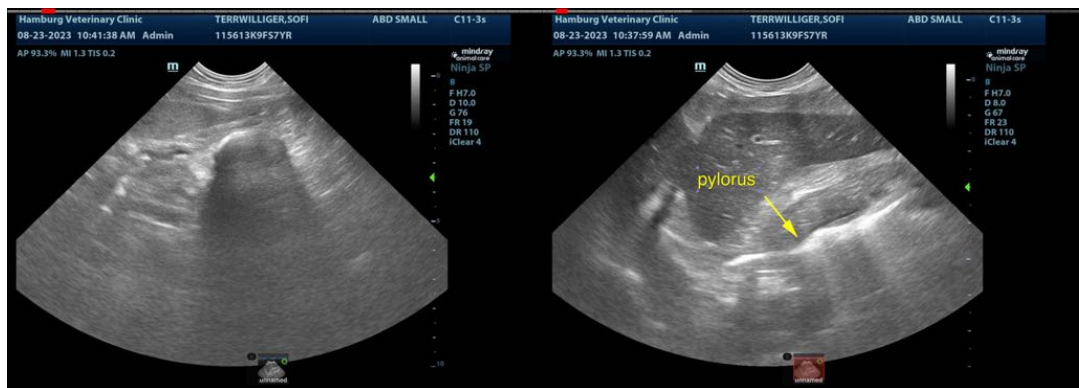
Spayed female

INTERPRETATION OF THE FINDINGS & FURTHER RECOMMENDATIONS

Screening for Addison's is warranted given the breed predisposition and anti-parasitic. B.i.d. canned feedings are warranted followed by reassessment of the clinical status.

WEIGHT

39 lbs

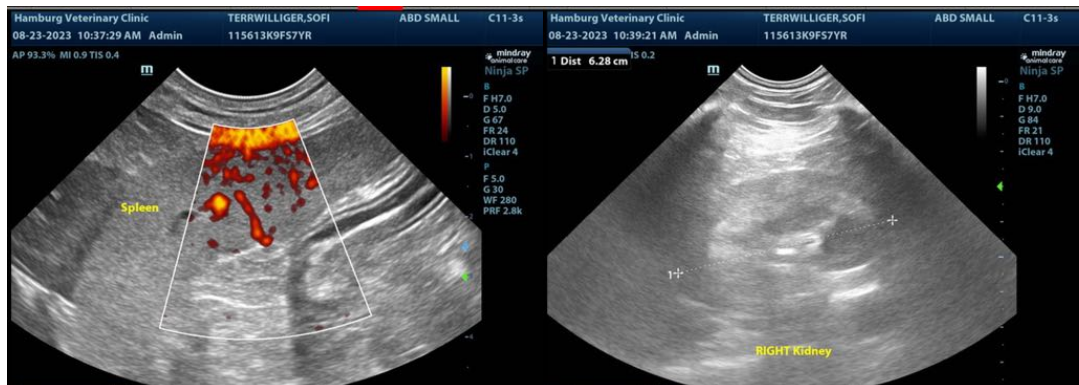


INTERPRETED BY

Eric Lindquist, DMV
DABVP, Cert. IVUS

IMAGING PERFORMED BY

JK



HOSPITAL NAME

Hamburg VC

REFERRING VET

Dr. Martens

INVOICE

46736

DATE

8/23/23



PATIENT

Sofi Louise Terrwilliger

SPECIES

Canine

BREED

Standard Poodle

SEX

Spayed female

AGE

7 years

WEIGHT

39 lbs

INTERPRETED BY

Eric Lindquist, DMV
DABVP, Cert. IVUSS

IMAGING PERFORMED BY

JK

HOSPITAL NAME

Hamburg VC

REFERRING VET

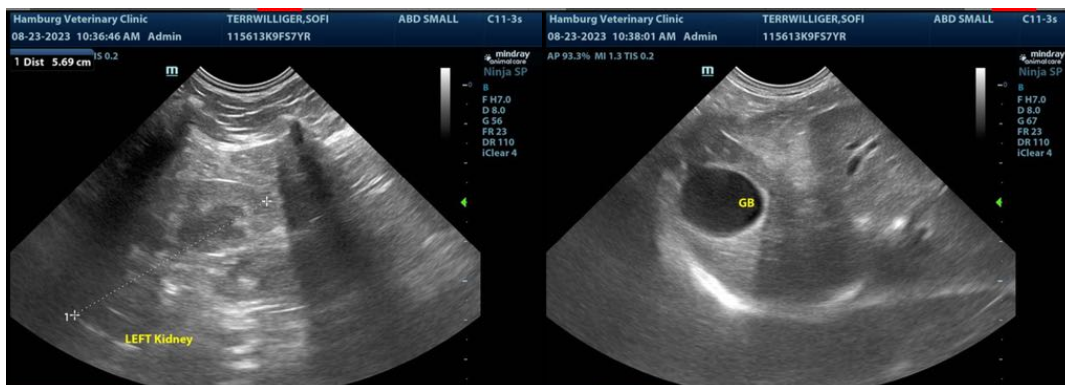
Dr. Martens

INVOICE

46736

DATE

8/23/23



The information and recommendations provided are based on the images presented by the referring veterinarian/sonographer. No evaluation can be communicated regarding pathology that was not visible in the image/video clips provided.

Thank you for this referral. If the clinical or image interpretation does not parallel your findings or if I can be of any further assistance please contact me.

Eric Lindquist, DMV, DABVP, Cert. IVUSS, CEO of SonoPath.com
info@SonoPath.com