



PATIENT

MAVI Garcia

SPECIES

Canine

BREED

Schnauzer Mix

SEX

Spayed female

AGE

5 years

WEIGHT

14.2 lbs

INTERPRETED BY

Eric Lindquist, DMV
DABVP, Cert. IVUSS

IMAGING PERFORMED BY

Julissa Diaz

HOSPITAL NAME

Centro Veterinario Del
Norte

REFERRING VET

Dr. Trinidad

INVOICE

32497

DATE

8/23/22

PRESENTING CLINICAL SIGNS

History: Presented for abdominal ultrasound on referral. Dog has had persistently elevated ALP, ALT since 2020. Recently hospitalized for vomiting. Referring vet wants to rule out hepatic mass or other hepatic disease.

ULTRASONOGRAPHIC EXAMINATION OF THE ABDOMEN

Urinary System

The **urinary bladder**, trigone, and pelvic urethra presented normal thicknesses and normal tone. The ureters were not visible which is normal. No uroliths or sediment were visualized and anechoic urine was present. No evidence of inflammatory or neoplastic changes was noted. Ureteral papillae were normal.

The **kidneys** revealed normal size and structure, corticomedullary definition and ratio for this age. The cortices presented largely uniform texture with normal echogenic relationship to liver and spleen. Medullary structure differed distinctly from the cortex and no evidence of pelvic dilation was present. The capsules were acceptably uniform without significant irregularities. Both kidneys measured 4.0 cm each with pinpoint mineralization.

Adrenal Glands

Both **adrenal glands** were visualized and recognized as having normal shape, size, position and echogenicity for this breed. The phrenic vasculature, glandular echogenicity and detail were unremarkable. Capsule, cortex, and medullary definition were normal for this age patient. The left adrenal gland measured 0.5 cm.

Spleen

The **spleen** presented a smooth homogeneous parenchyma hyperechoic to liver and renal cortical parenchyma. The capsule was smooth without noticeable expansion or deviation from within the spleen or adjacent pathology. The splenic vasculature demonstrated normal volume without signs of congestion or thrombosis. No sonographic evidence of acute or chronic inflammatory, neoplastic, or infarctual changes was noted.

Liver

The **liver** images submitted revealed subjectively normal liver size, contour, and structure. Parenchymal echogenicity was naturally coarse and hypoechoic to the spleen. Vascular and biliary tracts were of normal volume with no evidence of congestion. The gallbladder presented acceptably thin walls with primarily anechoic content. The cystic and common bile ducts were normal. No pathological hepatic lymphadenopathy was evident. No overt structural evidence of inflammatory, infiltrative or regenerative pathology was evident.



PATIENT

Gastrointestinal

MAVI Garcia

There was some residual chyme and gas was noted in the **stomach**, yet not pathological. This is consistent with end post prandial presentation. Some echogenic round structures were noted in the stomach. This is consistent with kibble or possible medications. These are non-obstructive and non pathological. Transit of chyme into the small intestine was normal. Curvilinear patterns were maintained throughout the GI tract. No evidence of pathology. Small and large intestine demonstrated normal luminal chyme and stool consistency respectively. No obstructive or overt infiltrative disease was noted. No associated abnormal lymphatic activity was noted.

SPECIES

Canine

BREED

Schnauzer Mix

SEX

Spayed female

Pancreas

The base and limbs of the **pancreas** were observed to be largely isoechoic to surrounding omental fat. Pancreatic duct and capsular contour were acceptably normal and parenchyma respected normal curvilinear patterns. No overt evidence of active inflammatory or neoplastic disease was noted.

AGE

5 years

ULTRASONOGRAPHIC FINDINGS

Structurally unremarkable abdomen.

WEIGHT

14.2 lbs

Benign hepatopathy.

INTERPRETATION OF THE FINDINGS & FURTHER RECOMMENDATIONS

INTERPRETED BY

Eric Lindquist, DMV
DABVP, Cert. IVUSS

There was no evidence of significant pathology. FNA of the liver can be considered to assess inflammatory cell type.

IMAGING PERFORMED BY

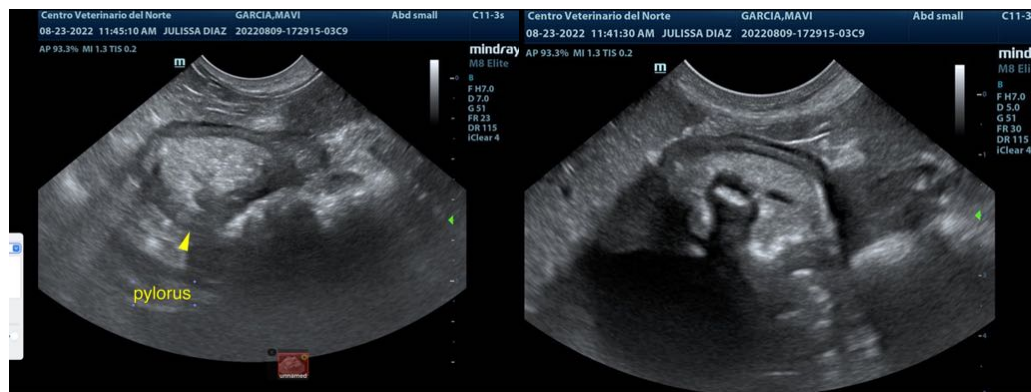Julissa Diaz

HOSPITAL NAME

Centro Veterinario Del Norte

REFERRING VET

Dr. Trinidad



INVOICE

32497

DATE

8/23/22



PATIENT

MAVI Garcia

SPECIES

Canine

BREED

Schnauzer Mix

SEX

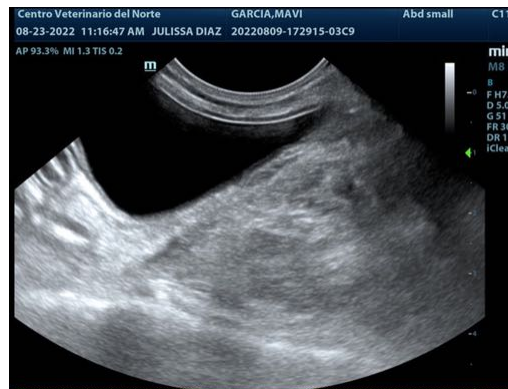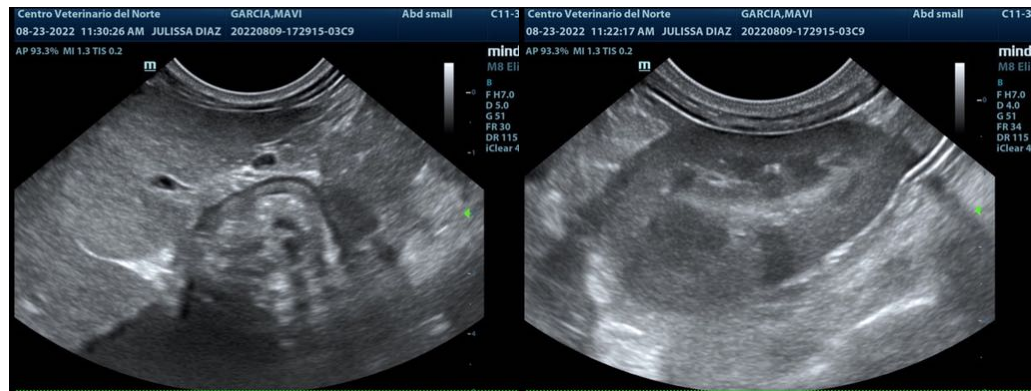
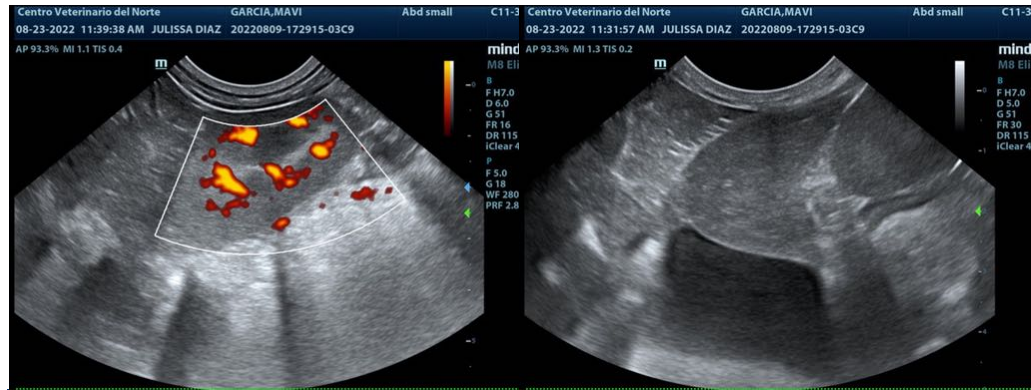
Spayed female

AGE

5 years

WEIGHT

14.2 lbs



INTERPRETED BY

Eric Lindquist, DMV
DABVP, Cert. IVUSS

IMAGING PERFORMED BY

Julissa Diaz

HOSPITAL NAME

Centro Veterinario Del Norte

REFERRING VET

Dr. Trinidad

INVOICE

32497

DATE

8/23/22

The information and recommendations provided are based on the images presented by the referring veterinarian/sonographer. No evaluation can be communicated regarding pathology that was not visible in the image/video clips provided.

Thank you for this referral. If the clinical or image interpretation does not parallel your findings or if I can be of any further assistance please contact me.

Eric Lindquist, DMV, DABVP, Cert. IVUSS, CEO of SonoPath.com
info@SonoPath.com