



**PATIENT PRESENTING CLINICAL SIGNS**

Kindra George

History: Prev echo 6/20/22. Current medications since prev echo: Enalapril: 15mg SID, Vetmedin 6.25mg BID, Spironolactone 25mg BID. lasix 40mg BID. BP today: systolic: 117

**SPECIES BREED SEX AGE WEIGHT INTERPRETED BY**

Canine

Labrador

Spayed female

14 years

52.8 lbs

Eric Lindquist, DMV  
DABVP, Cert. IVUSS

Dr. Rodriguez

Foxfield VS

Dr. Rodriguez

32491

8/23/22

**ULTRASONOGRAPHIC EXAMINATION OF THE HEART**

The echocardiogram in this patient demonstrated normal **left atrial** size based on 3 separate methods of LA evaluation. **Mitral** valve insufficiency was noted. The **left ventricle** presented thicknesses with linear contour and was not dilated nor restricted. The **myocardium** presented normal echogenicity without subjective evidence of significant fibrotic or ischemic disease. **Contractility** was adequate. Minor **aortic insufficiency** was noted. The **right atrium** and auricle revealed normal size, structure and content. No evidence of masses was noted. **Tricuspid** valvular assessment demonstrated adequate linear morphology and kinesis. The **right ventricle** was of normal size (1/3 diameter of LV), chordae structure, myocardial echogenicity and thickness. **Pulmonary outflow** tract assessment revealed normal valve structure, laminar flow, and diameter (approx.1:1 pa/ao ratio). No visible **pericardial** or free pleura fluid was noted. The cranial **mediastinum and pericardial and extra-cardiac regions** were free of masses in the visible window. Periodic arrhythmia was noted.

CANINE CARDIAC PARAMETERS	MR VMAX (m/s)	TR VMAX (m/s)	LA/AO (Boon method)	LA/AO (Heart Base; Swe)	FS (%)	EF (%)	EPSS (cm)
NORMAL PARAMETER	4.5-5.5	<2.7	1.3	<1.6	28-40	40-100	<0.6
PATIENT	6.0		1.0		35	60	NM
CANINE CARDIAC PARAMETERS	HR (BPM)	AV VMAX (m/s)	PV MAX (m/s)	BODY WEIGHT (kg)	LA (2D short axis Base view) (cm)	LVIDd (Avg; 2D and m-mode short axis) (cm)	LVIDs (Avg; 2D and m-mode short axis) (cm)
NORMAL PARAMETER	50-100	0.7-1.7	0.7-1.6	BELOW	BELOW	BELOW	BELOW
PATIENT		1.3	0.7	52.8 lbs	3.1 max	4.25	

**ULTRASONOGRAPHIC FINDINGS**

Mitral and aortic insufficiency.  
Compensated valvular disease.  
Trivial pulmonic insufficiency noted.  
Occasional arrhythmia.



**PATIENT**

Kindra George

**SPECIES**

Canine

**BREED**

Labrador

**SEX**

Spayed female

**AGE**

14 years

**WEIGHT**

52.8 lbs

**INTERPRETED BY**

Eric Lindquist, DMV  
DABVP, Cert. IVUSS

**IMAGING PERFORMED BY**

Dr. Rodriguez

**HOSPITAL NAME**

Foxfield VS

**REFERRING VET**

Dr. Rodriguez

**INVOICE**

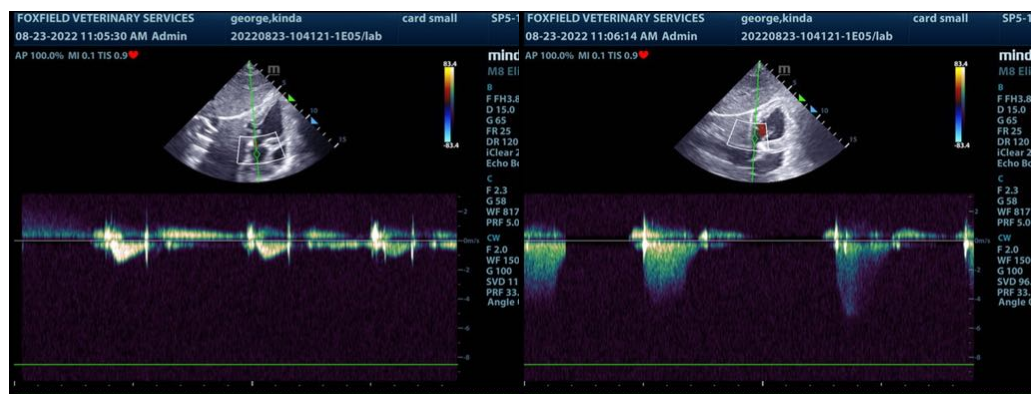
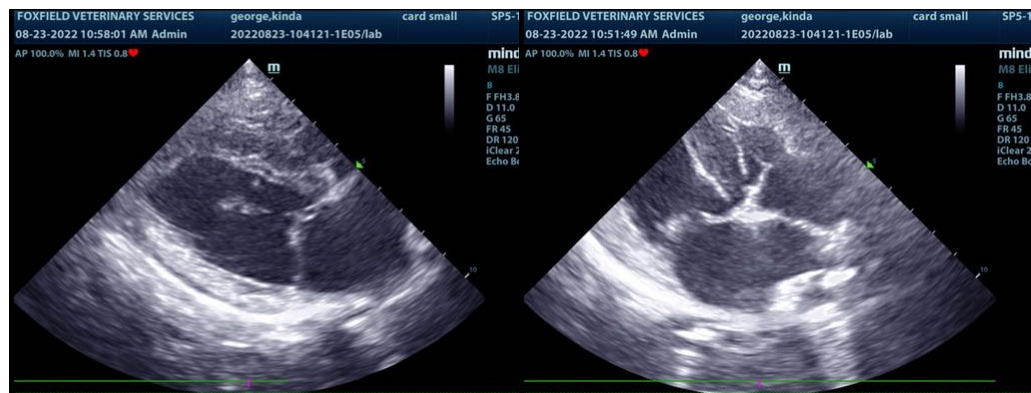
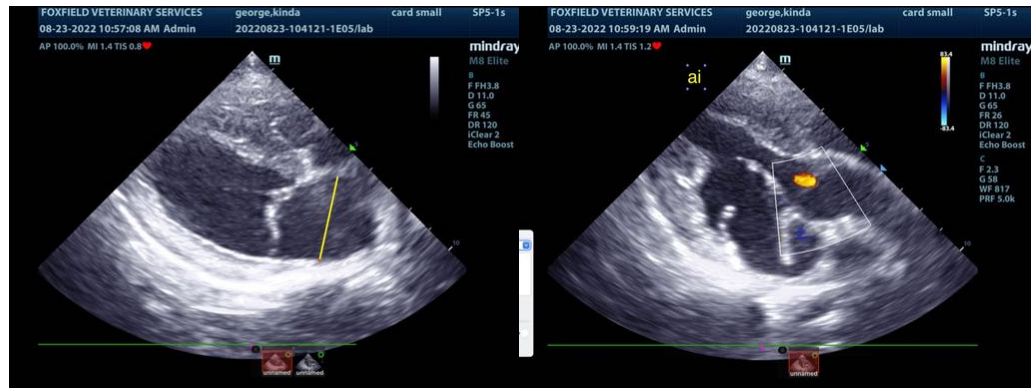
32491

**DATE**

8/23/22

**INTERPRETATION OF THE FINDINGS & FURTHER RECOMMENDATIONS**

The heart appears stable regarding contractility and volume. EKG is indicated. I believe that the Lasix dose can be diminished and can be halved in this patient with a recheck of the underlying sleeping respiratory rate that should be <25/minute. Otherwise, the other medication should be maintained. It is possible that this patient underwent an inciting episode such as myocarditis in the past or possible nutritional issues as the heart appears to have responded dramatically to the prior presentation. Recheck echocardiogram is recommended in 6 months if stable.





**PATIENT**

Kindra George

**SPECIES**

Canine

**BREED**

Labrador

**SEX**

Spayed female

**AGE**

14 years

**WEIGHT**

52.8 lbs

**INTERPRETED BY**

Eric Lindquist, DMV  
DABVP, Cert. IVUSS

**IMAGING PERFORMED BY**

Dr. Rodriguez

**HOSPITAL NAME**

Foxfield VS

**REFERRING VET**

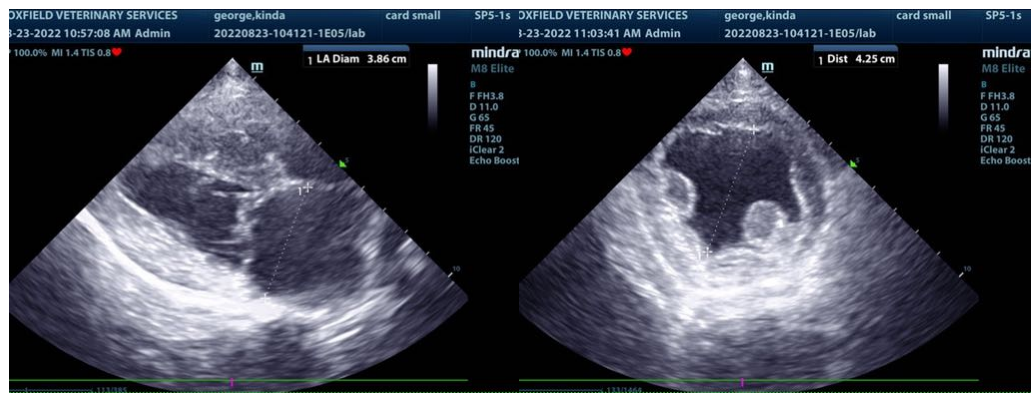
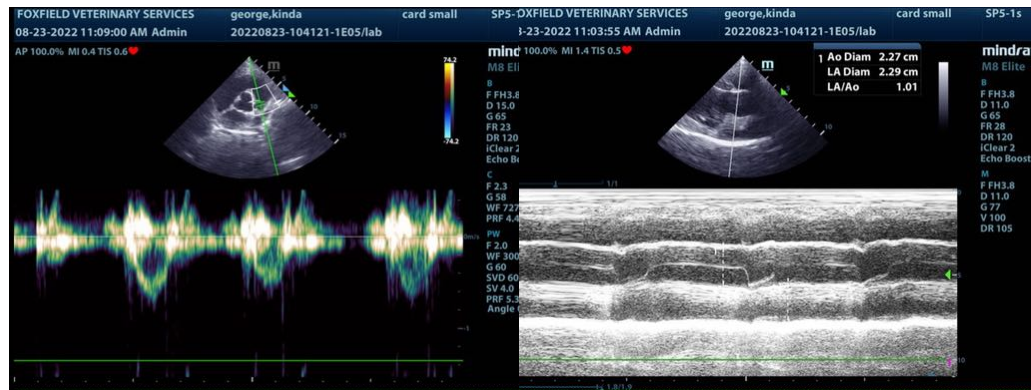Dr. Rodriguez

**INVOICE**

32491

**DATE**

8/23/22



The information and recommendations provided are based on the images presented by the referring veterinarian/sonographer. No evaluation can be communicated regarding pathology that was not visible in the image/video clips provided.

Thank you for this referral. If the clinical or image interpretation does not parallel your findings or if I can be of any further assistance please contact me.

**Eric Lindquist, DMV, DABVP, Cert. IVUSS, CEO of SonoPath.com**  
info@SonoPath.com