



PATIENT PRESENTING CLINICAL SIGNS

Rico Bodden History: Ow mentions that he is doing well in general, a little less active due to age but he does well. He eats, drinks, urinates normally. Defecating is mostly normal but still gets constipated every now and then. Coughs when excited. Patient is QAR at presentation. Heart murmur, left side, grade 5.
SPECIES Periodontal disease grade 4.

Canine Abnormal PE/Chem/CBC/UA Results: Phosphorus: 1.9 mg/dL

BREED ULTRASONOGRAPHIC EXAMINATION OF THE HEART

Chihuahua

SEX Neutered Male The **left atrial** size was slightly enlarged primarily in the LA max measurement, yet normal in the other LA measurements. Chamber volumes and echogenicity were normal. The cranial and caudal **mitral** valve leaflets presented vegetative thickening consistent with endocardiosis. Prolapse of the anterior mitral valve leaflet was noted. Doppler indicated measurable insufficiency. The **left ventricle** presented thicknesses with linear contour and was not dilated nor restricted. The **myocardium** presented normal echogenicity without subjective evidence of significant fibrotic or ischemic disease. **Contractility** of the ventricular walls was adequate and in normal range for this patient evidenced by the fractional shortening measurement and subjective evaluation of the different regions of the myocardium. The **left ventricular outflow** tract demonstrated normal laminar flow and subjective structural integrity. The **right atrium** and auricle revealed normal size, structure and content. No evidence of masses was noted or chamber overload. Trivial **tricuspid** insufficiency was noted. The **right ventricle** was of normal size (1/3 diameter of LV), chordae structure, myocardial echogenicity and thickness. **Pulmonic** tract assessment revealed normal valve structure, laminar flow, and diameter (approx. 1:1 pa/ao ratio). No visible **pericardial** or free pleura fluid was noted. No echographically detectable evidence of infiltrative disease was visible. The cranial **mediastinum** and **pericardial regions** were free of masses in the visible window.

AGE 12 Years

WEIGHT 10.30 Pounds

INTERPRETED BY

Eric Lindquist, DMV
DABVP, Cert. IVUSS

IMAGING PERFORMED BY

Dr. Kim

HOSPITAL NAME

Ridgefield Park AH

REFERRING VET

Dr. Kim

INVOICE

91425

DATE

8/23/21

CANINE	MR	TR	LA/AO	LA/AO	FS	EF	EPSS
CARDIAC PARAMETERS	VMAX (m/s)	VMAX (m/s)	(Boon method)	(Heart Base; Swe)	(%)	(%)	(cm)
NORMAL PARAMETER	4.5-5.5	<2.7	1.3	<1.6	28-40	40-100	<0.6
PATIENT	5.84		NM	1.4	46	79	0.1
CANINE	HR	AV	PV	BODY WEIGHT	LA	LVIDd	LVIDs
CARDIAC PARAMETERS	(BPM)	VMAX (m/s)	MAX (m/s)		2D short axis Base view (cm)	Avg; 2D and m-mode short axis (cm)	Avg; 2D and m-mode short axis (cm)
NORMAL PARAMETER	50-100	0.7-1.7	0.7-1.6	BELOW	BELOW	BELOW	BELOW
PATIENT		1.2		10.3 lbs	3.2 max	2.52	



PATIENT

Rico Bodden

ULTRASONOGRAPHIC FINDINGS

- Early stage B2 valvular disease.

SPECIES

Canine

INTERPRETATION OF THE FINDINGS & FURTHER RECOMMENDATIONS

If vertebral heart score is excessive in this patient then I recommend Pimobendan at 0.3 mg/kg b.i.d. based on EPIC study criteria. Blood pressure measurements are warranted. A recheck echocardiogram is recommended in 3-6 months depending upon murmur grade and clinical status. Assessment of BUN, creatinine, USG, chest radiographs and blood pressure as well as clinical exam is ideal in 7-10 days. Basal respiratory rate should be <20/min.

BREED

Chihuahua

SEX

Neutered Male

AGE

12 Years

WEIGHT

10.30 Pounds

INTERPRETED BY

Eric Lindquist, DMV
DABVP, Cert. IVUSS

IMAGING PERFORMED BY

Dr. Kim

HOSPITAL NAME

Ridgefield Park AH

REFERRING VET

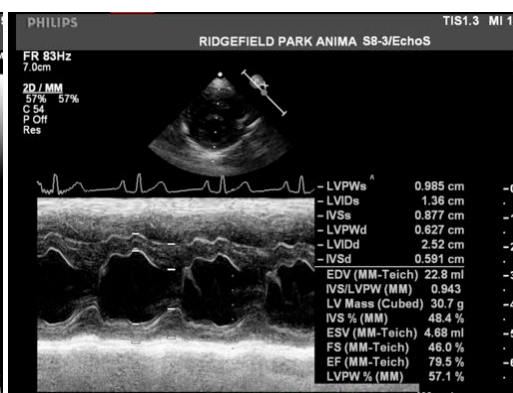
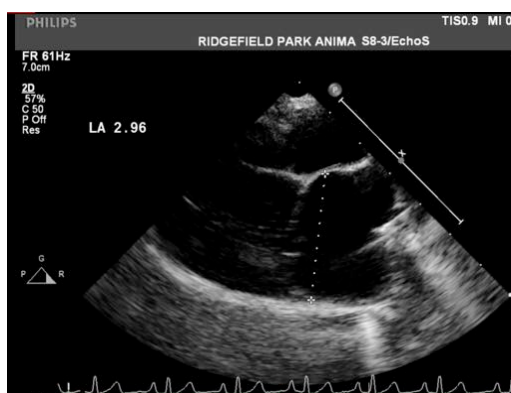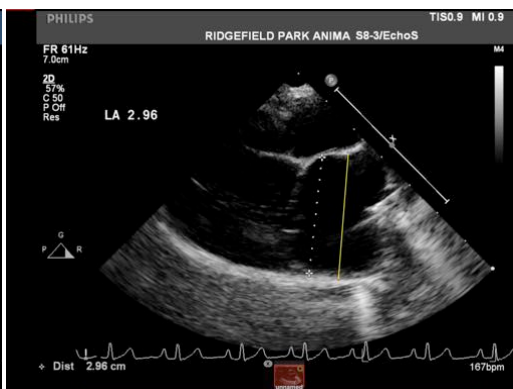
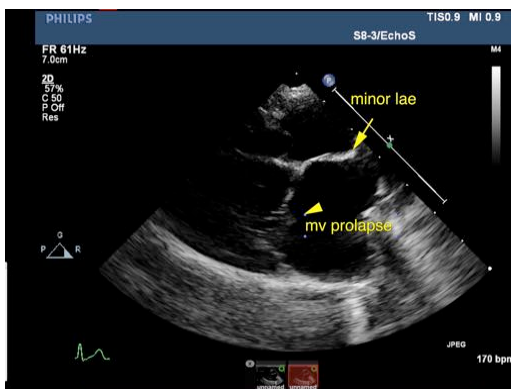
Dr. Kim

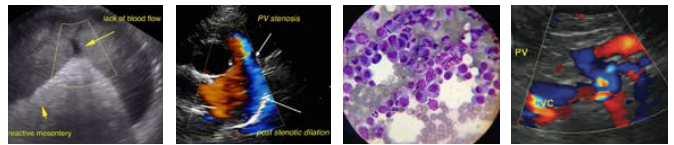
INVOICE

91425

DATE

8/23/21





PATIENT

Rico Bodden

SPECIES

Canine

BREED

Chihuahua

SEX

Neutered Male

AGE

12 Years

WEIGHT

10.30 Pounds

INTERPRETED BY

Eric Lindquist, DMV
DABVP, Cert. IVUSS

IMAGING PERFORMED BY

Dr. Kim

HOSPITAL NAME

Ridgefield Park AH

REFERRING VET

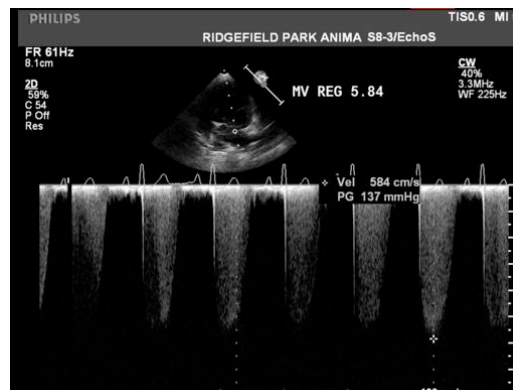
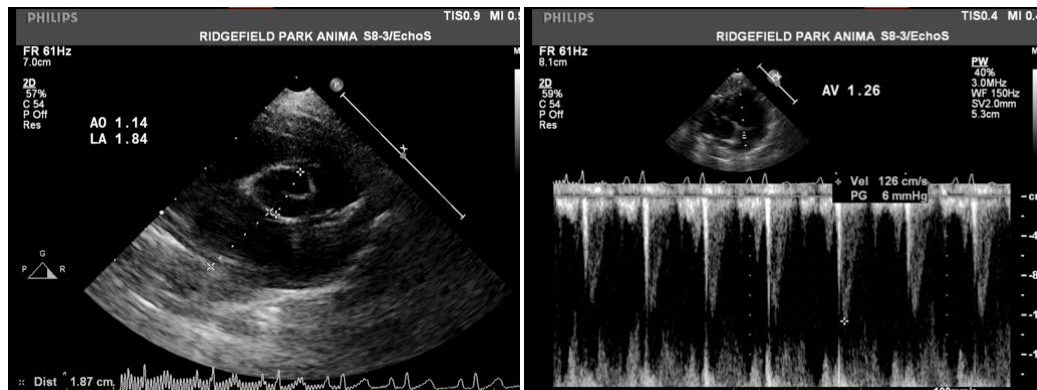
Dr. Kim

INVOICE

91425

DATE

8/23/21



The information and recommendations provided are based on the images presented by the referring veterinarian. No evaluation can be communicated regarding pathology that was not visible in the image/video clips provided.

Thank you for this referral. If the clinical or image interpretation does not parallel your findings or if I can be of any further assistance please contact me.

Eric Lindquist, DMV, DABVP, Cert. IVUSS, CEO of SonoPath.com
info@SonoPath.com

Mitral & Tricuspid Valve Disease

<http://www.sonopath.com/ValveDisease>

Description: Myxomatous valvular degeneration refers to a sterile degenerative disease that affects middle-aged and older dogs. The mitral valve apparatus includes the left ventricular papillary muscles, chordae tendinae, valvular annulus, and anterior and posterior leaflets. The anterior leaflet is continuous with the aortic outflow tract. The accumulation of mucopolysaccharides within the spongiosa and fibrosa layers of the leaflets creates a vegetative nodular appearance. This vegetative pathology may also be the result of bacteremia due to dental disease or a different source of bacterial pervasion. Lengthening of the chordae tendinae occurs secondary to any excessive turbulent forces that might transpire.



PATIENT

Rico Bodden

SPECIES

Canine

BREED

Chihuahua

SEX

Neutered Male

AGE

12 Years

WEIGHT

10.30 Pounds

INTERPRETED BY

Eric Lindquist, DMV
DABVP, Cert. IVUS

IMAGING PERFORMED BY

Dr. Kim

HOSPITAL NAME

Ridgefield Park AH

REFERRING VET

Dr. Kim

INVOICE

91425

DATE

8/23/21

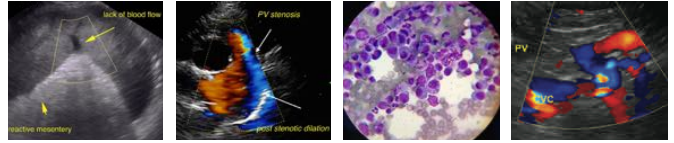
Chondrodystrophic breeds are overrepresented and typically have collapsing trachea and intervertebral disc disease. Cavalier King Charles Spaniels are paradigmatic of this phenomenon; they develop mitral valve disease (MVD) at an early age. MVD prevalence can be as high as 33% in toy breeds over 10 years of age and is the most common cardiac disease in dogs (it accounts for 75-80% of all cases). MVD has also been reported in German Shepherds; they demonstrate a more rapid progression of the disease in comparison to other breeds.

Distortion of the mitral valve leaflets prevents normal coaptation of blood resulting in regurgitative flow of the stroke volume into the left atrium. The lengthening and rupture of the chordae can lead to leaflet prolapse into the atrium and the eventual inversion of the flail leaflet into the atrium, which will in turn exacerbate the regurgitation. Chordae rupture often occurs suddenly, leading to the rapid onset of congestive heart failure (CHF), as the myocardium does not have adequate time to hypertrophy and compensate for the defect. (A small amount of regurgitation can be well tolerated if it progresses more slowly over time.) The result is volume overload of the left atrium and left ventricle, which gives rise to eccentric hypertrophy. Eccentric hypertrophy causes dilation of the mitral annulus, which further complicates the myocardial left atrium and left ventricle stretch. Myocardial oxygen deprivation due to poor coronary perfusion (stretch and catecholamine stimulation) leads to myocardial cell death, replacement fibrosis, and myocardial dysfunction. This pathological progression is known as "overload cardiomyopathy."

Clinical Signs: The most common sign of MVD is a progressive cough; it is due to left-sided volume overload, which in turn precipitates pulmonary edema and left atrial bulging at the left mainstem bronchus. Respiratory distress ensues gradually in chronic cases or rapidly in cases of primary chordae rupture. Exercise intolerance, syncope, ascites, weight loss, and anorexia are also commonly observed. A physical exam will often reveal an audible murmur best heard over the left cardiac apex. The murmur audibility and length into systole typically corresponds to the degree of mitral regurgitation but not necessarily to the severity of the cardiac status. Concurrent systemic hypertension may induce progression of the disease thereby necessitating systemic blood pressure measurements during medical management.

A challenging situation occurs when the practitioner must determine whether the origin of a cough is respiratory (e.g. tracheal collapse, chronic bronchitis, COPD) or cardiac (e.g. pulmonary edema, mainstem bronchus pressure). A cough history of months or years, normal to high body scores, and normal heart rates with sinus arrhythmia tend to support chronic airway disease. In cases of MVD, however, the disease tends to be progressive: the body score is lower, the heart rate is higher, and there is a possibility of pathological arrhythmias. Yet, both bronchial disease and MVD can be present simultaneously, and advanced diagnostics, such as ultrasound examination, are necessary to distinguish which culprit is inciting the clinical signs.

Diagnostics: Ascertaining NT-proBNP levels may help to determine whether dyspnea is respiratory or cardiac in origin and provide information that can assist with the early detection of cardiac disease in subclinical patients, especially in high-risk breeds, such as Cavalier King Charles Spaniels, Podles, and Cocker Spaniels.



PATIENT

Rico Bodden

Radiographic findings may reveal a vertical or bulging caudal cardiac waist, hilar edema, generalized cardiomegaly, elevation of the left mainstem bronchus, and right-sided enlargement in advanced cases where pulmonary hypertension or tricuspid disease is also present.

SPECIES

Canine

BREED

Chihuahua

Echocardiographic findings allow the practitioner to assess precisely cardiac function under pathological circumstances. Moreover, they enable an evaluation of the myocardial response at the time of the exam and help practitioners continue to quantify that response over time while patients are undergoing therapy.

SEX

Neutered Male

Treatment: The following treatment options are based on the ACVIM consensus statement regarding MVD.

AGE

12 Years

Stage A: There is a high risk of cardiac disease, but as there are no clinical signs, no specific therapy—medical or dietary—is indicated. A radiograph and an echocardiogram should be conducted in one year or earlier if the patient is a large-breed dog as MVD may progress faster.

WEIGHT

10.30 Pounds

Stage B: Heart disease is present.

INTERPRETED BY

Eric Lindquist, DMV
DABVP, Cert. IVUSS

B1: There is a murmur, but no chamber enlargement. Treatment is the same as for stage A.

IMAGING PERFORMED BY

Dr. Kim

B2: There is a murmur with left atrial and left ventricular enlargement, but the patient is asymptomatic. Start angiotensin-converting enzyme (ACE) inhibitors (enalapril at 0.5 mg/kg PO Q12-24hr or benazepril 0.25-0.5 mg/kg PO Q24hr). Consider beta blockers and mild sodium restriction.

HOSPITAL NAME

Ridgefield Park AH

Stage C: There are past or current clinical signs of heart failure.

REFERRING VET

Dr. Kim

Acute CHF:

- Lasix 2 mg/kg IV or IM hourly to a total dose of 8 mg/kg until the respiratory rate has normalized. Alternatively, for cases of life-threatening pulmonary edema, administer as a CRI (1mg/kg/hour).
- Oxygen supplementation.
- Continue with the ACE inhibitor and add pimobendan at 0.25-0.3 mg/kg PO BID.

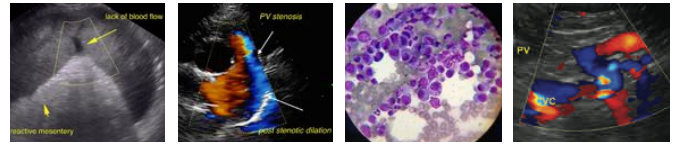
INVOICE

91425

DATE

8/23/21

Chronic therapy:



PATIENT

Rico Bodden

- Lasix at 2 mg/kg PO BID and increase incrementally as needed.
- Continue with the ACE inhibitor.
- Pimobendan at 0.25-0.3 mg/kg PO BID.
- Consider adding spironolactone at 0.25-2 mg/kg PO BID to control congestion.
- A sodium-restricted diet is recommended, although some dogs will not eat it.
- Consider administering omega-3 fatty acids, digoxin, theophylline, and cough suppressants.
- If the dog is not already on beta blockers, then do not commence.

SPECIES

Canine

BREED

Chihuahua

Stage D: This is the end-stage of the disease. Continue with the standard therapy of diuretics, ACE inhibitors, and pimobendan, and consider the following:

SEX

Neutered Male

- Abdominocentesis when applicable to decrease discomfort if the patient is undergoing respiratory distress.
- Anti-anxiety medications for sedative purposes.
- Sodium nitroprusside and dobutamine (in a critical care facility).
- Nitroglycerin.

AGE

12 Years

WEIGHT

10.30 Pounds

We recommend monitoring serum urea, creatinine, electrolytes, urine specific gravity, and possibly blood pressure for 5-7 days after therapy has commenced. A repeat ECG is warranted if an arrhythmia was present during the original assessment.

INTERPRETED BY

Eric Lindquist, DMV
DABVP, Cert. IVUSS

References:

Atkins C, Bonagura J, Ettinger S, et al. Guidelines for the diagnosis and treatment of canine chronic valvular heart disease. *J Vet Int Med* 2009; 23(6):1142-50.

IMAGING PERFORMED BY

Dr. Kim

Borgarelli M, Buchanan J. Historical review, epidemiology and natural history of degenerative mitral valve disease. *J Vet Cardiol* 2012;14:93-101.

HOSPITAL NAME

Ridgefield Park AH

Chetboul V, Tissier R. Echocardiographic assessment of canine degenerative mitral valve disease. *J Vet Cardiol* 2012;14:127-48.

REFERRING VET

Dr. Kim

Fox P. Pathology of myxomatous mitral valve disease in the dog. *J Vet Cardiol* 2012;14:103-26.

INVOICE

91425

DATE

8/23/21