



PATIENT

Parker Wittwer

SPECIES

Canine

BREED

Min Pin

SEX

Neutered Male

AGE

3 Years

WEIGHT

12.5 Pounds

INTERPRETED BY

Eric Lindquist, DMV
DABVP, Cert. IVUSS

IMAGING PERFORMED BY

Jenn

HOSPITAL NAME

Rockaway AH

REFERRING VET

Dr. Maniar

INVOICE

12695

DATE

8/23/21

PRESENTING CLINICAL SIGNS

History: vomiting, blood in urine

Abnormal PE/Chem/CBC/UA Results:

ULTRASONOGRAPHIC EXAMINATION OF THE ABDOMEN

Urinary System

The **urinary bladder**, trigone, and pelvic urethra presented normal thicknesses and normal tone. The ureters were not visible which is normal. No uroliths or sediment were visualized and anechoic urine was present. No evidence of inflammatory or neoplastic changes were noted. Ureteral papillae were normal.

The **kidneys** revealed normal size and structure, corticomedullary definition and ratio for this age. The cortices presented largely uniform texture with normal echogenic relationship to liver and spleen. Medullary structure differed distinctly from the cortex and no evidence of pelvic dilation was present. The capsules were acceptably uniform without significant irregularities. The right kidney measured 4.6 cm. The left kidney measured 4.49 cm.

Adrenal Glands

Both **adrenal glands** were visualized and recognized as having normal shape, size, position and echogenicity for this breed. The phrenic vasculature, glandular echogenicity and detail were unremarkable. Capsule, cortex, and medullary definition were normal for this age patient. The right adrenal gland measured 1.8 cm x 0.85 cm at the caudal pole and 0.59 cm at the cranial pole. The left adrenal gland measured 1.94 cm x 0.56 cm at the caudal pole and 0.6 cm at the cranial pole.

Spleen

The **spleen** presented a smooth homogeneous parenchyma hyperechoic to liver and renal cortical parenchyma. The capsule was smooth without noticeable expansion or deviation from within the spleen or adjacent pathology. The splenic vasculature demonstrated normal volume without signs of congestion or thrombosis. No sonographic evidence of acute or chronic inflammatory, neoplastic, or infarctual changes were noted.

Liver

The **liver** revealed minor coarse architecture and uniform parenchyma. The gallbladder and common bile duct were unremarkable. History of inflammatory hepatopathy likely yet no evidence of active disease.

Gastrointestinal

The **stomach** revealed minor shadowing material in the pyloric outflow, possible kibble or similar. The small intestine and colon were unremarkable.

Pancreas

The base and limbs of the **pancreas** were observed to be largely isoechoic to surrounding omental fat. Pancreatic duct and capsular contour were acceptably normal and parenchyma respected normal curvilinear patterns. No overt evidence of active inflammatory or neoplastic disease was noted.



PATIENT

Parker Wittwer

ULTRASONOGRAPHIC FINDINGS

SPECIES

Canine

- Minor retention of ingesta or possible shadowing gastric material
- Liver, minor coarse architecture

BREED

Min Pin

INTERPRETATION OF THE FINDINGS & FURTHER RECOMMENDATIONS

Urinalysis assessment for evidence of UTI or coagulopathy warranted given the urinary tract is unremarkable. The material in the pylorus may represent medications, only measured 1.0 cm, non-obstructive. No evidence of significant disease. Supportive care should prove effective.

SEX

Neutered Male

AGE

3 Years

WEIGHT

12.5 Pounds

INTERPRETED BY

Eric Lindquist, DMV
DABVP, Cert. IVUSS

IMAGING PERFORMED BY

Jenn

HOSPITAL NAME

Rockaway AH

REFERRING VET

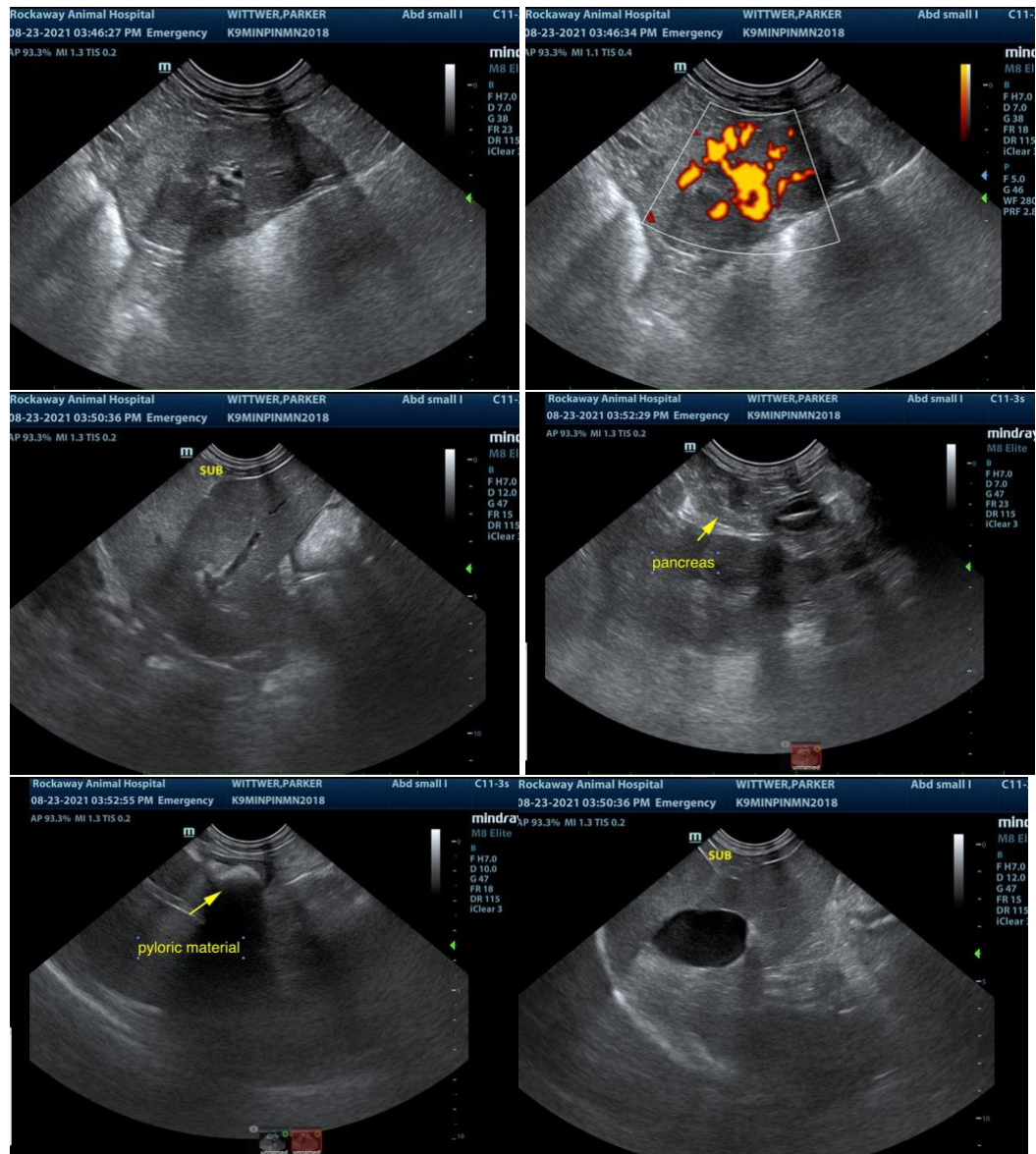
Dr. Maniar

INVOICE

12695

DATE

8/23/21





PATIENT

Parker Wittwer

SPECIES

Canine

BREED

Min Pin

SEX

Neutered Male

AGE

3 Years

WEIGHT

12.5 Pounds

INTERPRETED BY

Eric Lindquist, DMV
DABVP, Cert. IVUSS

IMAGING PERFORMED BY

Jenn

HOSPITAL NAME

Rockaway AH

REFERRING VET

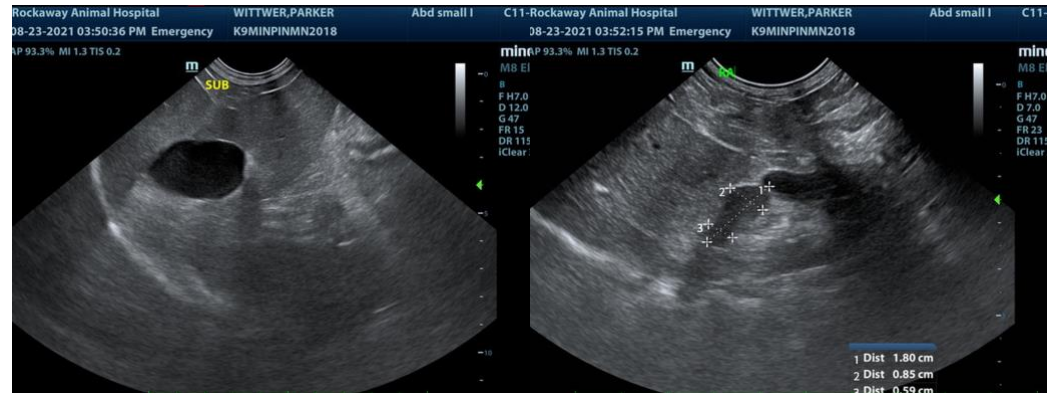
Dr. Maniar

INVOICE

12695

DATE

8/23/21



The information and recommendations provided are based on the images presented by the referring veterinarian. No evaluation can be communicated regarding pathology that was not visible in the image/video clips provided.

Thank you for this referral. If the clinical or image interpretation does not parallel your findings or if I can be of any further assistance please contact me.

Eric Lindquist, DMV, DABVP, Cert. IVUSS, CEO of SonoPath.com
info@SonoPath.com