

**DATE**

8/23/21

**PRESENTING CLINICAL SIGNS**

History: hugging walls, disoriented, neurologic- then fine.

Current Medications:

Lab Results: ALT [abnormal? Not provided by the veterinarian].

Radiographs: Not provided by the veterinarian.

Date of Previous IntraPet Ultrasound: No previous IntraPet scans.

**PATIENT**

Layla Howard

**SPECIES**

Canine

**ULTRASONOGRAPHIC EXAMINATION OF THE ABDOMEN****Urinary System**

The **urinary bladder**, trigone, and pelvic urethra presented normal thicknesses and normal tone. The ureters were not visible which is normal. No uroliths or sediment were visualized and anechoic urine was present. No evidence of inflammatory or neoplastic changes was noted. Ureteral papillae were normal.

**BREED**

German Shepherd Mix

The **kidneys** were bilaterally swollen. The left kidney measured 6.38 cm. The right kidney measured 6.05 cm.

**SEX**

Spayed Female

**Adrenal Glands**

Both **adrenal glands** were visualized and recognized as having normal shape, size, position and echogenicity for this breed. The phrenic vasculature, glandular echogenicity and detail were unremarkable. Capsule, cortex, and medullary definition were normal for this age patient. The left adrenal gland measured 2.54 x 0.45 cm at the caudal pole and 0.5 cm at the cranial pole. The right adrenal gland measured 2.09 x 0.42 cm at the cranial pole and 0.52 cm at the caudal pole.

**AGE**

12/8/20

**WEIGHT**

27.4 lbs

**Spleen**

The **spleen** presented a smooth homogeneous parenchyma hyperechoic to liver and renal cortical parenchyma. The capsule was smooth without noticeable expansion or deviation from within the spleen or adjacent pathology. The splenic vasculature demonstrated normal volume without signs of congestion or thrombosis. No sonographic evidence of acute or chronic inflammatory, neoplastic, or infarctual changes was noted.

**INTERPRETED BY**Eric Lindquist, DMV  
DABVP, Cert. IVUSS**Liver**

The **liver** was subnormal in size and uniform. Abnormal tortuous vessel was noted in the extrahepatic space. This is strongly suggestive for portosystemic shunting especially given the subnormal liver size and swollen kidneys. However, the exact type of shunt cannot be ascertained. The gallbladder and common bile duct were unremarkable. The liver measured 2.34 cm in width.

**HOSPITAL NAME**

Gambrills VC

**REFERRING VET**

Dr. Orenstein

**Gastrointestinal**

Examination of the **gastrointestinal tract** revealed a stomach and intestine free of stasis, of normal wall thickness, acceptable curvilinear mural detail, and peristaltic activity. Small and large intestine demonstrated normal luminal chyme and stool consistency respectively. No obstructive or overt infiltrative disease was noted. No associated abnormal lymphatic activity was noted.

**INVOICE**

91429

**Pancreas**

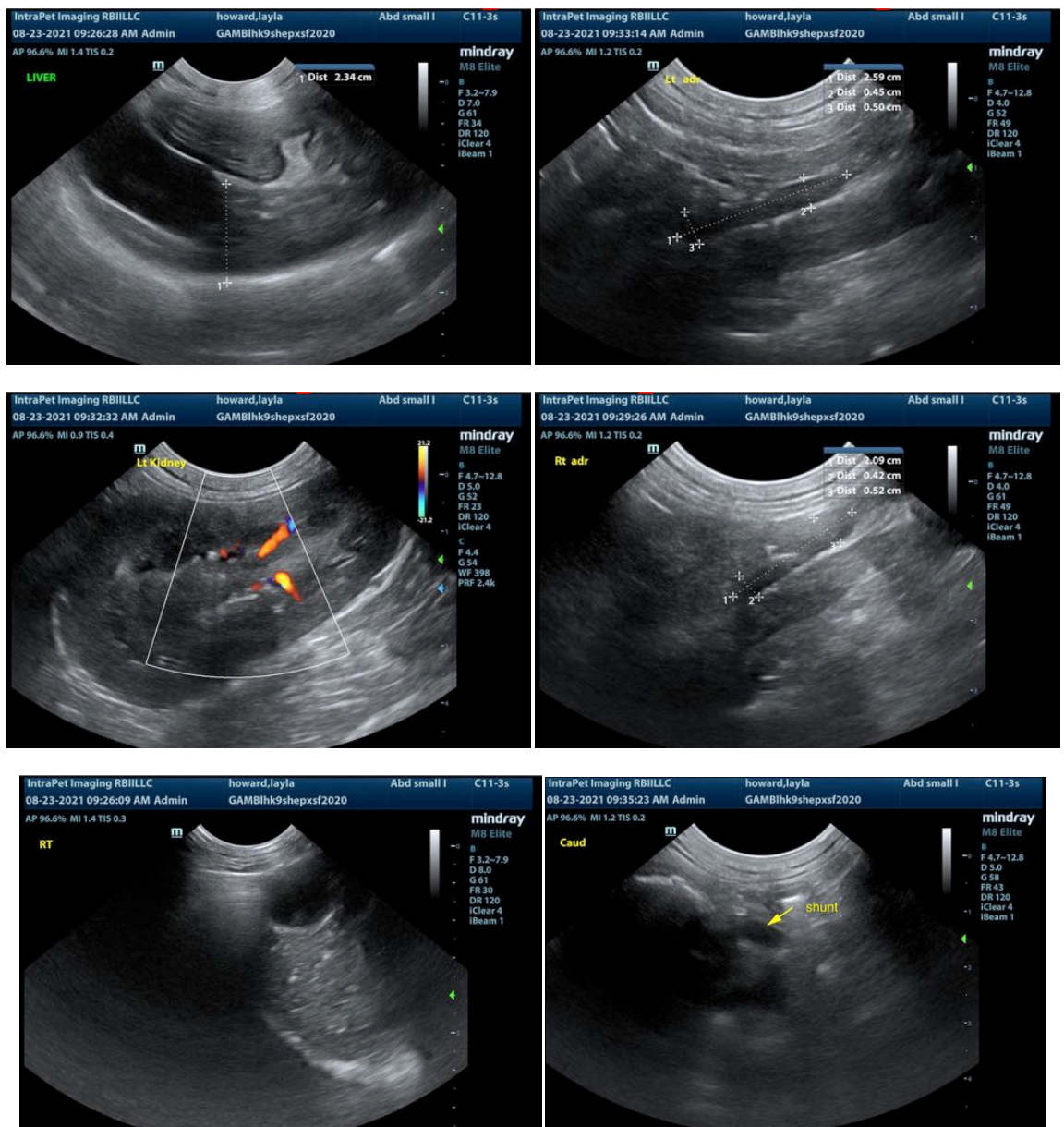
The base and limbs of the **pancreas** were observed to be largely isoechoic to surrounding omental fat. Pancreatic duct and capsular contour were acceptably normal and parenchyma respected normal curvilinear patterns. No overt evidence of active inflammatory or neoplastic disease was noted.

## ULTRASONOGRAPHIC FINDINGS

Microhepatica.  
Swollen kidneys.

## INTERPRETATION OF THE FINDINGS & FURTHER RECOMMENDATIONS

CT with contrast is warranted as well as bile acid profile. Extrahepatic portosystemic shunt should be further defined with CT with contrast.



The information and recommendations provided are based on the images presented by the referring veterinarian. No evaluation can be communicated regarding pathology that was not visible in the

**image/video clips provided.**

Thank you for this referral. If the clinical or image interpretation does not parallel your findings or if I can be of any further assistance please contact me.

**Eric Lindquist**, DMV, DABVP, Cert. IVUSS, CEO of SonoPath.com  
Eric.Lindquist@SonoPath.com