

**DATE PRESENTING CLINICAL SIGNS**

8/23/21 History: Presents for ADR, lethargy, intermittent diarrhea.

PATIENT Current Medications: No current medications.

Ben Templeton

Lab Results: ALP 327, Hct- 28.5%- non regenerative anemia, stress leukogram, Globulin 4.7, Glucose 151
Radiographs: large soft tissue opacity seen displacing intestines on abdominal rads.**SPECIES** Date of Previous IntraPet Ultrasound: No previous IntraPet scans.

Canine

Sedation: Not needed.

Stat Report: stat report requested/Approved.

BREED**ULTRASONOGRAPHIC EXAMINATION OF THE ABDOMEN**

Labrador Retriever

Urinary System**SEX**

Neutered Male

The **urinary bladder**, trigone, and pelvic urethra presented normal thicknesses and normal tone. The ureters were not visible which is normal. No uroliths or sediment were visualized and anechoic urine was present. No evidence of inflammatory or neoplastic changes were noted. Ureteral papillae were normal. The residual prostate measured 1.08 cm.**AGE**

2/7/2020

The **kidneys** revealed normal size and structure, corticomedullary definition and ratio for this age. The cortices presented largely uniform texture with normal echogenic relationship to liver and spleen. Medullary structure differed distinctly from the cortex and no evidence of pelvic dilation was present. The capsules were acceptably uniform without significant irregularities. The right kidney measured 7.2 cm. The left kidney measured 7.89 cm.**WEIGHT**

90.1 Pounds

Adrenal Glands**INTERPRETED BY**Eric Lindquist, DMV
DABVP, Cert. IVUSSBoth **adrenal glands** were visualized and recognized as having normal shape, size, position and echogenicity for this breed. The phrenic vasculature, glandular echogenicity and detail were unremarkable. Capsule, cortex, and medullary definition were normal for this age patient. The right adrenal gland measured 1.97 cm x 0.77 cm at the caudal pole and 1.3 cm at the cranial pole.**HOSPITAL NAME**

Eastern AH

SpleenThe **spleen** revealed an expansive mixed hypoechoic moderately complex and peripherally inflamed mass, measuring 9.2 cm with generalized irregular contour to the remainder of the spleen. Regional inflammation extending from the spleen to the region of the pancreas, areas of necrosis and infarcts likely.**REFERRING VET**

Dr. Haviland

LiverThe **liver** revealed multiple mixed hypo- and hyperechoic nodules, measuring up to 1.92 cm. Mild disruption of architecture was noted. The liver was otherwise unremarkable. The gallbladder and common bile duct were unremarkable.**INVOICE**

12689

GastrointestinalExamination of the **gastrointestinal tract** revealed a stomach and intestine free of stasis, of normal wall thickness, acceptable curvilinear mural detail, and peristaltic activity. Small and large intestine demonstrated normal luminal chyme and stool consistency respectively. No obstructive or overt infiltrative disease was noted. No associated abnormal lymphatic activity was noted.**Pancreas**

The base and limbs of the **pancreas** were observed to be largely isoechoic to surrounding omental fat. Pancreatic duct and capsular contour were acceptably normal and parenchyma respected normal curvilinear patterns. No overt evidence of active inflammatory or neoplastic disease was noted.

Free Abdomen

A trace amount of free fluid noted in the caudal **abdomen**.

Heart

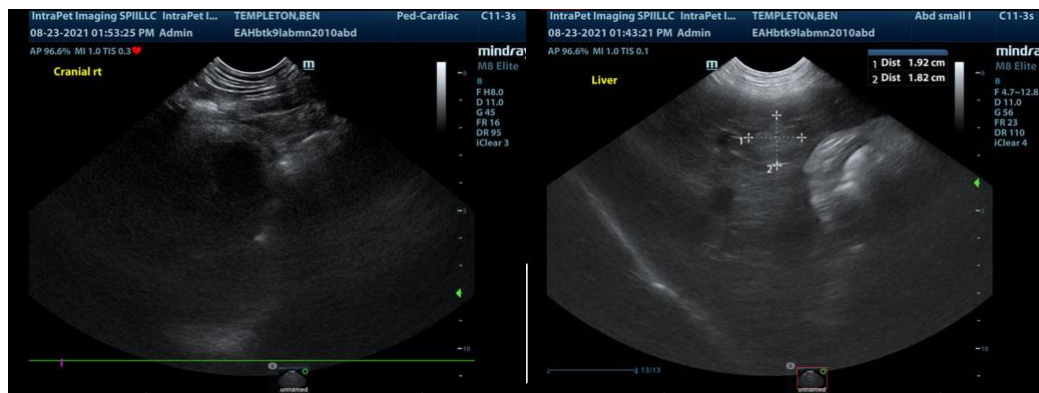The **right auricle** and pericardium were unremarkable in this patient.

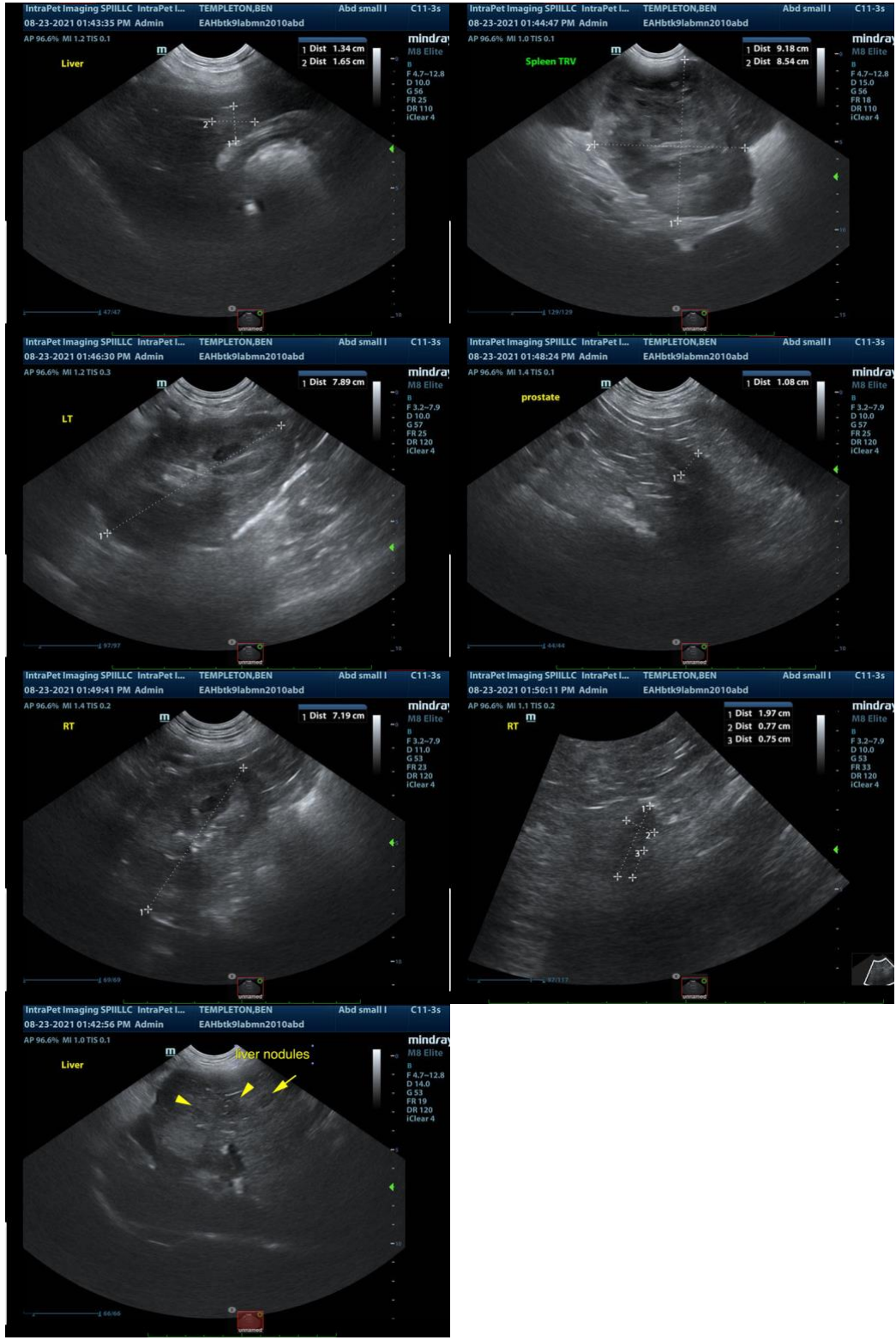
ULTRASONOGRAPHIC FINDINGS

- Splenic masses and nodular changes with regional free fluid
- Undefined hepatic nodules

INTERPRETATION OF THE FINDINGS & FURTHER RECOMMENDATIONS

Exploratory surgery would be recommended in this patient with expectations of inspection of the liver directly for metastatic changes, however, 70% of dogs over 7 years old have benign nodules in the liver and these nodules are not particularly disruptive and may represent nodular hyperplasia, however, metastatic disease of course is entirely possible. Sarcoma suspected. Round cell neoplasia or hemangiosarcoma can present in this fashion. Guarded to poor prognosis depending upon surgical outcome and histopathology. 3 view chest radiographs warranted prior to surgery.





The information and recommendations provided are based on the images presented by the referring veterinarian. No evaluation can be communicated regarding pathology that was not visible in the image/video clips provided.

Thank you for this referral. If the clinical or image interpretation does not parallel your findings or if I can be of any further assistance please contact me.

Eric Lindquist, DMV, DABVP, Cert. IVUSS, CEO of SonoPath.com
info@SonoPath.com