



PATIENT

Wilbur Richardson

SPECIES

Canine

BREED

Labrador Retriever

SEX

Neutered male

AGE

12 years

WEIGHT

85 lbs

INTERPRETED BY

Eric Lindquist, DMV
DABVP, Cert. IVUSS

IMAGING PERFORMED BY

Jill Rumachik

HOSPITAL NAME

Clarity Imaging

REFERRING VET

Dr. CC Sheldon

INVOICE

46711

DATE

8/22/23

PRESENTING CLINICAL SIGNS

History: Pneumonia diagnosis in spring 2023 -- lingering cough since then. No murmur heard on exam. ProBNP slightly elevated at 1080 (range: 0-900 pmol/L). Some exercise intolerance and excessive panting noted at home.

ULTRASONOGRAPHIC EXAMINATION OF THE HEART

The echocardiogram in this patient demonstrated normal **left atrial** size based on 3 separate methods of LA evaluation. The cranial and caudal **mitral** valve leaflets presented normal linear structure, extension in systole, and union in diastole with normal kinesis. The **left ventricle** presented thicknesses with linear contour and was not dilated nor restricted. The **myocardium** presented normal echogenicity without subjective evidence of significant fibrotic or ischemic disease. **Contractility** of the ventricular walls was adequate and in normal range for this patient evidenced by the fractional shortening measurement and subjective evaluation of the different regions of the myocardium. The **left ventricular outflow** tract demonstrated normal laminar flow and subjective structural integrity. The **right atrium** and auricle revealed normal size, structure and content. No evidence of masses was noted. **Tricuspid** valvular assessment demonstrated adequate linear morphology and kinesis. The **right ventricle** was of normal size (1/3 diameter of LV), chordae structure, myocardial echogenicity and thickness. **Pulmonary outflow** tract assessment revealed normal valve structure, laminar flow, and diameter (approx. 1:1 pa/ao ratio). No visible **pericardial** or free pleura fluid was noted. The cranial **mediastinum and pericardial and extra-cardiac regions** were free of masses in the visible window.

CANINE CARDIAC PARAMETERS	MR VMAX (m/s)	TR VMAX (m/s)	LA/AO (Boon method)	LA/AO (Heart Base;)	FS (%)	EF (%)	EPSS (cm)
NORMAL PARAMETER	4.5-5.5	<2.7	1.3	Up to 1.6	28-40	40-100	<0.6
PATIENT			1.15	1.3	40		0.1
CANINE CARDIAC PARAMETERS	HR (BPM)	AV VMAX (m/s)	PV MAX (m/s)	BODY WEIGHT (kg)	LA 2D short axis Base view (cm)	LVIDd Avg; 2D and m- mode short axis (cm)	LVIDs Avg; 2D and m- mode short axis (cm)
NORMAL PARAMETER	50-100	0.7-1.7	0.7-1.6	BELOW	BELOW	BELOW	BELOW
PATIENT		1.5	0.9	85 lbs	4.5 max	3.3	

ULTRASONOGRAPHIC FINDINGS

Normal echocardiogram.

No evidence of cardiogenic disease as the cause of cough in this patient.



INTERPRETATION OF THE FINDINGS & FURTHER RECOMMENDATIONS

Chest radiographs and bronchoalveolar lavage would likely be valuable in this patient given the patient's history.

PATIENT

Wilbur Richardson

SPECIES

Canine

BREED

Labrador Retriever

SEX

Neutered male

AGE

12 years

WEIGHT

85 lbs

INTERPRETED BY

Eric Lindquist, DMV
DABVP, Cert. IVUSS

IMAGING PERFORMED BY

Jill Rumachik

HOSPITAL NAME

Clarity Imaging

REFERRING VET

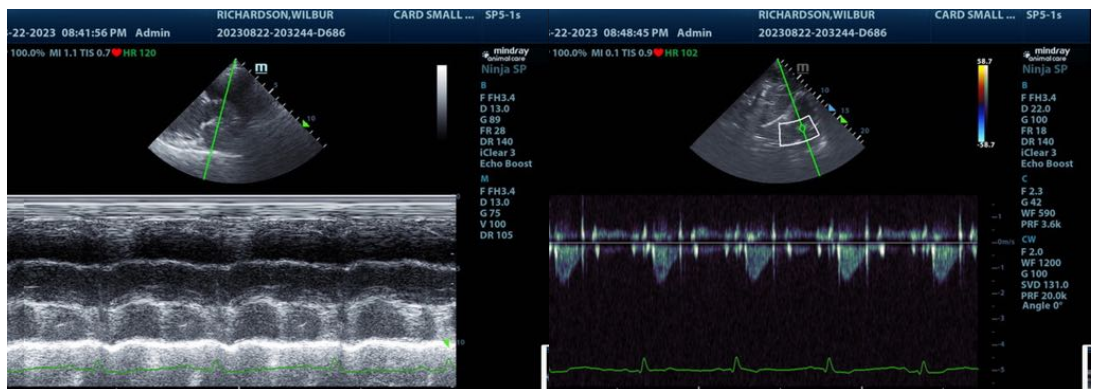
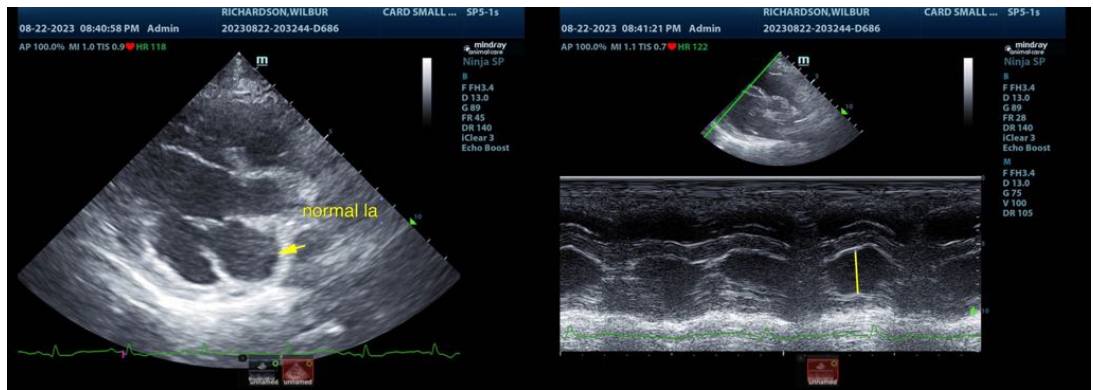
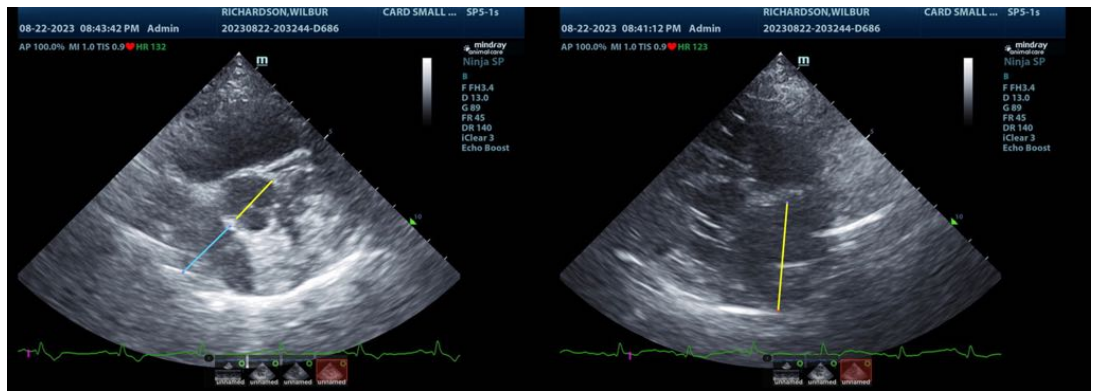
Dr. CC Sheldon

INVOICE

46711

DATE

8/22/23





PATIENT

Wilbur Richardson

SPECIES

Canine

BREED

Labrador Retriever

SEX

Neutered male

AGE

12 years

WEIGHT

85 lbs

INTERPRETED BY

Eric Lindquist, DMV
DABVP, Cert. IVUSS

IMAGING PERFORMED BY

Jill Rumachik

HOSPITAL NAME

Clarity Imaging

REFERRING VET

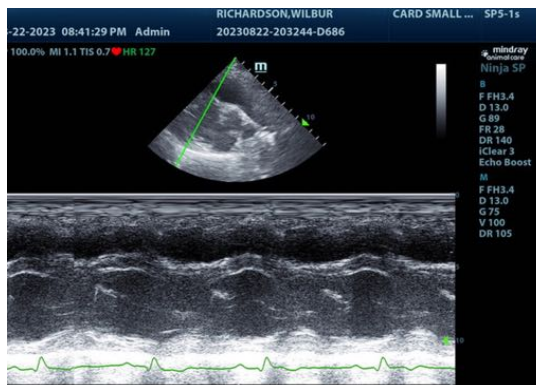
Dr. CC Sheldon

INVOICE

46711

DATE

8/22/23



The information and recommendations provided are based on the images presented by the referring veterinarian/sonographer. No evaluation can be communicated regarding pathology that was not visible in the image/video clips provided.

Thank you for this referral. If the clinical or image interpretation does not parallel your findings or if I can be of any further assistance please contact me.

Eric Lindquist, DMV, DABVP, Cert. IVUSS, CEO of SonoPath.com
info@SonoPath.com