



**PATIENT**

Blue Alberrrts

**SPECIES**

Lizard

**BREED**

Savannah Monitor

**SEX**

Female

**AGE**

1 year

**WEIGHT**

690 g

**INTERPRETED BY**

Eric Lindquist, DMV  
DABVP, Cert. IVUSS

**IMAGING PERFORMED BY**

Dallas Ramberg

**HOSPITAL NAME**

Lone Mountain AH

**REFERRING VET**

Dr. Moore

**INVOICE**

46713

**DATE**

8/22/23

**PRESENTING CLINICAL SIGNS**

History: presented as a transfer from ER for lethargy and being unresponsive. free fluid noted in coelom and around the heart. P obtunded.

Abnormal PE/Chem/CBC/UA Results: full CBC/chem pending, HCT was 26% - mildly anemic.

**ULTRASONOGRAPHIC EXAMINATION OF THE ABDOMEN**

The abdomen in this patient revealed a mild amount of ascites. The liver had uniform parenchyma with no evidence of pathology. The gallbladder was unremarkable. The gastrointestinal tract revealed normal content. Other visceral organs were unremarkable. There was no evidence of masses however, free fluid was persistent.

The heart was visualized with normal volume and spontaneous contrast with slight free fluid around the heart. Contractility appeared adequate. HR was normal at 35-40 bpm.

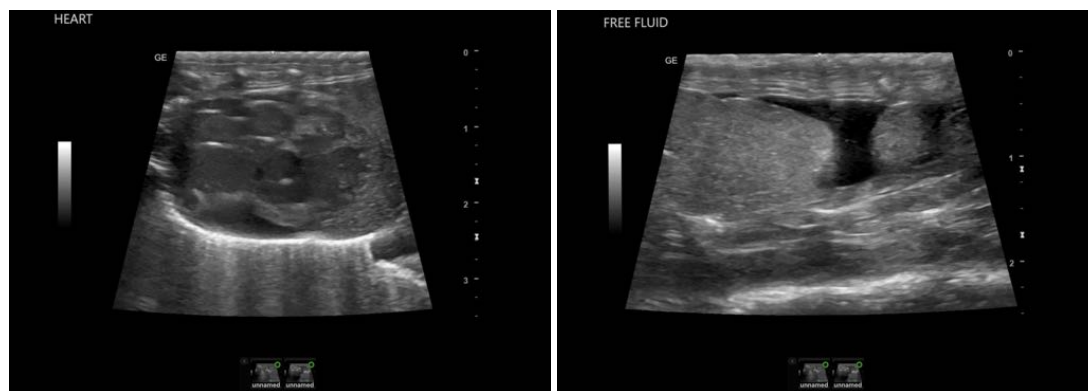**ULTRASONOGRAPHIC FINDINGS**

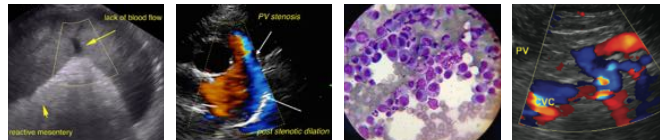
Undefined free fluid, possible toxin exposure.

Heart normal volume with spontaneous contrast and normal contractility, no evidence of primary pathology.

**INTERPRETATION OF THE FINDINGS & FURTHER RECOMMENDATIONS**

The cause of free fluid was unclear. I suspect toxin or infectious exposure. Abdominocentesis and cytospin is recommended.





**PATIENT**

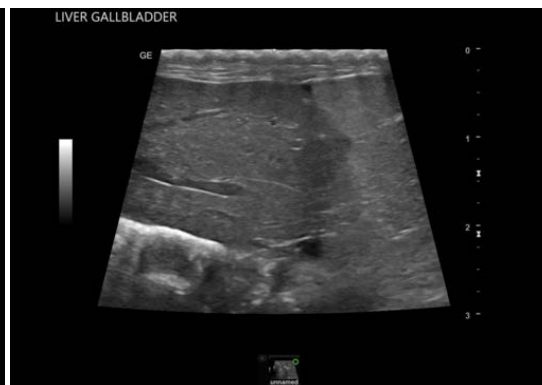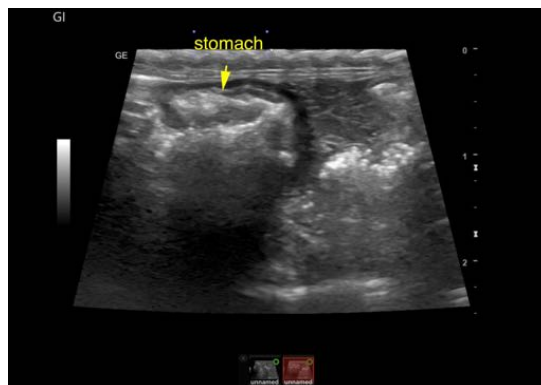Blue Alberrrts

**SPECIES**

Lizard

**BREED**

Savannah Monitor



**SEX**

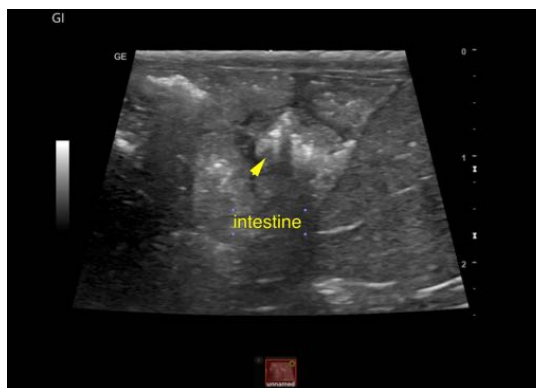Female

**AGE**

1 year

**WEIGHT**

690 g



**INTERPRETED BY**

Eric Lindquist, DMV  
DABVP, Cert. IVUSS

**IMAGING PERFORMED BY**

Dallas Ramberg

**HOSPITAL NAME**

Lone Mountain AH

**REFERRING VET**

Dr. Moore

**INVOICE**

46713

**DATE**

8/22/23

The information and recommendations provided are based on the images presented by the referring veterinarian/sonographer. No evaluation can be communicated regarding pathology that was not visible in the image/video clips provided.

Thank you for this referral. If the clinical or image interpretation does not parallel your findings or if I can be of any further assistance please contact me.

**Eric Lindquist**, DMV, DABVP, Cert. IVUSS, CEO of SonoPath.com  
info@SonoPath.com