



**PATIENT**

Sunny Runyan

**SPECIES**

Feline

**BREED**

Feline

**SEX**

Neutered Male

**AGE**

14 Years

**WEIGHT**

9.09 Pounds

**INTERPRETED BY**

Eric Lindquist, DMV  
DABVP, Cert. IVUSS

**IMAGING PERFORMED BY**

Megan Schneck

**HOSPITAL NAME**

Willamette VH

**REFERRING VET**

Gary Jimmerson

**INVOICE**

11439ag

**DATE**

8/21/22

**PRESENTING CLINICAL SIGNS**

History: Presented 8/20 for 1d vomiting with small amount of blood, 1d anorexia and lethargy. Tachypneic. Hx pica (plastic, seen carrying a Qtip around yesterday)

Abnormal PE/Chem/CBC/UA Results: intermittent gallop, grade 4/6 sternal systolic murmur - r/o hyperT4 vs congenital heart disease interstitial pulmonary pattern in caudal lung fields on VD - r/o CHF vs pneumonia vs neoplasia vs other bilirubin crystalluria, elevated ALT - r/o triaditis vs hepatitis vs neoplasia vs other elevated SDMA - r/o early renal disease vs systemic hypertension vs cardiorenal vs toxin vs other.

**ULTRASONOGRAPHIC EXAMINATION OF THE ABDOMEN**

**Urinary System**

The **urinary bladder**, trigone, and pelvic urethra presented normal thicknesses and normal tone. The ureters were not visible which is normal. No uroliths or sediment were visualized and anechoic urine was present. No evidence of inflammatory or neoplastic changes were noted. Ureteral papillae were normal.

The **kidneys** revealed largely normal size and structure, corticomedullary definition and ratio (cortex 1/3 of medulla) were essentially maintained with some mild age-related loss of curvilinear patterns regarding the capsule and C/M junction. The cortices presented largely uniform texture with some increased echogenicity expected for his age patient. Medullary structure differed distinctly from that of the cortex and no evidence of pelvic dilation was present. The left kidney measured 3.79 cm in length. The right kidney measured 3.5 cm in length.

**Adrenal Glands**

Both **adrenal glands** were visualized and recognized as having normal shape, size, position and echogenicity for this breed. The phrenic vasculature, glandular echogenicity and detail were unremarkable. Capsule, cortex, and medullary definition were normal for this age patient. The right adrenal gland measured 0.17 cm. The left adrenal gland measured 0.29 cm.

**Spleen**

The **spleen** presented a smooth homogeneous parenchyma hyperechoic to liver and renal cortical parenchyma. The capsule was smooth without noticeable expansion or deviation from within the spleen or adjacent pathology. The splenic vasculature demonstrated normal volume without signs of congestion or thrombosis. No sonographic evidence of acute or chronic inflammatory, neoplastic, or infarctual changes were noted.

**Liver**

The **liver** images from right and left intercostal as well as subcostal views revealed subjectively normal liver size, contour, and structure. Some age-related parenchymal remodeling was noted but likely not clinically significant at this time. Vascular and biliary tracts were of normal volume and no evidence of congestion was noted. The gallbladder presented some dependent debris with essentially normal contour. The cystic and common bile ducts were normal. No overt evidence of active inflammatory, infiltrative or regenerative pathology was noted but should be paired with current or past LE elevations regarding any clinical significance to this presentation. The hepatic lymph nodes were unremarkable.

**Gastrointestinal**



**PATIENT**

Sunny Runyan

Examination of the **gastrointestinal tract** revealed a stomach and intestine free of stasis, of normal wall thickness, acceptable curvilinear mural detail, and peristaltic activity. Small and large intestine demonstrated normal luminal chyme and stool consistency respectively. No obstructive or overt infiltrative disease was noted. An enlarged/reactive epigastric lymph node was observed measuring 0.39 cm.

**SPECIES**

Feline

**Pancreas**

The base and limbs of the **pancreas** were observed to be largely isoechoic to surrounding omental fat. Pancreatic duct and capsular contour were acceptably normal and parenchyma respected normal curvilinear patterns. No overt evidence of active inflammatory or neoplastic disease was noted.

**BREED**

Feline

**ULTRASONOGRAPHIC FINDINGS**

**SEX**

- Geriatric abdominal changes

Neutered Male

**INTERPRETATION OF THE FINDINGS & FURTHER RECOMMENDATIONS**

No evidence of significant abdominal disease was present in this study.

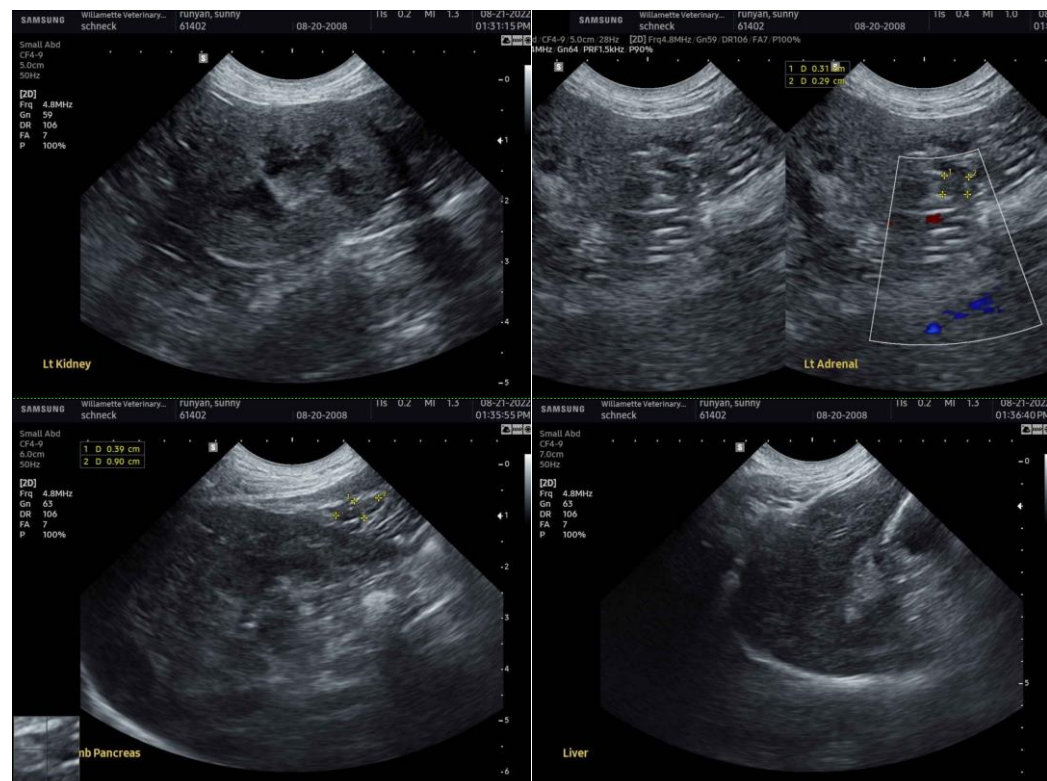
**AGE**

14 Years

A rapid view of the heart revealed volume overload in the left heart. Thoracic ultrasound and three view chest radiographs are recommended to assess thoracic pathology.

**WEIGHT**

9.09 Pounds



**INTERPRETED BY**

Eric Lindquist, DMV  
DABVP, Cert. IVUSS

**IMAGING PERFORMED BY**

Megan Schneck

**HOSPITAL NAME**

Willamette VH

**REFERRING VET**

Gary Jimmerson

**INVOICE**

11439ag

**DATE**

8/21/22



**PATIENT**

Sunny Runyan

**SPECIES**

Feline

**BREED**

Feline

**SEX**

Neutered Male

**AGE**

14 Years

**WEIGHT**

9.09 Pounds

**INTERPRETED BY**

Eric Lindquist, DMV  
DABVP, Cert. IVUSS

**IMAGING PERFORMED BY**

Megan Schneck

**HOSPITAL NAME**

Willamette VH

**REFERRING VET**

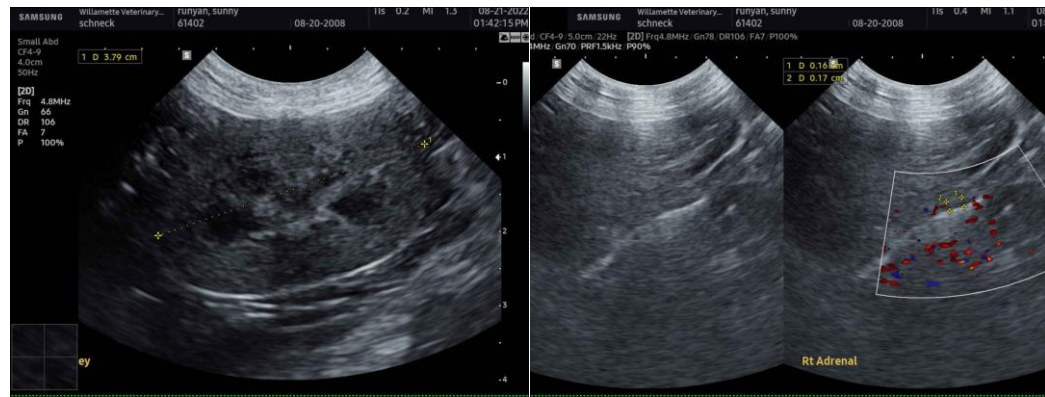
Gary Jimmerson

**INVOICE**

11439ag

**DATE**

8/21/22



The information and recommendations provided are based on the images presented by the referring veterinarian. No evaluation can be communicated regarding pathology that was not visible in the image/video clips provided.

Thank you for this referral. If the clinical or image interpretation does not parallel your findings or if I can be of any further assistance please contact me.

Eric Lindquist, DMV, DABVP, Cert. IVUSS, CEO of SonoPath.com  
info@SonoPath.com