

**DATE**

8/22/22

PRESENTING CLINICAL SIGNS

History: Attempting to hold back vomit. Had a similar episode 2 weeks ago. Tense in abdomen. Palpation triggers more writhing swallowing behavior.

PATIENT

Savanah Russell

Current Medications: Cerenia 60mg SID.

Radiographs: No FB or obstruction seen. Possible space occupying lesion in left mid abdomen.

Date of Previous IntraPet Ultrasound: 3/26/19. See attached

Sedation: Not required to complete full diagnostic ultrasound.

Stat Report: Not requested.

Imaging Performed By: Rachel Brillhart, RDMS.

SPECIES

Canine

BREED

Terrier

SEX

Spayed Female

AGE

2/15/13

WEIGHT

40.5 Pounds

INTERPRETED BY

Eric Lindquist, DMV
DABVP, Cert. IVUSS

ULTRASONOGRAPHIC EXAMINATION OF THE ABDOMEN**Urinary System**

The **urinary bladder**, trigone, and pelvic urethra presented normal thicknesses and normal tone. The ureters were not visible which is normal. No uroliths or sediment were visualized, and anechoic urine was present. No evidence of inflammatory or neoplastic changes were noted. Ureteral papillae were normal.

The **kidneys** revealed normal size and structure, corticomedullary definition and ratio for this age. The cortices presented largely uniform texture with normal echogenic relationship to liver and spleen. Medullary structure differed distinctly from the cortex and no evidence of pelvic dilation was present. The capsules were acceptably uniform without significant irregularities. The right kidney measured 4.74 cm. The left kidney measured 4.74 cm.

Adrenal Glands

Both **adrenal glands** were visualized and recognized as having normal shape, size, position and echogenicity for this breed. The phrenic vasculature, glandular echogenicity and detail were unremarkable. Capsule, cortex, and medullary definition were normal for this age patient. The right adrenal gland measured 1.94 cm x 0.64 cm at the caudal pole and 0.67 cm at the cranial pole. The left adrenal gland measured 2.53 cm x 0.72 cm at the caudal pole and 0.55 cm at the cranial pole.

Spleen

The **spleen** presented a smooth homogeneous parenchyma hyperechoic to liver and renal cortical parenchyma. The capsule was smooth without noticeable expansion or deviation from within the spleen or adjacent pathology. The splenic vasculature demonstrated normal volume without signs of congestion or thrombosis. No sonographic evidence of acute or chronic inflammatory, neoplastic, or infarctual changes were noted.

HOSPITAL NAME

Abbey AH

REFERRING VET

Dr. Kluttz

Liver

The **liver** was uniform. A minor amount of coalesced sludge was present, up to 2.0 cm. The gallbladder wall was unremarkable. No evidence of pathology otherwise.

INVOICE

16990

Gastrointestinal

Mild **gastritis** pattern was noted. The pylorus revealed a similar presentation to the prior sonogram, in fact, it's mildly improved. A minor amount of echogenic mucosal remodeling is noted. A minor amount of gastric luminal fluid was present. The small intestine was unremarkable.

Pancreas

The base and limbs of the **pancreas** were observed to be largely isoechoic to surrounding omental fat. Pancreatic duct and capsular contour were acceptably normal and parenchyma respected normal curvilinear patterns. No overt evidence of active inflammatory or neoplastic disease was noted.

ULTRASONOGRAPHIC FINDINGS

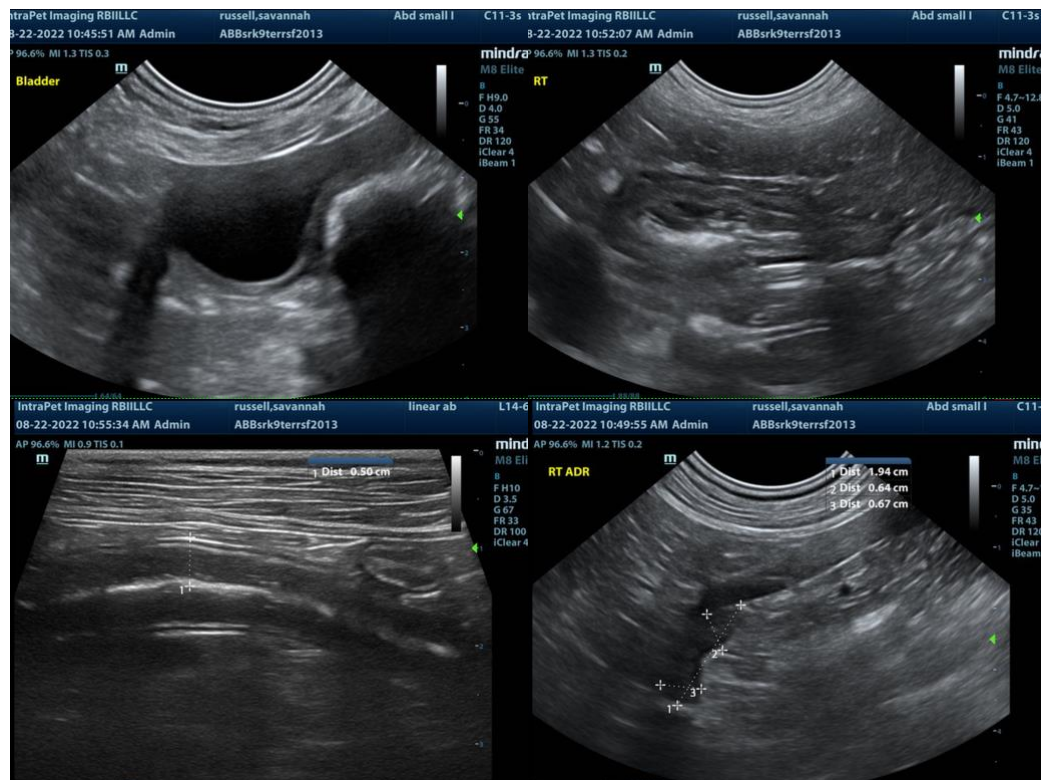
- Structurally unremarkable abdomen
- Improved pylorus with minor residual luminal fluid. Chronic gastritis is likely, given the patient history.
- Gallbladder sludge

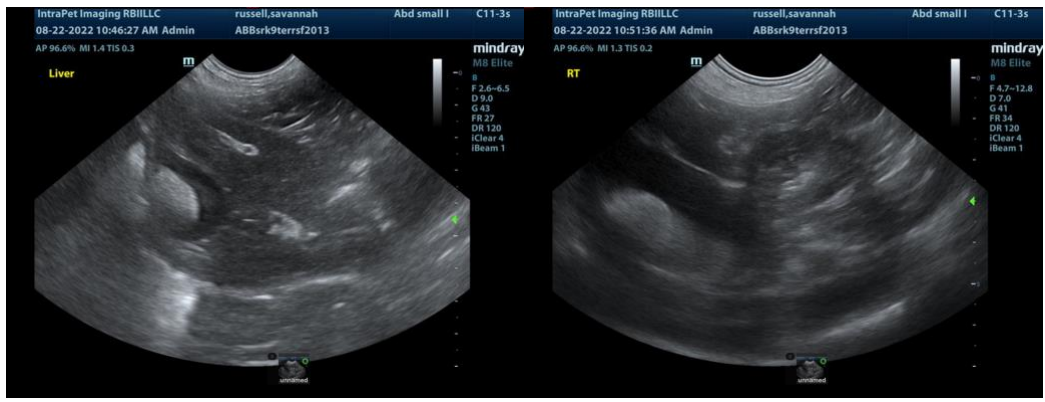
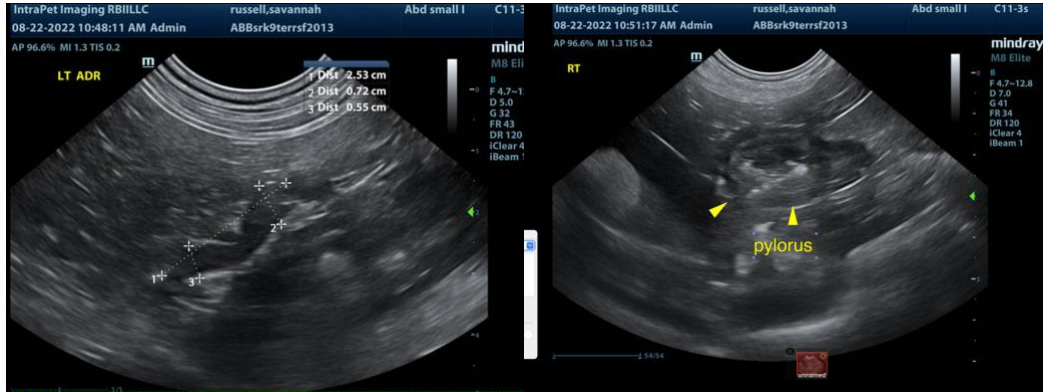
INTERPRETATION OF THE FINDINGS & FURTHER RECOMMENDATIONS

Endoscopy would be warranted. No evidence or suspicion of neoplasia or foreign bodies. A clinical trial of the following could be considered.

Helicobacter/Gastritis protocol

A clinical trial of **Zithromax (Dogs: 5-10 mg/kg p.o. q24h. May increase dosing interval to q48h after 3-5 days of treatment)**, **Metronidazole (10-20 mg/kg p.o. b.i.d.)**, **Pepcid (0.5-1 mg/kg s.i.d.)** and **Sucralfate (0.5-2 g/dog PO)** or **Omeprazole (1 mg/kg p.o. s.i.d.)** over the next 3 weeks along with a **novel-protein or hydrolyzed diet** with slurry feeding b.i.d./t.i.d. over the next 2-4 days and then increase to canned diet bid. Dry food should be avoided over the next 4 weeks. A recheck sonogram to assess GI improvement or progression would be ideal in 4 weeks.





The information and recommendations provided are based on the images presented by the referring veterinarian. No evaluation can be communicated regarding pathology that was not visible in the image/video clips provided.

Thank you for this referral. If the clinical or image interpretation does not parallel your findings or if I can be of any further assistance please contact me.

Eric Lindquist, DMV, DABVP, Cert. IVUSS, CEO of SonoPath.com
 info@SonoPath.com