

PATIENT PRESENTING CLINICAL SIGNS

Oscar Hurrle

History: Off and on history of pain in LF shoulder which is worsening and now unable to control his pain. Xrays show no bony changes(attached) but in last month the shoulder has become significantly thicker and some bony neck changes as well. Has been on Gabapentin, Amitryptiline, Deramaxx and Robaxin. Discontinue Amitryptiline today and applied Fentanyl Patch.

SPECIES

Canine

Abnormal PE/Chem/CBC/UA Results: Please see attached rads and physio assessment reports.

BREED

St. Poodle X Bernese
Mtn. Dog

LIMITED ULTRASONOGRAPHIC EXAMINATION

The left shoulder region in this patient revealed an undifferentiated multifocal. mineralizing hypoechoic mass, measuring 10+ cm with significant boney disruption. Regional soft tissue inflammation was noted. The mass appears contained by muscle fascia. However, some hypoechoic undifferentiated tissue was noted and appears to have escaped beyond the mass. A separate hypoechoic mass within the fascial planes was present. Regional spread is likely, may be of lymph node origin, depending upon the region imaged.

SEX

Neutered Male

ULTRASONOGRAPHIC FINDINGS

AGE

10 Years

- Aggressive sarcomatous type shoulder mass with boney disruption and lysis

WEIGHT

34.4 kg

INTERPRETATION OF THE FINDINGS & FURTHER RECOMMENDATIONS

Chondrosarcoma or similar is suspected. FNA is indicted. Capsular escape with regional tissue inflammation and secondary metastatic lesions are noted. CT evaluation of the shoulder and axillary region is recommended to assess the extent of the pathology. Abdominal sonogram is warranted to assess for related lesions.

INTERPRETED BY

Eric Lindquist, DMV
DABVP, Cert. IVUSS

IMAGING PERFORMED BY

Crytal Hill

HOSPITAL NAME

Hartzel AH

REFERRING VET

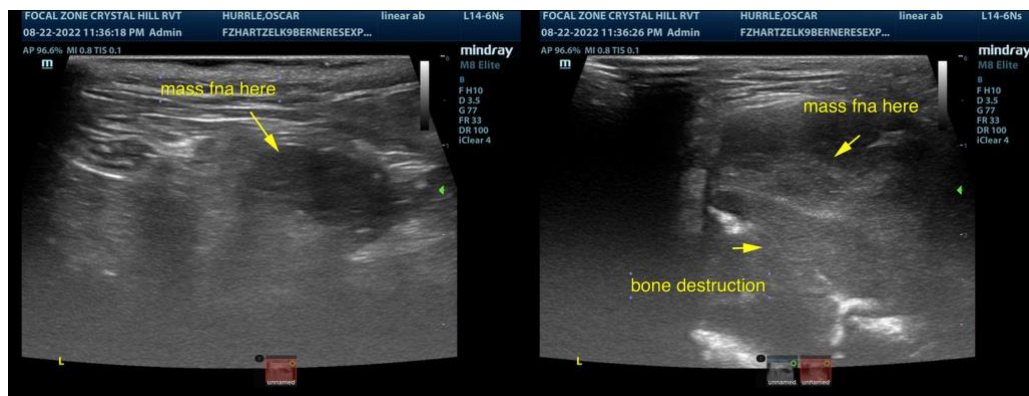
Dr. Allo

INVOICE

16986

DATE

8/22/22





PATIENT

Oscar Hurrle

SPECIES

Canine

BREED

St. Poodle X Bernese
Mtn. Dog

SEX

Neutered Male

AGE

10 Years

WEIGHT

34.4 kg

INTERPRETED BY

Eric Lindquist, DMV
DABVP, Cert. IVUSS

**IMAGING
PERFORMED BY**

Crytal Hill

HOSPITAL NAME

Hartzel AH

REFERRING VET

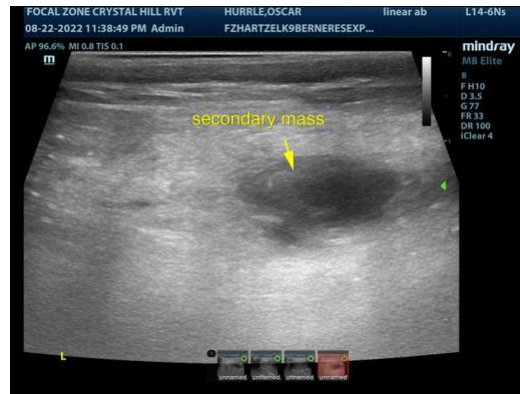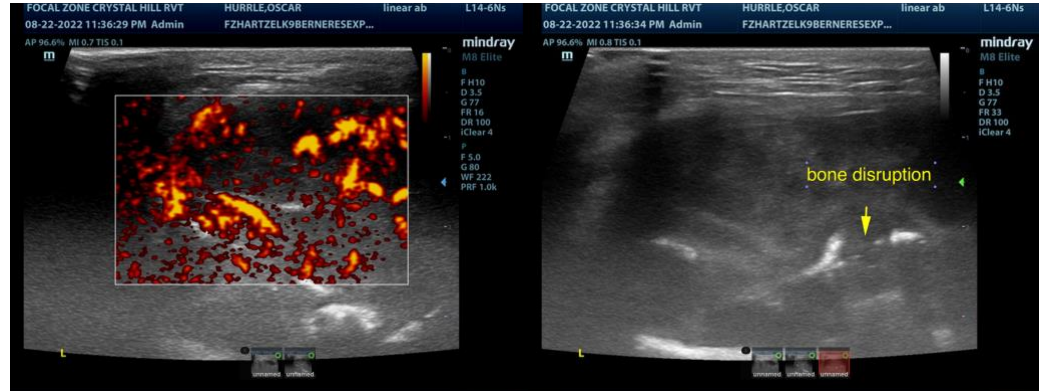
Dr. Allo

INVOICE

16986

DATE

8/22/22



The information and recommendations provided are based on the images presented by the referring veterinarian. No evaluation can be communicated regarding pathology that was not visible in the image/video clips provided.

Thank you for this referral. If the clinical or image interpretation does not parallel your findings or if I can be of any further assistance please contact me.

Eric Lindquist, DMV, DABVP, Cert. IVUSS, CEO of SonoPath.com
Eric.Lindquist@SonoPath.com