



PATIENT

Bosco Ciesla

SPECIES

Feline

BREED

Main Coon

SEX

Neutered Male

AGE

13 Years

WEIGHT

15.7 Pounds

PRESENTING CLINICAL SIGNS

History: Pre dental echo

Abnormal PE/Chem/CBC/UA Results:

ULTRASONOGRAPHIC EXAMINATION OF THE HEART

FELINE CARDIAC PARAMETERS	BODY WEIGHT (kg)	HR (BPM)	IVSd (cm)	LVIDd (cm)	LVWd (cm)	FS (%)	EF (%)
NORMAL PARAMETER	-----	150-240	0.3-0.6	1.0-2.1	0.25-0.6	35-67	80-100
PATIENT	--	NM	0.45	1.2	0.5	50	90
FELINE CARDIAC PARAMETERS	LA/AO (Boon)	LA/AO HEART BASE (Sisson)	LA 2D 4-chamber long axis AS to FW (Sisson) (cm)	LVOT VEL. (m/s)	RVOT VEL. (m/s)	IVRT (m/)	
NORMAL PARAMETER	<1.5	0.88-1.79	0.7-1.7	<1.6	<1.3	40-60	
PATIENT	1.0	1.3	--	--	.90	NM	
Adapted from June Boon, Veterinary Echocardiography, 1998							
Sisson D et al. JVIM 1991; 5: 232, Jacobs et al. Am J Vet Res 1985; 46:1705							

INTERPRETED BY

Eric Lindquist, DMV
DABVP, Cert. IVUSS

IMAGING PERFORMED BY

Travis Cerf

HOSPITAL NAME

Veterinary Center if
Hardyston

REFERRING VET

Dr. Travis Cerf

INVOICE

12667

DATE

8/22/21

Cardiac Presentation

The echocardiogram in this patient demonstrated normal **left atrial** size based on 3 separate LA measurements. The cranial and caudal **mitral** valve leaflets presented normal linear structure and kinetics. The **left ventricle** presented normal thicknesses with linear contour and was not dilated nor restricted. The **myocardium** presented normal echogenicity without subjective evidence of significant fibrotic or ischemic disease. **Contractility** of the ventricular walls was adequate and in normal range for this patient evidenced by the fractional shortening measurement and subjective evaluation of the different regions and angles of the myocardium. The **left ventricular outflow** tract demonstrated normal laminar flow and subjective structural integrity. The **right atrium** and auricle revealed normal size, structure and content. No evidence of masses was noted or chamber overload. **Tricuspid** valvular assessment demonstrated adequate linear morphology and kinetics. The **right ventricle** was of normal size (1/3 diameter of LV), chordae structure, myocardial echogenicity and thickness. **Pulmonic** tract assessment revealed normal valve structure, laminar flow, and diameter (approx.1:1 pa/ao ratio). No visible **pericardial** or free pleura fluid was noted or extra cardiac pathology in the visible planes. The cranial **mediastinum and pericardial regions** were free of masses in the visible window.

ULTRASONOGRAPHIC FINDINGS

- Normal echocardiogram

INTERPRETATION OF THE FINDINGS & FURTHER RECOMMENDATIONS

No contraindication to anesthetic procedure. No specific protocol, however, tobuterol (pre-med), propofol (induction) and isoflurane (maintenance) could be considered. No evidence of structural



PATIENT

disease.

Bosco Ciesla

SPECIES

Feline

BREED

Main Coon

SEX

Neutered Male

AGE

13 Years

WEIGHT

15.7 Pounds

INTERPRETED BY

Eric Lindquist, DMV
DABVP, Cert. IVUSS

**IMAGING
PERFORMED BY**

Travis Cerf

HOSPITAL NAME

Veterinary Center if
Hardyston

REFERRING VET

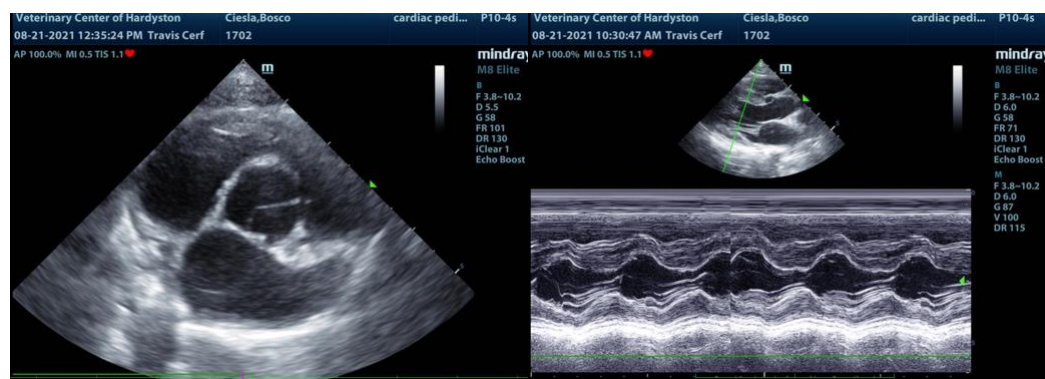
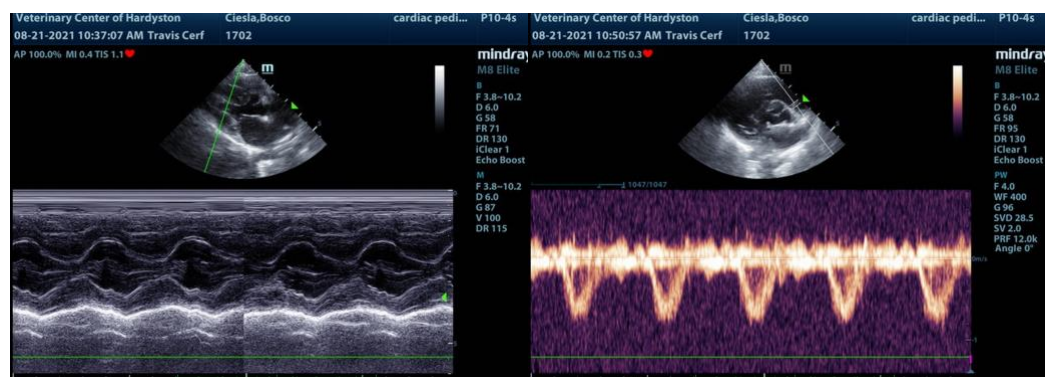
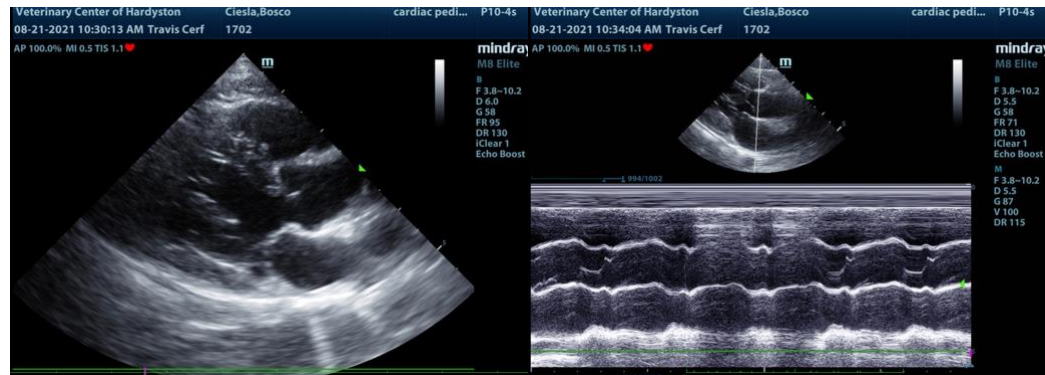
Dr. Travis Cerf

INVOICE

12667

DATE

8/22/21



The information and recommendations provided are based on the images presented by the referring veterinarian. No evaluation can be communicated regarding pathology that was not visible in the image/video clips provided.

Thank you for this referral. If the clinical or image interpretation does not parallel your findings or if I can be of any further assistance please contact me.

Eric Lindquist, DMV, DABVP, Cert. IVUSS, CEO of SonoPath.com
info@SonoPath.com