



PATIENT

Zeuss Mattu

PRESENTING CLINICAL SIGNS

History: Zeus has not been eating drinking for last 3-4 days, vomited twice this morning
Abnormal PE/Chem/CBC/UA Results: In-house lab results attached.

SPECIES

Canine

ULTRASONOGRAPHIC EXAMINATION OF THE ABDOMEN

Urinary System

BREED

Mastiff

The **urinary bladder**, trigone, and pelvic urethra presented normal thicknesses and normal tone. The ureters were not visible which is normal. No uroliths or sediment were visualized and anechoic urine was present. No evidence of inflammatory or neoplastic changes was noted. Ureteral papillae were normal.

SEX

Intact male

The **prostate** was uniformly enlarged with lobar swelling appeared to impinge upon the urethra and mildly deviate the descending colon. The prostatic tissue was hyperechoic containing focal areas of decreased echogenicity. These changes are suggestive of either chronic inflammatory episodes, benign cystic pathology or both. Underlying neoplasia cannot be completely ruled-out but is lower on the differential list. This presentation is most consistent with benign prostatic hyperplasia with possible active prostatitis. Neutering or off-label Finasteride (Propecia) (0.1-0.5 mg/kg Sid) treatment is indicated +/- FNA or prostatic wash cytology and culture. The prostate measured 4.48 cm.

AGE

7 years

WEIGHT

68.1 kg

The **kidneys** revealed normal size and structure, corticomedullary definition and ratio for this age. The cortices presented largely uniform texture with normal echogenic relationship to liver and spleen. Medullary structure differed distinctly from the cortex and no evidence of pelvic dilation was present. The capsules were acceptably uniform without significant irregularities. The left kidney measured 8.04 cm. The right kidney measured 8.8 cm.

INTERPRETED BY

Eric Lindquist, DMV
DABVP, Cert. IVUSS

Adrenal Glands

Both **adrenal glands** were visualized and recognized as having normal shape, size, position and echogenicity for this breed. The phrenic vasculature, glandular echogenicity and detail were unremarkable. Capsule, cortex, and medullary definition were normal for this age patient. The left adrenal gland measured 0.67 cm at the caudal pole and 0.6 cm at the cranial pole. The right adrenal gland measured 0.84 cm at the caudal pole and 0.87 cm at the cranial pole.

IMAGING PERFORMED BY

Dr. Abe

HOSPITAL NAME

Abe Enterprises

Spleen

The **spleen** presented a smooth homogeneous parenchyma hyperechoic to liver and renal cortical parenchyma. The capsule was smooth without noticeable expansion or deviation from within the spleen or adjacent pathology. The splenic vasculature demonstrated normal volume without signs of congestion or thrombosis. No sonographic evidence of acute or chronic inflammatory, neoplastic, or infarctual changes was noted. The spleen measured 1.8 cm.

REFERRING VET

Dr. Abe

INVOICE

91374

Liver

The **liver** images submitted revealed subjectively normal liver size, contour, and structure. Parenchymal echogenicity was naturally coarse and hypoechoic to the spleen. Vascular and biliary tracts were of normal volume with no evidence of congestion. The gallbladder presented acceptably thin walls with primarily anechoic content. The cystic and common bile ducts were normal. No pathological hepatic

DATE

8/20/21



PATIENT

lymphadenopathy was evident. No overt structural evidence of inflammatory, infiltrative or regenerative pathology was evident.

Zeuss Mattu

SPECIES

Gastrointestinal

Canine

Examination of the **gastrointestinal tract** revealed a stomach and intestine free of stasis, of normal wall thickness, acceptable curvilinear mural detail, and peristaltic activity. Small and large intestine demonstrated normal luminal chyme and stool consistency respectively. No obstructive or overt infiltrative disease was noted. No associated abnormal lymphatic activity was noted.

BREED

Mastiff

SEX

Pancreas

Intact male

The base and limbs of the **pancreas** were observed to be largely isoechoic to surrounding omental fat. Pancreatic duct and capsular contour were acceptably normal and parenchyma respected normal curvilinear patterns. No overt evidence of active inflammatory or neoplastic disease was noted.

AGE

7 years

ULTRASONOGRAPHIC FINDINGS

Normal abdomen.

WEIGHT

68.1 kg

Minor BPH prostate.

INTERPRETED BY

INTERPRETATION OF THE FINDINGS & FURTHER RECOMMENDATIONS

Eric Lindquist, DMV
DABVP, Cert. IVUSS

The ileocecal junction was clearly visible and there was no evidence of loss of curvilinear patterns. The gastrointestinal tract was empty. I recommend IV fluid support to correct azotemia. Full urinalysis is indicated as well as blood pressure measurements. I do not appreciate any masses in this patient. Other causes of anorexia such as pain related disease, spinal pain, thoracic or CNS disease should all be considered.

IMAGING PERFORMED BY

Dr. Abe

HOSPITAL NAME

Abe Enterprises

REFERRING VET

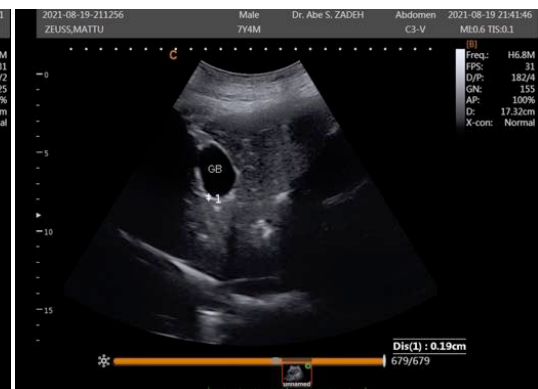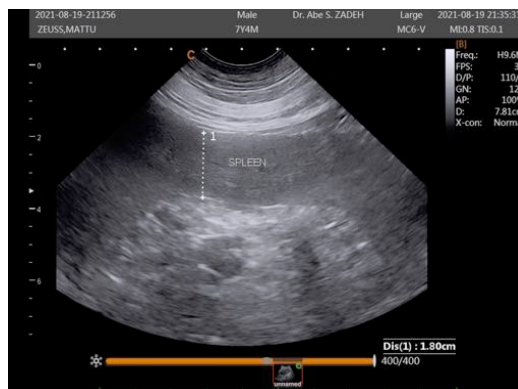
Dr. Abe

INVOICE

91374

DATE

8/20/21





PATIENT

Zeuss Mattu

SPECIES

Canine

BREED

Mastiff

SEX

Intact male

AGE

7 years

WEIGHT

68.1 kg

INTERPRETED BY

Eric Lindquist, DMV
DABVP, Cert. IVUSS

IMAGING PERFORMED BY

Dr. Abe

HOSPITAL NAME

Abe Enterprises

REFERRING VET

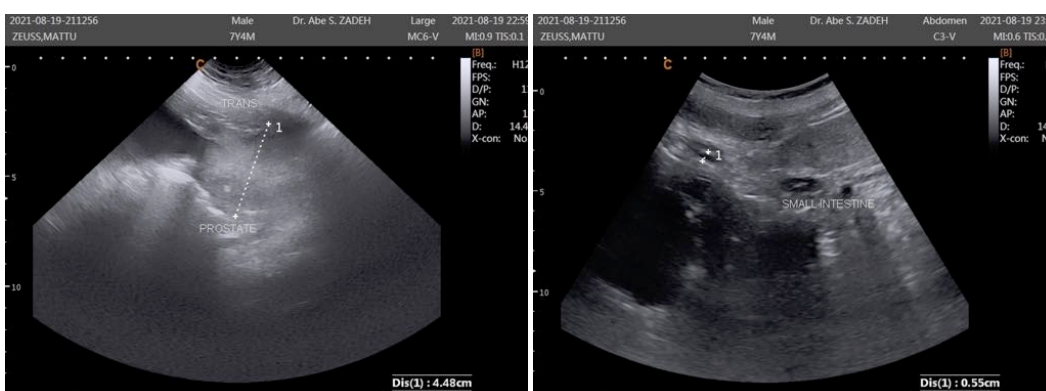
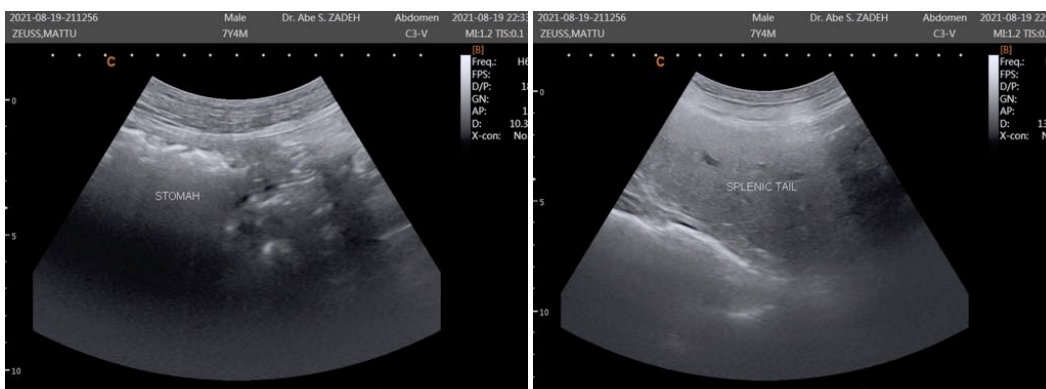
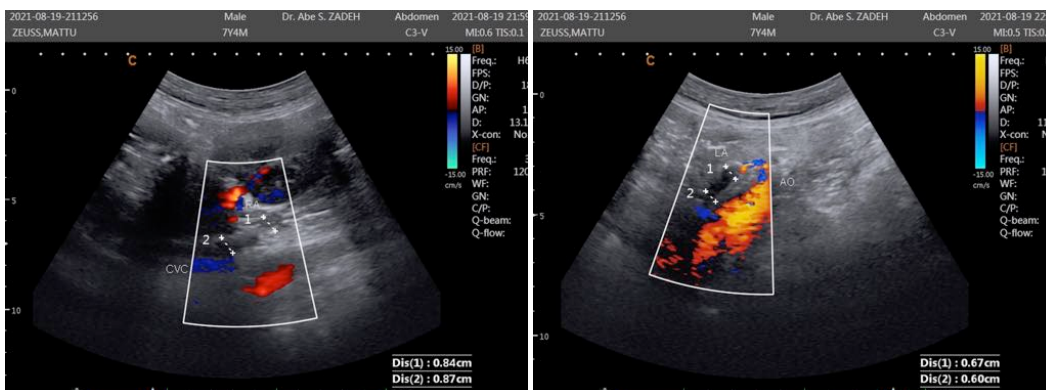
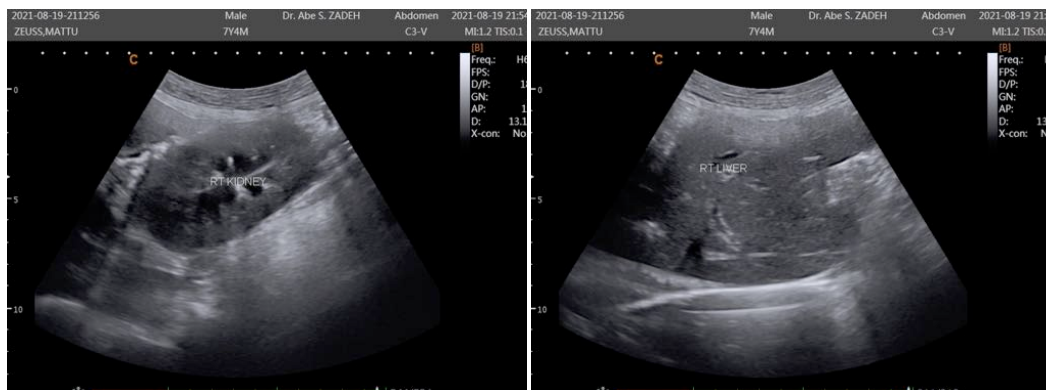
Dr. Abe

INVOICE

91374

DATE

8/20/21





PATIENT

Zeuss Mattu

SPECIES

Canine

BREED

Mastiff

SEX

Intact male

AGE

7 years

WEIGHT

68.1 kg

INTERPRETED BY

Eric Lindquist, DMV
DABVP, Cert. IVUSS

IMAGING PERFORMED BY

Dr. Abe

HOSPITAL NAME

Abe Enterprises

REFERRING VET

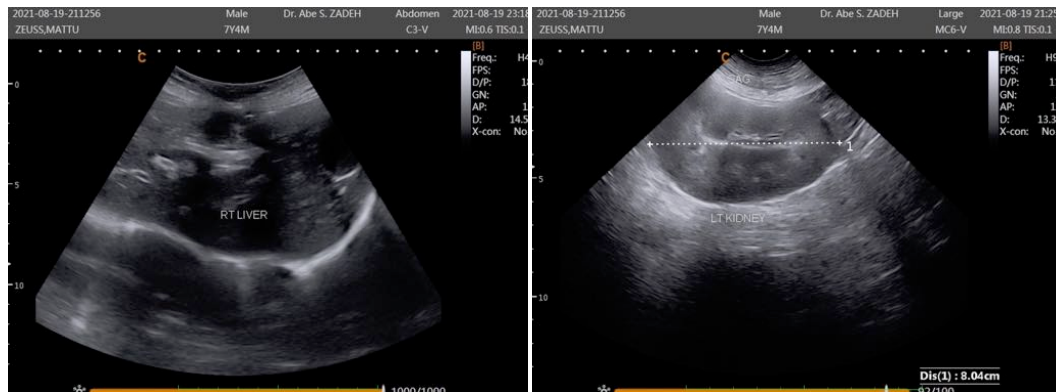
Dr. Abe

INVOICE

91374

DATE

8/20/21



The information and recommendations provided are based on the images presented by the referring veterinarian. No evaluation can be communicated regarding pathology that was not visible in the image/video clips provided.

Thank you for this referral. If the clinical or image interpretation does not parallel your findings or if I can be of any further assistance please contact me.

Eric Lindquist, DMV, DABVP, Cert. IVUSS, CEO of SonoPath.com
info@SonoPath.com