


**PATIENT**

Scooter Centrelli

**PRESENTING CLINICAL SIGNS**

 heart murmur (last echo 5/5/20); recently open-mouth breathing during exam. Is on enalapril  
 Abnormal PE/Chem/CBC/UA Results: pro BNP elevated 382; CBC/chem wnl

**SPECIES**

Feline

**ULTRASONOGRAPHIC EXAMINATION OF THE HEART**
**BREED**

DSH

**SEX**

Neutered Male

**AGE**

9 Years

**WEIGHT**

N/A

FELINE CARDIAC PARAMETERS	BODY WEIGHT (kg)	HR (BPM)	IVSd (cm)	LVIDd (cm)	LVWd (cm)	FS (%)	EF (%)
<b>NORMAL PARAMETER</b>	-----	150-240	0.3-0.6	1.0-2.1	0.25-0.6	35-67	80-100
<b>PATIENT</b>		129	0.45	2.41	0.4	29	59
FELINE CARDIAC PARAMETERS	LA/AO (Boon)	LA/AO HEART BASE (Sisson)	LA 2D 4-chamber long axis AS to FW (Sisson) (cm)	LVOT VEL. (m/s)	RVOT VEL. (m/s)	IVRT (m/)	
<b>NORMAL PARAMETER</b>	<1.5	0.88-1.79	0.7-1.7	<1.6	<1.3	40-60	
<b>PATIENT</b>	1.22	1.32	1.7	2.50	1.2	NM	
Adapted from June Boon, Veterinary Echocardiography, 1998 Sisson D et al. JVIM 1991; 5: 232, Jacobs et al. Am J Vet Res 1985; 46:1705							

**INTERPRETED BY**

 Eric Lindquist, DMV  
 DABVP, Cert. IVUSS

**IMAGING PERFORMED BY**

Diane McFadden

**HOSPITAL NAME**

Parsippany Troy Hills

**REFERRING VET**

Dr. Dulude

**Cardiac Presentation**

The left ventricle in this patient was irregularly thickened with multiple false tendons and mild volume overload. Systolic anterior motion was noted in some views. Turbulence is noted within the left ventricular outflow tract. Minor mitral insufficiency noted with a centralized jet. The right atrium and right ventricle were unremarkable with adequate tricuspid apposition. Within the main pulmonary artery, there is a continuous flow towards the pulmonary valve, which appears to be moderate size on color doppler. The direction of the jet makes proper alignment difficult, as it is obscured by the lung interference. The PDA could not be visualized on 2D imaging. However, within the proximal main pulmonary artery there seems to be origin to this continual flow jet from the craniodorsal position. Aortic velocity may be underestimated.

**ULTRASONOGRAPHIC FINDINGS**

- Possible atypical patent ductus arteriosus or aortopulmonary fistula or coronary fistula - this is likely the cause of the exercise intolerance in this patient.
- Left ventricular false tendons and cardiomyopathy with occasional systolic anterior motion

**INTERPRETATION OF THE FINDINGS & FURTHER RECOMMENDATIONS**

Given that there are not many differential diagnoses for a continuous jet within the main pulmonary artery, patent ductus arteriosus is most likely, however this is an odd position. An aortopulmonary fistula or coronary fistula are also minor potentials. Given the age of this patient, on prior echocardiograms this flow was likely not visualized owing to lung interference and the craniodorsal position. I recommend referral to an interventional cardiologist for further definition under full anesthesia.

**INVOICE**

24852

**DATE**

8/20/21



**PATIENT**

Scoter Centrelli

**SPECIES**

Feline

**BREED**

DSH

**SEX**

Neutered Male

**AGE**

9 Years

**WEIGHT**

N/A

**INTERPRETED BY**

Eric Lindquist, DMV  
DABVP, Cert. IVUSS

**IMAGING PERFORMED BY**

Diane McFadden

**HOSPITAL NAME**

Parsippany Troy Hills

**REFERRING VET**

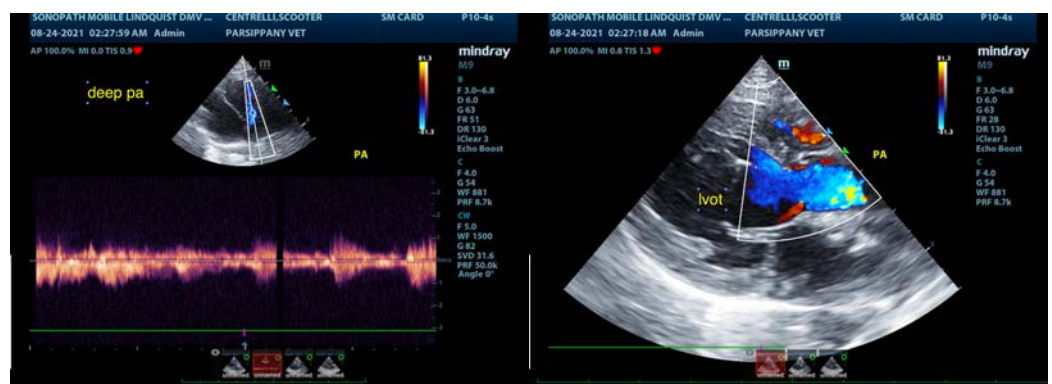
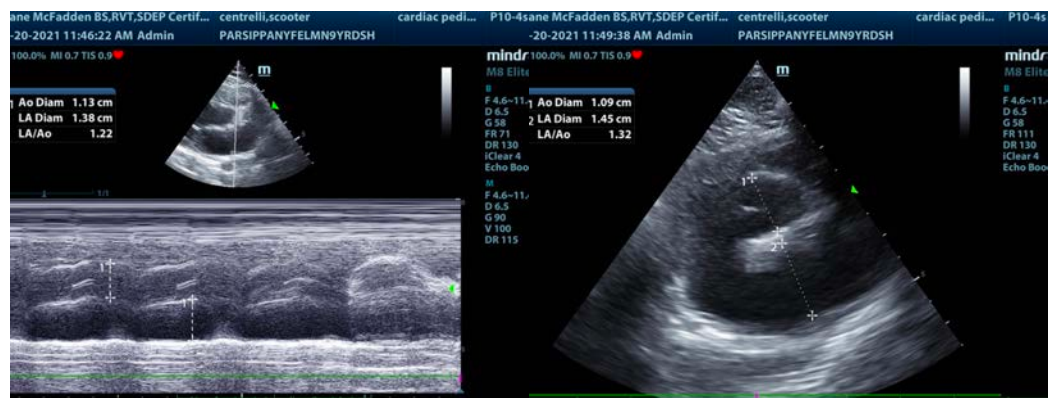
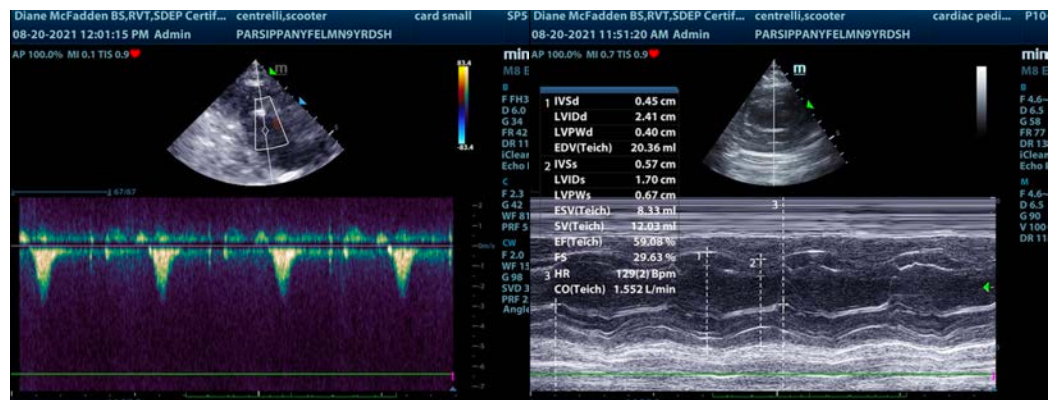
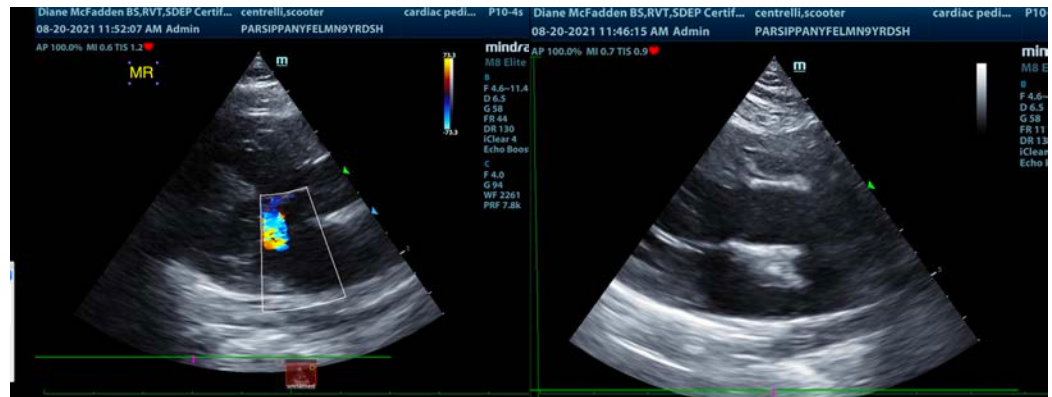
Dr. Dulude

**INVOICE**

24852

**DATE**

8/20/21





**PATIENT**

Scooter Centrelli

**SPECIES**

Feline

**BREED**

DSH

**SEX**

Neutered Male

**AGE**

9 Years

**WEIGHT**

N/A

**INTERPRETED BY**

Eric Lindquist, DMV  
DABVP, Cert. IVUSS

**IMAGING PERFORMED BY**

Diane McFadden

**HOSPITAL NAME**

Parsippany Troy Hills

**REFERRING VET**

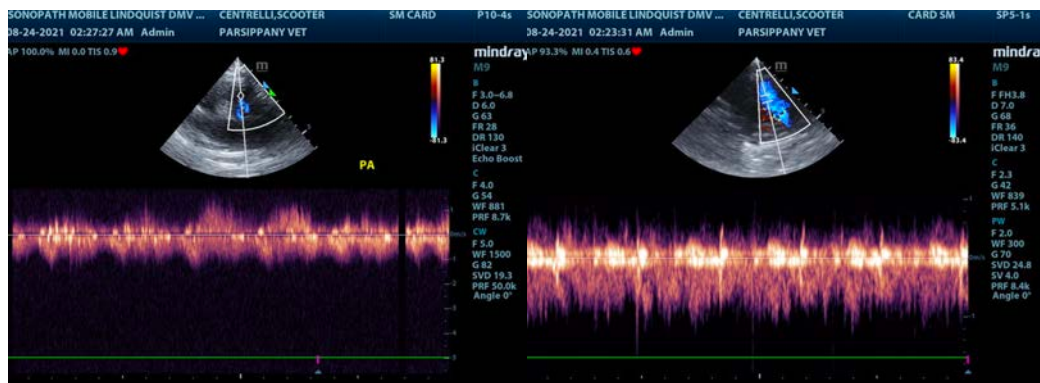
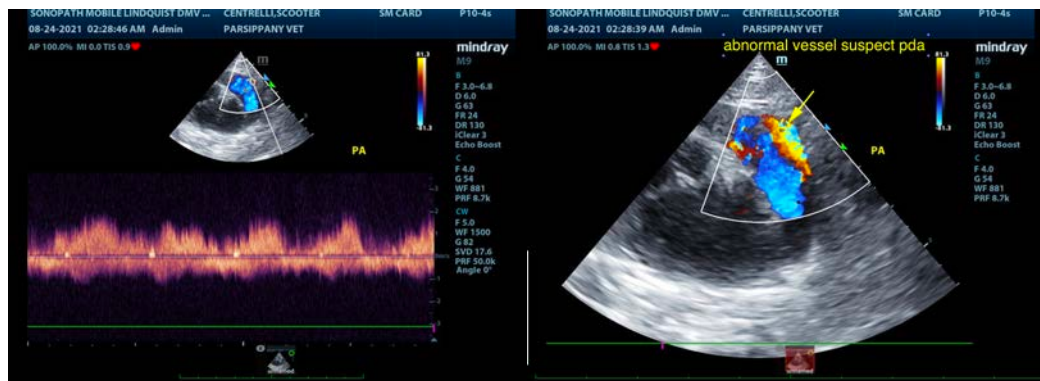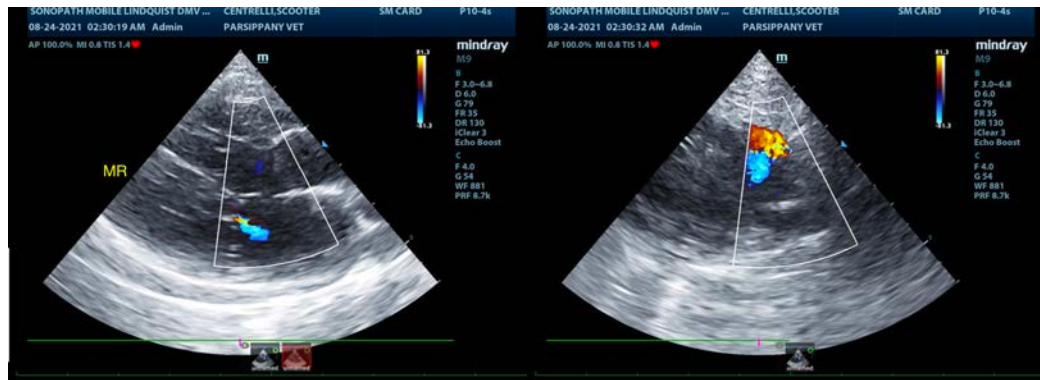
Dr. Dulude

**INVOICE**

24852

**DATE**

8/20/21



The information and recommendations provided are based on the images presented by the referring veterinarian. No evaluation can be communicated regarding pathology that was not visible in the image/video clips provided.

Thank you for this referral. If the clinical or image interpretation does not parallel your findings or if I can be of any further assistance please contact me.

Eric Lindquist, DMV, DABVP, Cert. IVUSS, CEO of SonoPath.com  
[info@SonoPath.com](mailto:info@SonoPath.com)