



**PATIENT**

Jazzy Koogler

**SPECIES**

Canine

**BREED**

Lab Mix

**SEX**

Spayed Female

**AGE**

3 Years

**WEIGHT**

66.8 Pounds

**INTERPRETED BY**

Eric Lindquist, DMV  
DABVP, Cert. IVUSS

**IMAGING PERFORMED BY**

Griffin

**HOSPITAL NAME**

Northside VC

**REFERRING VET**

Griffin

**INVOICE**

12646

**DATE**

8/20/21

**PRESENTING CLINICAL SIGNS**

History: Patient is not eating well for a couple of months but has not lost weight. Patient did not improve with omeprazole and cerenia

Abnormal PE/Chem/CBC/UA Results: PE: WNL CBC/CHEM/T4/SDMA wnl Rads: No evidence of mass in chest or abdomen

**ULTRASONOGRAPHIC EXAMINATION OF THE ABDOMEN**

**Urinary System**

The **urinary bladder**, trigone, and pelvic urethra presented normal thicknesses and normal tone. The ureters were not visible which is normal. No uroliths or sediment were visualized and anechoic urine was present. No evidence of inflammatory or neoplastic changes were noted. Ureteral papillae were normal.

The **kidneys** revealed normal size and structure, corticomedullary definition and ratio for this age. The cortices presented largely uniform texture with normal echogenic relationship to liver and spleen. Medullary structure differed distinctly from the cortex and no evidence of pelvic dilation was present. The capsules were acceptably uniform without significant irregularities. The left kidney measured 6.0 cm. The right kidney measured 6.0 cm.

**Adrenal Glands**

Both **adrenal glands** were visualized and recognized as having normal shape, size, position and echogenicity for this breed. The phrenic vasculature, glandular echogenicity and detail were unremarkable. Capsule, cortex, and medullary definition were normal for this age patient. The left adrenal gland measured 0.4 cm. The right adrenal gland measured 0.6 cm.

**Spleen**

The **spleen** presented a smooth homogeneous parenchyma hyperechoic to liver and renal cortical parenchyma. The capsule was smooth without noticeable expansion or deviation from within the spleen or adjacent pathology. The splenic vasculature demonstrated normal volume without signs of congestion or thrombosis. No sonographic evidence of acute or chronic inflammatory, neoplastic, or infarctual changes were noted.

**Liver**

The **liver** images submitted revealed subjectively normal liver size, contour, and structure. Parenchymal echogenicity was naturally coarse and hypoechoic to the spleen. Vascular and biliary tracts were of normal volume with no evidence of congestion. The gallbladder presented acceptably thin walls with primarily anechoic content. The cystic and common bile ducts were normal. No pathological hepatic lymphadenopathy was evident. No overt structural evidence of inflammatory, infiltrative or regenerative pathology was evident.

**Gastrointestinal**

Examination of the **gastrointestinal tract** revealed a stomach and intestine free of stasis, of normal wall thickness, acceptable curvilinear mural detail, and peristaltic activity. Small and large intestine demonstrated normal luminal chyme and stool consistency respectively. No obstructive or overt infiltrative disease was noted. No associated abnormal lymphatic activity was noted. No evidence of



**PATIENT**

macro-ulcerative changes. Micro-ulcerative changes cannot be entirely ruled out, would necessitate endoscopy.

Jazzy Koogler

**Pancreas**

**SPECIES**

The base and limbs of the **pancreas** were observed to be largely isoechoic to surrounding omental fat. Pancreatic duct and capsular contour were acceptably normal and parenchyma respected normal curvilinear patterns. No overt evidence of active inflammatory or neoplastic disease was noted.

Canine

**BREED**

**ULTRASONOGRAPHIC FINDINGS**

Lab Mix

- Structurally unremarkable abdomen

**SEX**

No obvious evidence of ulcerative disease. Other causes of anorexia such as pain elsewhere should be considered such as spinal pain, thoracic or CNS disease, yet the abdomen appears benign. Screening for occult Addison's could be considered even though the adrenals appear normal in size and contour.

Spayed Female

**AGE**

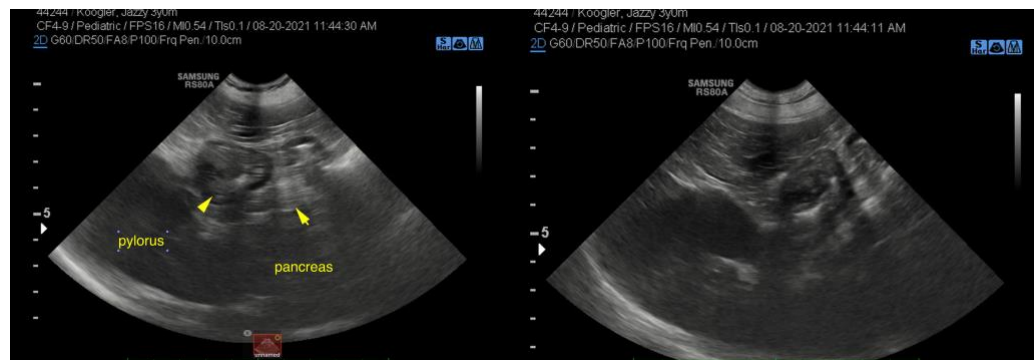
3 Years

**WEIGHT**

66.8 Pounds

**INTERPRETED BY**

Eric Lindquist, DMV  
DABVP, Cert. IVUSS

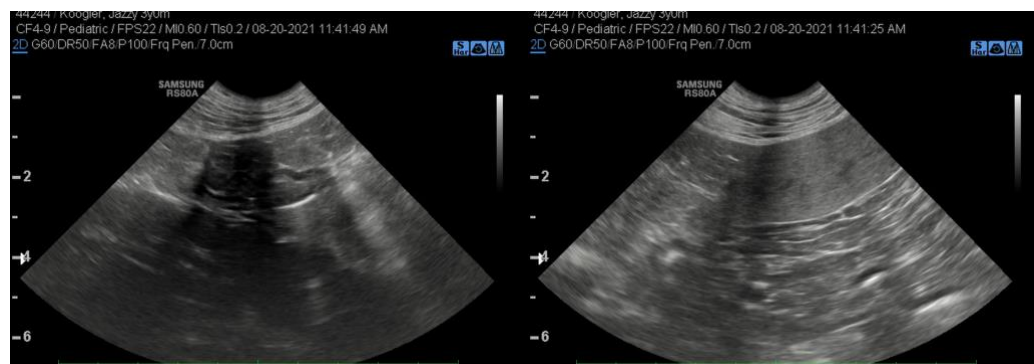


**IMAGING PERFORMED BY**

Griffin

**HOSPITAL NAME**

Northside VC



**REFERRING VET**

Griffin

**INVOICE**

12646

**DATE**

8/20/21



**PATIENT**

Jazzy Koogler

**SPECIES**

Canine

**BREED**

Lab Mix

**SEX**

Spayed Female

**AGE**

3 Years

**WEIGHT**

66.8 Pounds

**INTERPRETED BY**

Eric Lindquist, DMV  
DABVP, Cert. IVUSS

**IMAGING PERFORMED BY**

Griffin

**HOSPITAL NAME**

Northside VC

**REFERRING VET**

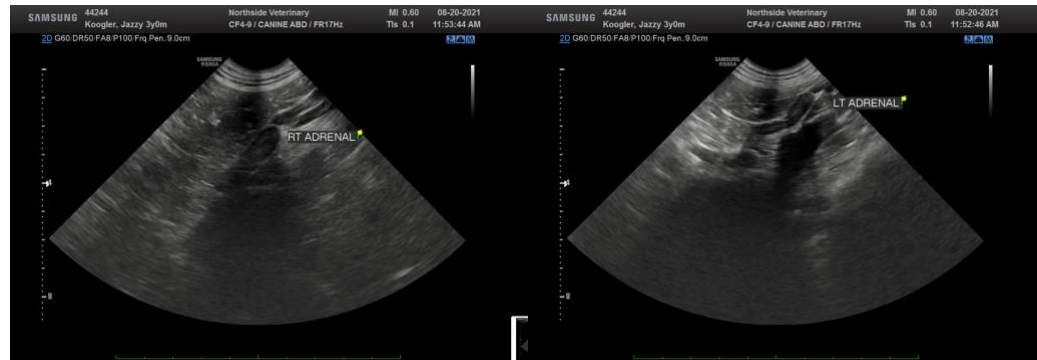
Griffin

**INVOICE**

12646

**DATE**

8/20/21



The information and recommendations provided are based on the images presented by the referring veterinarian. No evaluation can be communicated regarding pathology that was not visible in the image/video clips provided.

Thank you for this referral. If the clinical or image interpretation does not parallel your findings or if I can be of any further assistance please contact me.

**Eric Lindquist**, DMV, DABVP, Cert. IVUSS, CEO of SonoPath.com  
info@SonoPath.com