



**PATIENT PRESENTING CLINICAL SIGNS**

Buddy Gonzalez Abdominal mass.

**SPECIES ULTRASONOGRAPHIC EXAMINATION OF THE ABDOMEN**

**Canine Urinary System**

The **urinary bladder** revealed sand accumulation of approximately 1.0 cm.

**BREED** The **kidneys** revealed largely normal size and structure, corticomedullary definition and ratio (cortex 1/3 of medulla) were essentially maintained with some age-related loss of curvilinear patterns regarding the capsule and C/M junction. The cortices presented largely uniform texture with some increased echogenicity expected for his age patient. Medullary structure differed distinctly from that of the cortex. Mineralization noted in both kidneys. The right kidney measured 6.08 cm. The left kidney measured 5.97 cm. Trace pyelectasia noted in the left kidney.

**SEX**

Neutered Male

**Adrenal Glands**

**AGE**

13 Years

Both **adrenal glands** were visualized and recognized as having normal shape, size, position and echogenicity for this breed. The phrenic vasculature, glandular echogenicity and detail were unremarkable. Capsule, cortex, and medullary definition were normal for this age patient. The right adrenal gland measured 1.66 cm x 0.83 cm at the caudal pole and 1.55 cm at the cranial pole. The left adrenal gland measured 0.62 cm at the caudal pole and 0.47 cm at the cranial pole.

**WEIGHT**

N/A

**Spleen**

An undifferentiated, hypoechoic nodular parenchymal mass measuring 7.85 cm appeared to be deriving from the **spleen**. Portions of normal spleen appeared to be present with heterogeneous hyperechoic nodular changes noted. The mass appeared to derive from the cranial pole of the spleen, as it folded towards the liver.

**INTERPRETED BY**

Eric Lindquist, DMV  
DABVP, Cert. IVUSS

**Liver**

The **liver** revealed multifocal hyperechoic nodules and coarse architecture. The largest nodule measured 1.37 cm. The gallbladder and common bile duct were unremarkable.

**IMAGING PERFORMED BY**

Kelly Vazquez

**Gastrointestinal**

Examination of the **gastrointestinal tract** revealed a stomach and intestine free of stasis, of normal wall thickness, acceptable curvilinear mural detail, and peristaltic activity. Small and large intestine demonstrated normal luminal chyme and stool consistency respectively. No obstructive or overt infiltrative disease was noted. No associated abnormal lymphatic activity was noted.

**HOSPITAL NAME**

Englewood Vet Center

**REFERRING VET**

Dr. Ezik

**Pancreas**

The base and limbs of the **pancreas** were observed to be largely isoechoic to surrounding omental fat. Pancreatic duct and capsular contour were acceptably normal and parenchyma respected normal curvilinear patterns. No overt evidence of active inflammatory or neoplastic disease was noted.

**INVOICE**

24851

**Heart**

Rapid view of the heart revealed no evident pathology in the right auricle or pericardium.

**DATE**

8/20/21



**PATIENT**

Buddy Gonzalez

**SPECIES**

Canine

**BREED**

Beagle

**SEX**

Neutered Male

**AGE**

13 Years

**WEIGHT**

N/A

**INTERPRETED BY**

Eric Lindquist, DMV  
DABVP, Cert. IVUSS

**IMAGING PERFORMED BY**

Kelly Vazquez

**HOSPITAL NAME**

Englewood Vet Center

**REFERRING VET**

Dr. Ezik

**INVOICE**

24851

**DATE**

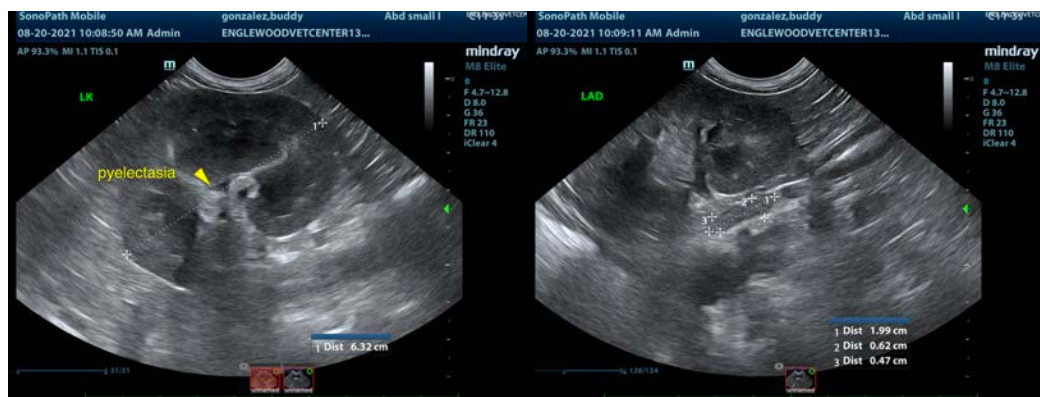
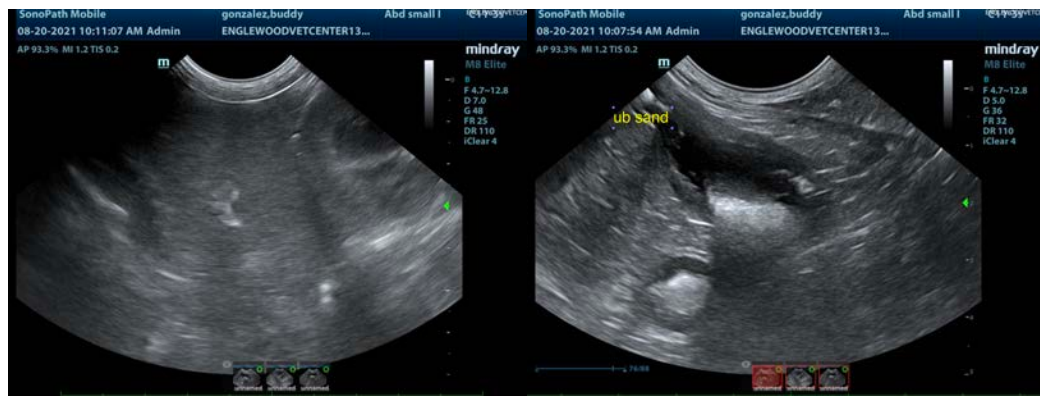
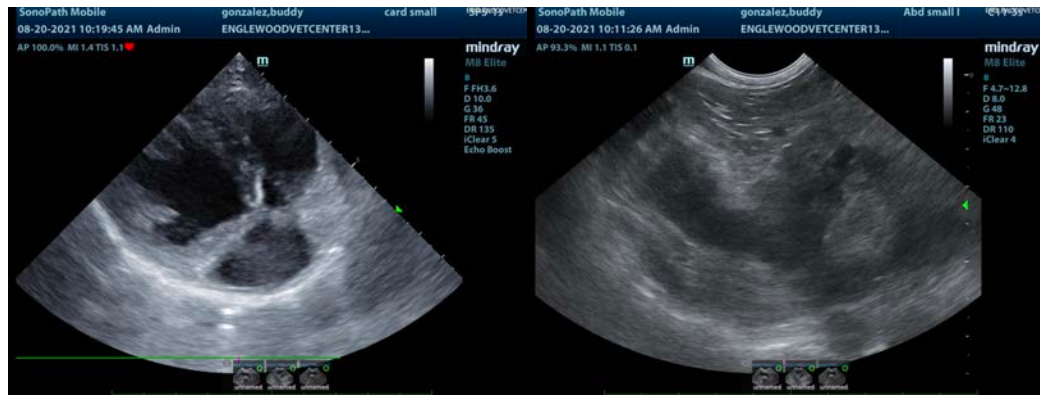
8/20/21

**ULTRASONOGRAPHIC FINDINGS**

- Large sarcoma type splenic mass, potential early metastatic disease to the liver.
- Bladder sand
- Renal calculi

**INTERPRETATION OF THE FINDINGS & FURTHER RECOMMENDATIONS**

Either ultrasound guided FNA of the splenic mass and liver nodules could be considered for further definition and staging, or direct exploratory surgery with expectations towards splenectomy, liver biopsy and cystotomy and sand analysis. Some nodular omental changes noted near the splenic mass. Local extension into the omentum is a potential. Likely sarcoma. 3-view chest radiographs warranted.





**PATIENT**

Buddy Gonzalez

**SPECIES**

Canine

**BREED**

Beagle

**SEX**

Neutered Male

**AGE**

13 Years

**WEIGHT**

N/A

**INTERPRETED BY**

Eric Lindquist, DMV  
DABVP, Cert. IVUSS

**IMAGING PERFORMED BY**

Kelly Vazquez

**HOSPITAL NAME**

Englewood Vet Center

**REFERRING VET**

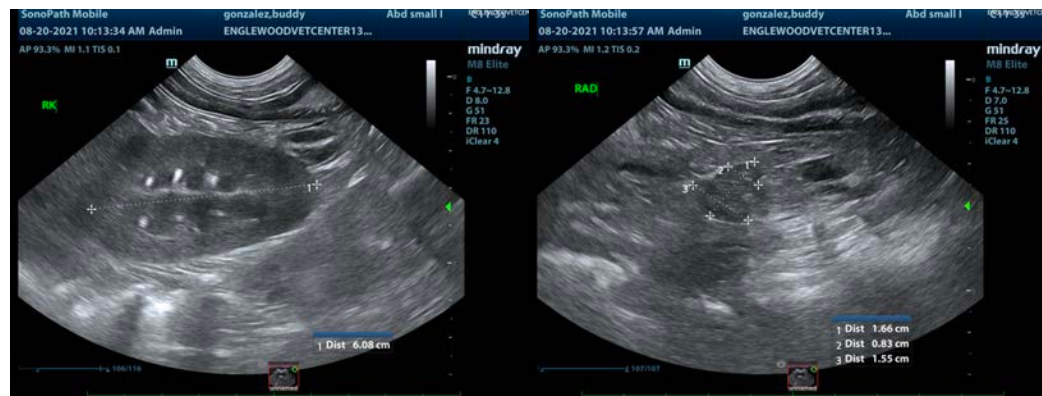
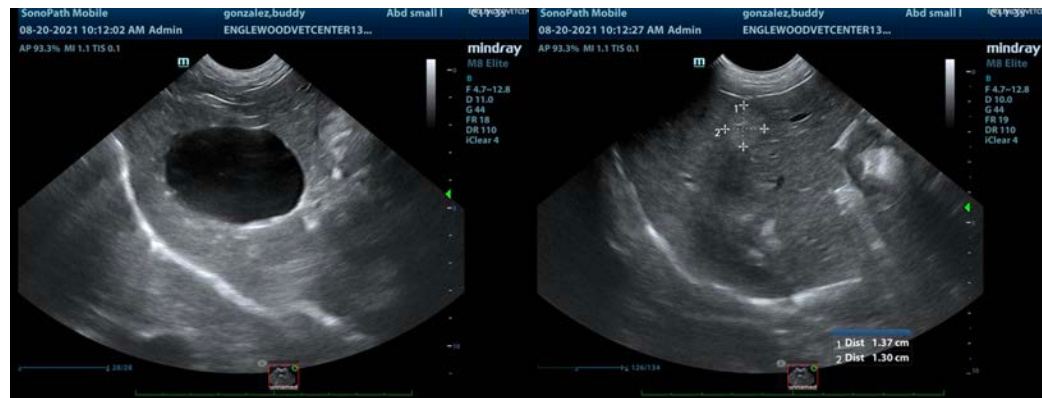
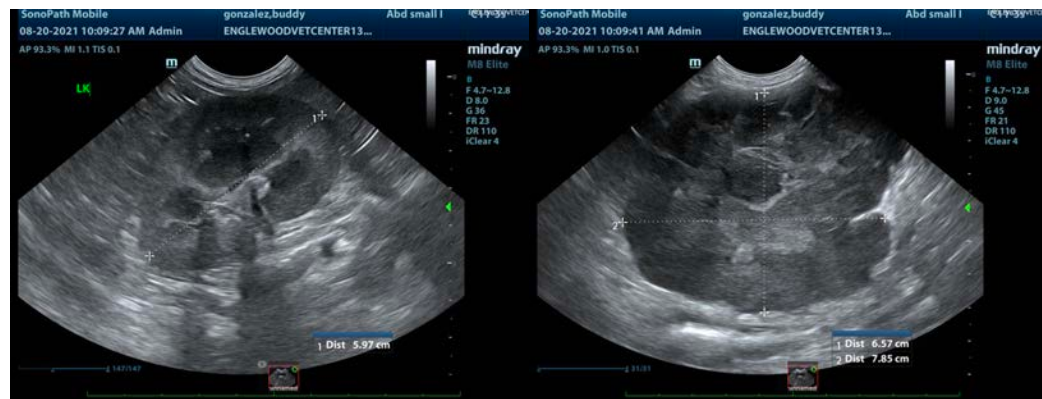
Dr. Ezik

**INVOICE**

24851

**DATE**

8/20/21



The information and recommendations provided are based on the images presented by the referring veterinarian. No evaluation can be communicated regarding pathology that was not visible in the image/video clips provided.

Thank you for this referral. If the clinical or image interpretation does not parallel your findings or if I can be of any further assistance please contact me.

**Eric Lindquist**, DMV, DABVP, Cert. IVUSS, CEO of SonoPath.com  
[info@SonoPath.com](mailto:info@SonoPath.com)