



PATIENT

Sky Lovell

SPECIES

Canine

BREED

Miniature Pinscher

SEX

Spayed female

AGE

3 years

WEIGHT

18.6 lbs

INTERPRETED BY

Eric Lindquist, DMV
DABVP, Cert. IVUSS

IMAGING PERFORMED BY

Dr. Casas

HOSPITAL NAME

State Ave VC

REFERRING VET

Dr. Casas

INVOICE

76377

DATE

8/2/23

PRESENTING CLINICAL SIGNS

History: Yesterday was normal This morning P was very lethargic Did not eat this morning Seems like she wants to jump up on bed but was unable to Did not defecate this morning O concerned about bowels/parasites Normal bowel movement yesterday Feeds rice, turkey, peas, carrots No vomiting Was walking slower, ears back Usually very bouncy When walking was holding head lower Meds- none PE: NSF, Temp- 101.5F

Abnormal PE/Chem/CBC/UA Results: GLU 119 * mg/dL, GLOB 2.0 * g/dL, RBC 8.64 10¹²/l, HGB 19.2 g/dl, HCT 62.82 %, MCHC 30.6 g/dl

ULTRASONOGRAPHIC EXAMINATION OF THE ABDOMEN

Urinary System

The **urinary bladder**, trigone, and pelvic urethra presented normal thicknesses and normal tone. The ureters were not visible which is normal. No uroliths or sediment were visualized and anechoic urine was present. No evidence of inflammatory or neoplastic changes was noted. Ureteral papillae were normal.

The **kidneys** revealed normal size and structure, corticomedullary definition and ratio for this age. The cortices presented largely uniform texture with normal echogenic relationship to liver and spleen. Medullary structure differed distinctly from the cortex and no evidence of pelvic dilation was present. The capsules were acceptably uniform without significant irregularities. The kidney measured 5.0 cm.

Adrenal Glands

The **adrenal glands** were not visualized.

Spleen

The **spleen** presented a smooth homogeneous parenchyma hyperechoic to liver and renal cortical parenchyma. The capsule was smooth without noticeable expansion or deviation from within the spleen or adjacent pathology. The splenic vasculature demonstrated normal volume without signs of congestion or thrombosis. No sonographic evidence of acute or chronic inflammatory, neoplastic, or infarctual changes was noted.

Liver

The **liver** images submitted revealed subjectively normal liver size, contour, and structure. Parenchymal echogenicity was naturally coarse and hypoechoic to the spleen. Vascular and biliary tracts were of normal volume with no evidence of congestion. The gallbladder presented acceptably thin walls with primarily anechoic content. The cystic and common bile ducts were normal. No pathological hepatic lymphadenopathy was evident. No overt structural evidence of inflammatory, infiltrative or regenerative pathology was evident.



PATIENT

Sky Lovell

SPECIES

Canine

BREED

Miniature Pinscher

SEX

Spayed female

AGE

3 years

WEIGHT

18.6 lbs

INTERPRETED BY

Eric Lindquist, DMV
DABVP, Cert. IVUSS

IMAGING PERFORMED BY

Dr. Casas

HOSPITAL NAME

State Ave VC

REFERRING VET

Dr. Casas

INVOICE

76377

DATE

8/2/23

Gastrointestinal

Examination of the **gastrointestinal tract** revealed a stomach and intestine free of stasis, of normal wall thickness, acceptable curvilinear mural detail, and peristaltic activity. Small and large intestine demonstrated normal luminal chyme and stool consistency respectively. No obstructive or overt infiltrative disease was noted. No associated abnormal lymphatic activity was noted.

Pancreas

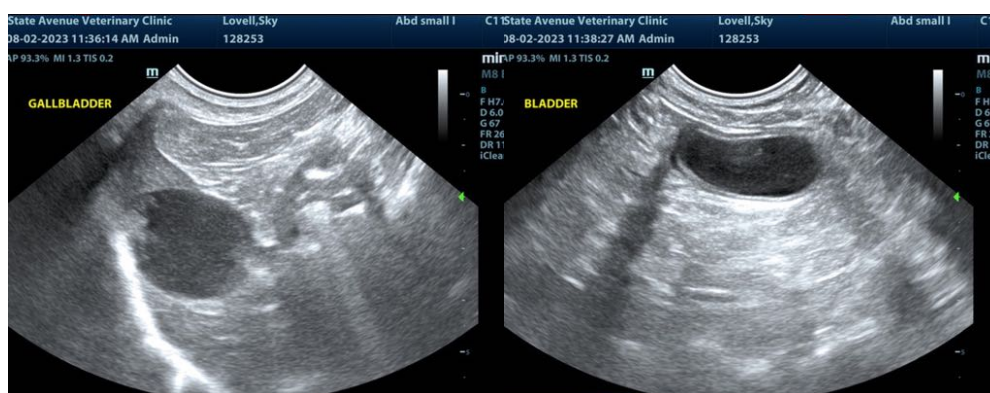
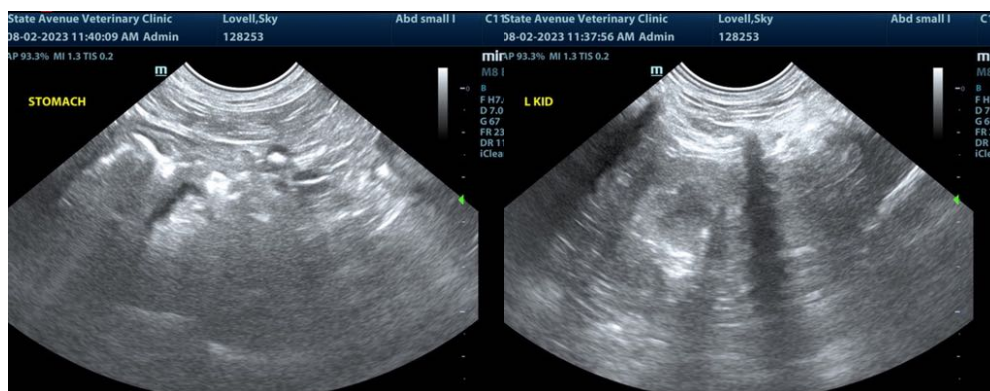
The base and limbs of the **pancreas** were observed to be largely isoechoic to surrounding omental fat. Pancreatic duct and capsular contour were acceptably normal and parenchyma respected normal curvilinear patterns. No overt evidence of active inflammatory or neoplastic disease was noted.

ULTRASONOGRAPHIC FINDINGS

Structurally unremarkable abdomen.

INTERPRETATION OF THE FINDINGS & FURTHER RECOMMENDATIONS

Supportive care should prove effective. Screening for Addison's is warranted as the adrenal glands were not overtly visible.





PATIENT

Sky Lovell

The information and recommendations provided are based on the images presented by the referring veterinarian/sonographer. No evaluation can be communicated regarding pathology that was not visible in the image/video clips provided.

SPECIES

Canine

Thank you for this referral. If the clinical or image interpretation does not parallel your findings or if I can be of any further assistance please contact me.

BREED

Miniature Pinscher

Eric Lindquist, DMV, DABVP, Cert. IVUSS, CEO of SonoPath.com
info@SonoPath.com

SEX

Spayed female

AGE

3 years

WEIGHT

18.6 lbs

INTERPRETED BY

Eric Lindquist, DMV
DABVP, Cert. IVUSS

IMAGING PERFORMED BY

Dr. Casas

HOSPITAL NAME

State Ave VC

REFERRING VET

Dr. Casas

INVOICE

76377

DATE

8/2/23