



**PATIENT**

Emma Stevens

**SPECIES**

Canine

**BREED**

Labrador Retriever

**SEX**

Spayed female

**AGE**

12 years

**WEIGHT**

71 lbs

**INTERPRETED BY**

Eric Lindquist, DMV  
DABVP, Cert. IVUSS

**IMAGING PERFORMED BY**

Anthony Krawitz

**HOSPITAL NAME**

Calusa VC

**REFERRING VET**

Dr. Krawitz

**INVOICE**

76375

**DATE**

8/2/23

**PRESENTING CLINICAL SIGNS**

History: She is doing well clinically other than back pain and several confirmed lipomas. About a year ago, she had an intermediate grade soft tissue spindle cell sarcoma excised from her side, which was totally excised by a specialist and has not recurred. At that time, a CT scan was performed and an enlarged right adrenal gland was found 19mm X 11mm with a small nodule within the cranial pole. A recent US a few months ago of the right adrenal gland showed it to be 19.9mm X 11.2mm, so no change. An OncoK9 cancer screen was run and was negative too.

Abnormal PE/Chem/CBC/UA Results: Recent BW WNL including Thyroid. Very mild Alk phos increase and Triglycerides.

**ULTRASONOGRAPHIC EXAMINATION OF THE ABDOMEN**

**Urinary System**

The **urinary bladder**, trigone, and pelvic urethra presented normal thicknesses and normal tone. The ureters were not visible which is normal. No uroliths or sediment were visualized and anechoic urine was present. No evidence of inflammatory or neoplastic changes was noted. Ureteral papillae were normal.

The **kidneys** revealed normal size and structure, corticomedullary definition and ratio for this age. The cortices presented largely uniform texture with normal echogenic relationship to liver and spleen. Medullary structure differed distinctly from the cortex and no evidence of pelvic dilation was present. The capsules were acceptably uniform without significant irregularities. The right kidney measured 6.5 cm. The left kidney measured 6.65 cm.

**Adrenal Glands**

The left **adrenal gland** was visualized and recognized as having normal shape, size, position and echogenicity for this breed. The phrenic vasculature, glandular echogenicity and detail were unremarkable. Capsule, cortex, and medullary definition were normal for this age patient. The left adrenal gland measured 1.83 x 0.59 cm at the caudal pole and 0.51 cm at the cranial pole. The right adrenal gland was heterogenous and measured 2.88 x 1.98 cm at the cranial pole and 0.89 cm at the caudal pole.

**Spleen**

The **spleen** presented a smooth homogeneous parenchyma hyperechoic to liver and renal cortical parenchyma. The capsule was smooth without noticeable expansion or deviation from within the spleen or adjacent pathology. The splenic vasculature demonstrated normal volume without signs of congestion or thrombosis. No sonographic evidence of acute or chronic inflammatory, neoplastic, or infarctual changes was noted.

**Liver**

The **liver** images from right and left intercostal as well as subcostal views revealed subjectively normal liver size, contour, and structure. Some age-related parenchymal remodeling was noted but likely not



**PATIENT**

Emma Stevens

clinically significant at this time. Vascular and biliary tracts were of normal volume and no evidence of congestion was noted. The gallbladder presented some dependent debris with essentially normal contour. The cystic and common bile ducts were normal. No overt evidence of active inflammatory, infiltrative or regenerative pathology was noted but should be paired with current or past LE elevations regarding any clinical significance to this presentation. The hepatic lymph nodes were unremarkable.

**SPECIES**

Canine

**Gastrointestinal**

**BREED**

Labrador Retriever

Examination of the **gastrointestinal tract** revealed a stomach and intestine free of stasis, of normal wall thickness, acceptable curvilinear mural detail, and peristaltic activity. Small and large intestine demonstrated normal luminal chyme and stool consistency respectively. No obstructive or overt infiltrative disease was noted. No associated abnormal lymphatic activity was noted.

**SEX**

Spayed female

**Pancreas**

**AGE**

12 years

The base and limbs of the **pancreas** were observed to be largely isoechoic to surrounding omental fat. Pancreatic duct and capsular contour were acceptably normal and parenchyma respected normal curvilinear patterns. No overt evidence of active inflammatory or neoplastic disease was noted.

**WEIGHT**

71 lbs

**ULTRASONOGRAPHIC FINDINGS**

Heterogenous right adrenal gland.

Age related abdominal changes.

**INTERPRETED BY**

Eric Lindquist, DMV  
DABVP, Cert. IVUSS

**INTERPRETATION OF THE FINDINGS & FURTHER RECOMMENDATIONS**

There was no evidence of primary disease responsible for the clinical signs. Referred back pain/orthopedic pain is likely.

**IMAGING PERFORMED BY**

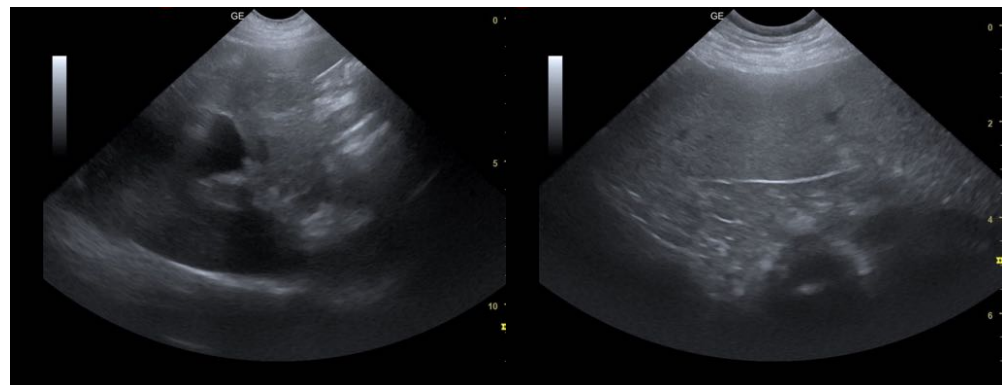
Anthony Krawitz

**HOSPITAL NAME**

Calusa VC

**REFERRING VET**

Dr. Krawitz



**INVOICE**

76375

**DATE**

8/2/23



**PATIENT**

Emma Stevens

**SPECIES**

Canine

**BREED**

Labrador Retriever

**SEX**

Spayed female

**AGE**

12 years

**WEIGHT**

71 lbs

**INTERPRETED BY**

Eric Lindquist, DMV  
DABVP, Cert. IVUSS

**IMAGING PERFORMED BY**

Anthony Krawitz

**HOSPITAL NAME**

Calusa VC

**REFERRING VET**

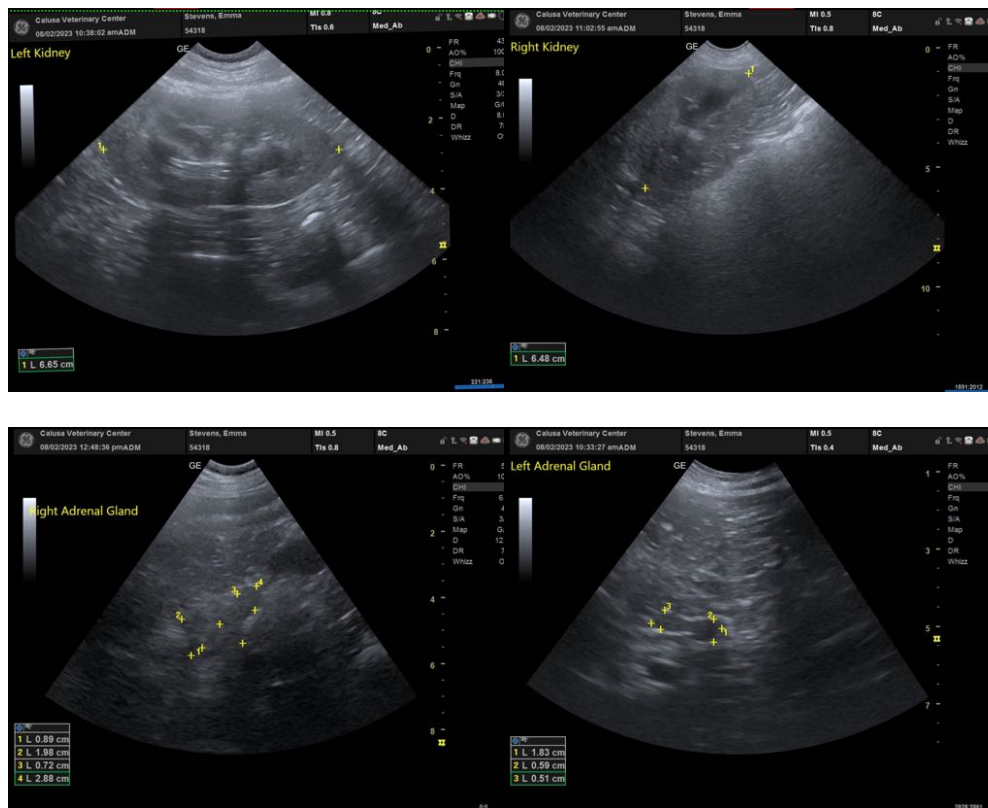
Dr. Krawitz

**INVOICE**

76375

**DATE**

8/2/23



The information and recommendations provided are based on the images presented by the referring veterinarian/sonographer. No evaluation can be communicated regarding pathology that was not visible in the image/video clips provided.

Thank you for this referral. If the clinical or image interpretation does not parallel your findings or if I can be of any further assistance please contact me.

**Eric Lindquist**, DMV, DABVP, Cert. IVUSS, CEO of SonoPath.com  
info@SonoPath.com