

**PATIENT**

Biscuit Laurice

**PRESENTING CLINICAL SIGNS**

History: recheck from yesterday Dog has been NPO since Tues am

**SPECIES**

Canine

**ULTRASONOGRAPHIC EXAMINATION OF THE ABDOMEN**

**Gastrointestinal**

There is a minor amount of ingesta noted int eh stomach. The small intestine revealed transit of chyme without overt obstruction. The colon was filled with hard stool.

**BREED**

Lab Mix

**ULTRASONOGRAPHIC FINDINGS**

**SEX**

Spayed female

Minor retention of chyme was noted in the stomach.

Full colon.

**AGE**

2 years

**INTERPRETATION OF THE FINDINGS & FURTHER RECOMMENDATIONS**

There was no overt foreign body. I recommend an enema in this patient to evacuate the colon and enhance GI emptying. There was no overt evidence of obstruction.

**WEIGHT**

78 lbs

**INTERPRETED BY**

Eric Lindquist, DMV  
DABVP, Cert. IVUSS

**IMAGING PERFORMED BY**

Jenn

**HOSPITAL NAME**

Rockaway AH

**REFERRING VET**

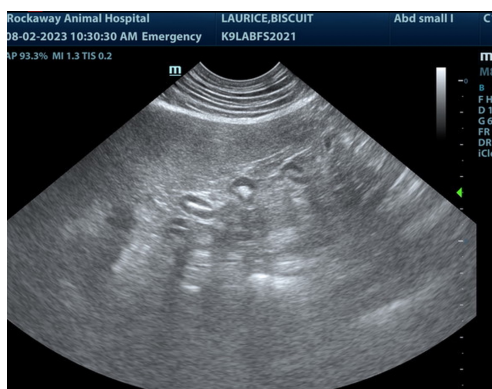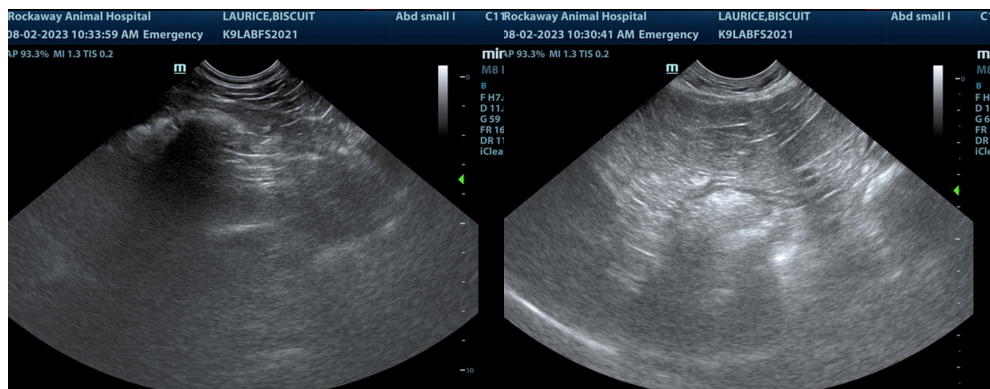
Dr. Maniar

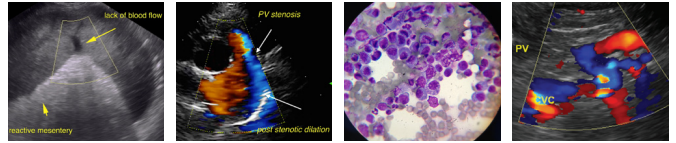
**INVOICE**

76373

**DATE**

8/2/23





**PATIENT**

Biscuit Laurice

The information and recommendations provided are based on the images presented by the referring veterinarian/sonographer. No evaluation can be communicated regarding pathology that was not visible in the image/video clips provided.

**SPECIES**

Canine

Thank you for this referral. If the clinical or image interpretation does not parallel your findings or if I can be of any further assistance please contact me.

**BREED**

Lab Mix

**Eric Lindquist**, DMV, DABVP, Cert. IVUSS, CEO of SonoPath.com  
info@SonoPath.com

**SEX**

Spayed female

**AGE**

2 years

**WEIGHT**

78 lbs

**INTERPRETED BY**

Eric Lindquist, DMV  
DABVP, Cert. IVUSS

**IMAGING  
PERFORMED BY**

Jenn

**HOSPITAL NAME**

Rockaway AH

**REFERRING VET**

Dr. Maniar

**INVOICE**

76373

**DATE**

8/2/23