



## PATIENT

Notte Kinsley

## SPECIES

Feline

## BREED

Main Coon

## SEX

Neutered Male

## AGE

16 Years

## WEIGHT

14 Pounds

## PRESENTING CLINICAL SIGNS

History: Murmur noted today 3/6. Dental due on 8/15.22

Abnormal PE/Chem/CBC/UA Results: WNL

## ULTRASONOGRAPHIC EXAMINATION OF THE HEART

FELINE CARDIAC PARAMETERS	BODY WEIGHT (kg)	HR (BPM)	IVSd (cm)	LVIDd (cm)	LVWd (cm)	FS (%)	EF (%)
<b>NORMAL PARAMETER</b>	-----	150-240	0.3-0.6	1.0-2.1	0.25-0.6	35-67	80-100
<b>PATIENT</b>	--	NM	0.6	1.17	0.64	50	--
FELINE CARDIAC PARAMETERS	LA/AO (Boon)	LA/AO HEART BASE (Sisson)	LA 2D 4-chamber long axis AS to FW (Sisson) (cm)	LVOT VEL. (m/s)	RVOT VEL. (m/s)	IVRT (m/)	
<b>NORMAL PARAMETER</b>	<1.5	0.88-1.79	0.7-1.7	<1.6	<1.3	40-60	
<b>PATIENT</b>	1.15	1.2	--	--	--	NM	
Adapted from June Boon, Veterinary Echocardiography, 1998							
Sisson D et al. JVIM 1991; 5: 232, Jacobs et al. Am J Vet Res 1985; 46:1705							

## INTERPRETED BY

Eric Lindquist, DMV  
DABVP, Cert. IVUSS

## IMAGING PERFORMED BY

A. Rodriguez

## HOSPITAL NAME

Foxfield VS

## REFERRING VET

A. Rodriguez

## INVOICE

16693

## DATE

8/2/22

## Cardiac Presentation

The echocardiogram in this patient demonstrated normal **left atrial** size based on 3 separate LA measurements. The cranial and caudal **mitral** valve leaflets presented normal linear structure and kinetics. A minor amount of left ventricular remodeling noted and slight hypertrophy. The **myocardium** presented normal echogenicity without subjective evidence of significant fibrotic or ischemic disease. **Contractility** of the ventricular walls was adequate and in normal range for this patient evidenced by the fractional shortening measurement and subjective evaluation of the different regions and angles of the myocardium. The **left ventricular outflow** tract demonstrated normal laminar flow and subjective structural integrity. The **right atrium** and auricle revealed normal size, structure and content. No evidence of masses was noted or chamber overload. **Tricuspid** valvular assessment demonstrated adequate linear morphology and kinetics. The **right ventricle** was of normal size (1/3 diameter of LV), chordae structure, myocardial echogenicity and thickness. **Pulmonic** tract assessment revealed normal valve structure, laminar flow, and diameter (approx.1:1 pa/ao ratio). No visible **pericardial** or free pleura fluid was noted or extra cardiac pathology in the visible planes. The cranial **mediastinum and pericardial regions** were free of masses in the visible window.

## Urinary System

The **urinary bladder**, trigone, and pelvic urethra presented normal thicknesses and normal tone. The ureters were not visible which is normal. No uroliths or sediment were visualized and anechoic urine was present. No evidence of inflammatory or neoplastic changes were noted. Ureteral papillae were normal.



**PATIENT**

Notte Kinsley

**SPECIES**

Feline

**BREED**

Main Coon

**SEX**

Neutered Male

**AGE**

16 Years

**WEIGHT**

14 Pounds

**INTERPRETED BY**

Eric Lindquist, DMV  
DABVP, Cert. IVUSS

**IMAGING  
PERFORMED BY**

A. Rodriguez

**HOSPITAL NAME**

Foxfield VS

**REFERRING VET**

A. Rodriguez

**INVOICE**

16693

**DATE**

8/2/22

The **kidneys** presented a relatively uniform cortical hyperechogenicity when compared to the renal medulla, spleen and liver. No overt masses were noted. Corticomedullary definition was nebulous and the ratio favored the cortex slightly. The ureters were not visible and assumed to be normal. These changes are most consistent with chronic interstitial nephritis yet infiltrative disease could not be entirely ruled out without biopsy though neoplasia is not suspected. This is a moderate change. The left kidney measured 4.17 cm. Cortical infarcts and remodeling were noted in the left kidney. Severe dystrophic changes and infarcts were noted in the right kidney. The right kidney measured 3.4 cm. Blood flow to the kidneys was subjectively subnormal.

**Adrenal Glands**

Both **adrenal glands** were visualized and recognized as having normal shape, size, position and echogenicity for this breed. The phrenic vasculature, glandular echogenicity and detail were unremarkable. Capsule, cortex, and medullary definition were normal for this age patient. The left adrenal gland measured 0.41 cm. The right adrenal gland measured 0.43 cm.

**Spleen**

The **spleen** presented a smooth homogeneous parenchyma hyperechoic to liver and renal cortical parenchyma. The capsule was smooth without noticeable expansion or deviation from within the spleen or adjacent pathology. The splenic vasculature demonstrated normal volume without signs of congestion or thrombosis. No sonographic evidence of acute or chronic inflammatory, neoplastic, or infarctual changes were noted.

**Liver**

The **liver** parenchyma was uniformly hyperechoic to falciform fat without disruption of architecture. No masses were noted. The gall bladder and common bile duct were unremarkable. This presentation is most consistent with hepatic lipidosis with the minor potential for underlying lymphoma or inflammatory hepatopathy. The potential for these latter pathologies would be based on hepatic enzyme elevations and clinical profile. A 25-gauge US-guided FNA is warranted if any elevation in SAP or bilirubin is present or if anorexia is present to assess cytological disease (lipidosis or round cell neoplasia). Biopsy is warranted if an elevation in ALT is present to assess hepatic portal infrastructure yet should be done with caution owing to parenchymal fragility in these presentations. This is a mild change.

**Gastrointestinal**

Examination of the **gastrointestinal tract** revealed a stomach and intestine free of stasis, of normal wall thickness, acceptable curvilinear mural detail, and peristaltic activity. Small and large intestine demonstrated normal luminal chyme and stool consistency respectively. No obstructive or overt infiltrative disease was noted. No associated abnormal lymphatic activity was noted.

**Pancreas**

The base and limbs of the **pancreas** were observed to be largely isoechoic to surrounding omental fat. Pancreatic duct and capsular contour were acceptably normal and parenchyma respected normal curvilinear patterns. No overt evidence of active inflammatory or neoplastic disease was noted.

**Free Abdomen**

The mesenteric **lymph nodes** were slightly enlarged.



**PATIENT**

Notte Kinsley

**SPECIES**

Feline

**BREED**

Main Coon

**SEX**

Neutered Male

**AGE**

16 Years

**WEIGHT**

14 Pounds

**INTERPRETED BY**

Eric Lindquist, DMV  
DABVP, Cert. IVUSS

**IMAGING PERFORMED BY**

A. Rodriguez

**HOSPITAL NAME**

Foxfield VS

**REFERRING VET**

A. Rodriguez

**INVOICE**

16693

**DATE**

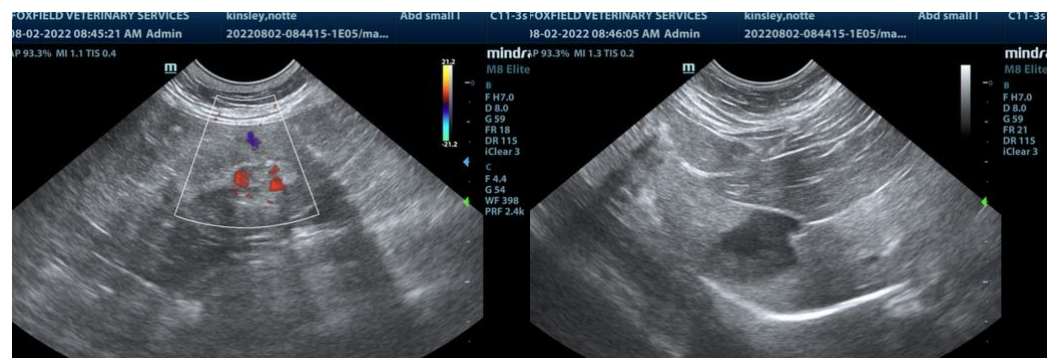
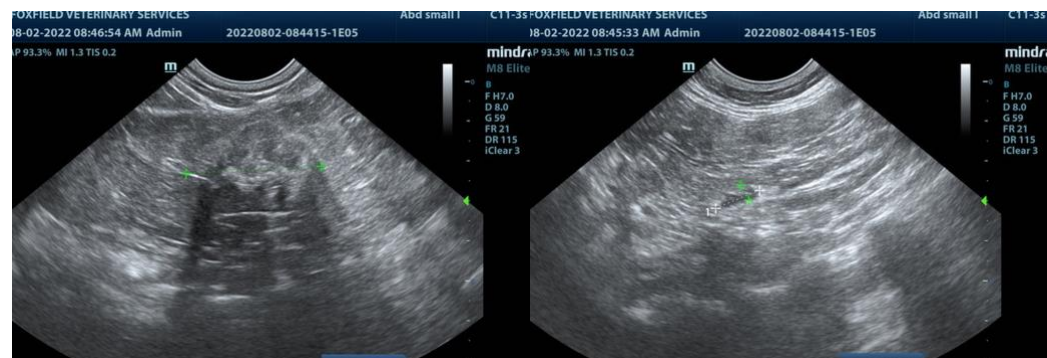
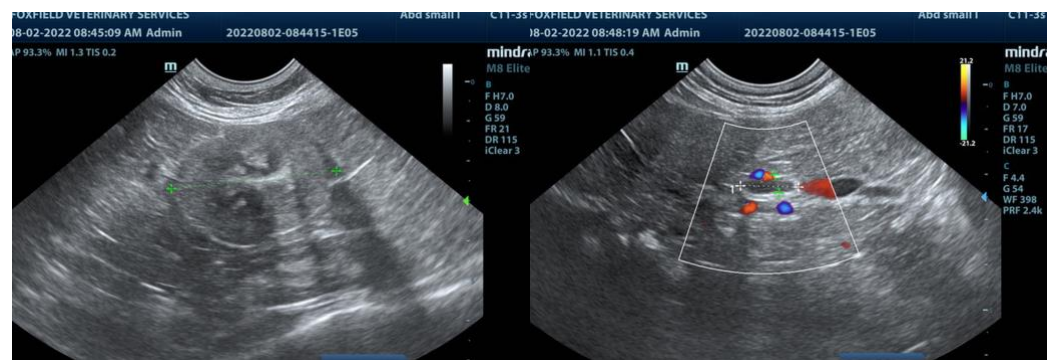
8/2/22

**ULTRASONOGRAPHIC FINDINGS**

- Severe renal dystrophy in the right kidney and moderate in the left kidney- Subjectively near end stage degenerative renal disease.
- Minor left ventricular hypertrophy- not clinically significant

**INTERPRETATION OF THE FINDINGS & FURTHER RECOMMENDATIONS**

BUN, creatinine, urine specific gravity, inflammatory sediment and urine should all be monitored carefully, as well as blood pressure measurements. No contraindication to anesthetic procedure. Torbutrol (premed), propofol (induction), and isoflurane (maintenance) is suggested.





**PATIENT**

Notte Kinsley

**SPECIES**

Feline

**BREED**

Main Coon

**SEX**

Neutered Male

**AGE**

16 Years

**WEIGHT**

14 Pounds

**INTERPRETED BY**

Eric Lindquist, DMV  
DABVP, Cert. IVUSS

**IMAGING PERFORMED BY**

A. Rodriguez

**HOSPITAL NAME**

Foxfield VS

**REFERRING VET**

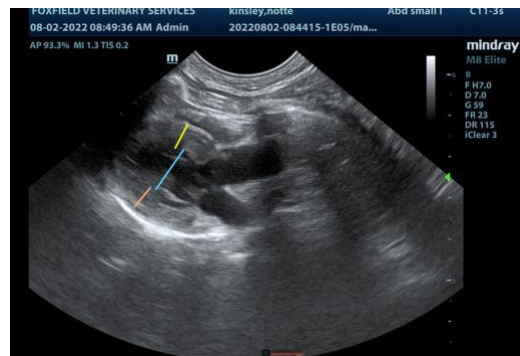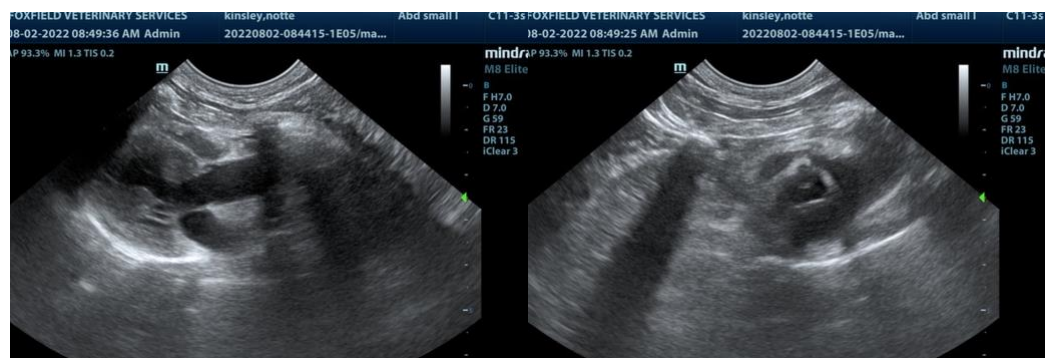
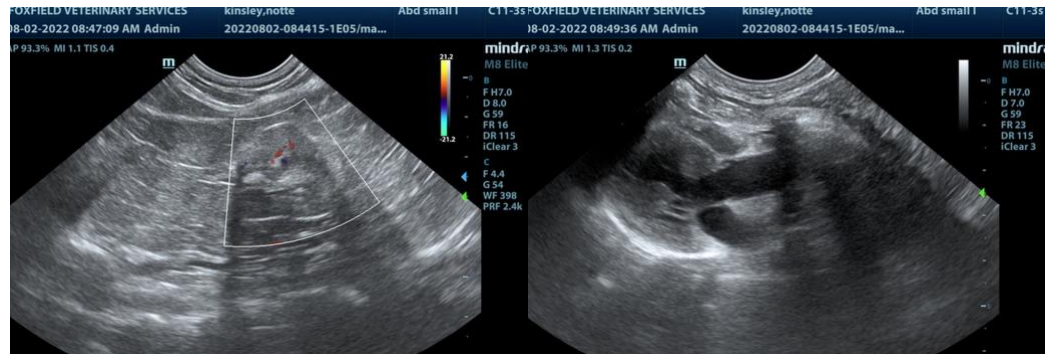
A. Rodriguez

**INVOICE**

16693

**DATE**

8/2/22



The information and recommendations provided are based on the images presented by the referring veterinarian. No evaluation can be communicated regarding pathology that was not visible in the image/video clips provided.

Thank you for this referral. If the clinical or image interpretation does not parallel your findings or if I can be of any further assistance please contact me.

**Eric Lindquist**, DMV, DABVP, Cert. IVUSS, CEO of SonoPath.com  
info@SonoPath.com