


PATIENT PRESENTING CLINICAL SIGNS

Zooney Kim History: 6 month recheck of valvular disease

SPECIES

Canine

Abnormal PE/Chem/CBC/UA Results: Current Medications 1.25mg Vetmedin q12h, 1/3 12.5mg furosemide PO q24h, 1.25mg enalapril q24h

ULTRASONOGRAPHIC EXAMINATION OF THE HEART
BREED

Rat Terrier

SEX

Spayed Female

AGE

14 Years

WEIGHT

9.7 Pounds

CANINE CARDIAC PARAMETERS	MR VMAX (m/s)	TR VMAX (m/s)	LA/AO (Boon method)	LA/AO (Heart Base; Swe)	FS (%)	EF (%)	EPSS (cm)
NORMAL PARAMETER	4.5-5.5	<2.7	1.3	<1.3	28-40	40-100	<0.6
PATIENT	5.30	2.5	NM	2.4	59	90	NM
CANINE CARDIAC PARAMETERS	HR (BPM)	AV VMAX (m/s)	PV MAX (m/s)	BODY WEIGHT (kg)	LA 2D short axis Base view (cm)	LVIDd Avg; 2D and m-mode short axis (cm)	LVIDs Avg; 2D and m-mode short axis (cm)
NORMAL PARAMETER	50-100	0.7-1.7	0.7-1.6				
PATIENT	130	1.50	.69	--	3.55	3.23	--

INTERPRETED BY

Eric Lindquist, DMV, DABVP, Cert. IVUSS

IMAGING PERFORMED BY

Sara Hansen

HOSPITAL NAME

Edgewood AC

REFERRING VET

Dr. Kimball

DATE

8/19/22

Invoice

16915

Cardiac Presentation

The cardiac presentation in this patient presented moderate persistent volume overload of the left ventricle and left atrium. Mitral and tricuspid insufficiency were present. No pericardial or pleural effusion noted. Prolapse of the anterior mitral valve leaflet noted. This is partially compensated C-1 valvular disease. Hepatic veins were not dilated.

ULTRASONOGRAPHIC FINDINGS

- Partially compensated C-1 valvular disease

INTERPRETATION OF THE FINDINGS & FURTHER RECOMMENDATIONS

I recommend refining therapy by increasing enalapril to 0.5 mg/kg BID and adding Spironolactone at 1-2 mg/kg BID. Sleeping respiratory rate of <25 per minute. Recheck in 3-6 months, depending upon clinical progression. BUN, creatinine and blood pressures should all be monitored 7-10 days post medications.



PATIENT

Zooley Kim

SPECIES

Canine

BREED

Rat Terrier

SEX

Spayed Female

AGE

14 Years

WEIGHT

9.7 Pounds

INTERPRETED BY

Eric Lindquist, DMV,
DABVP, Cert. IVUSS

IMAGING PERFORMED BY

Sara Hansen

HOSPITAL NAME

Edgewood AC

REFERRING VET

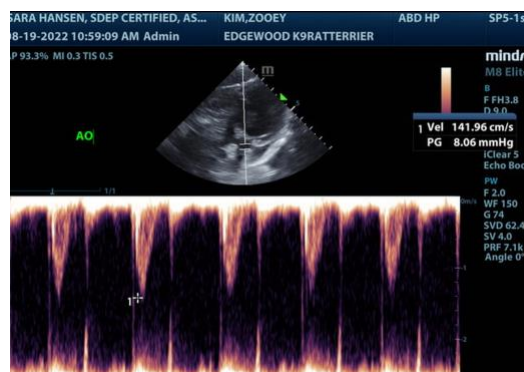
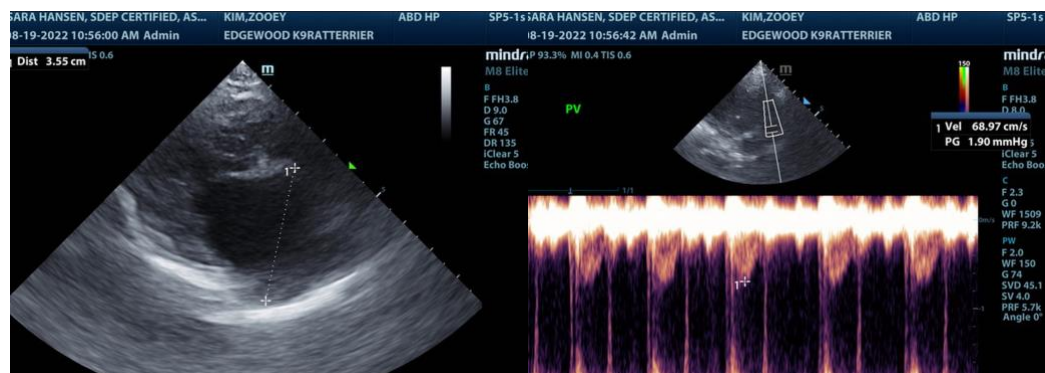
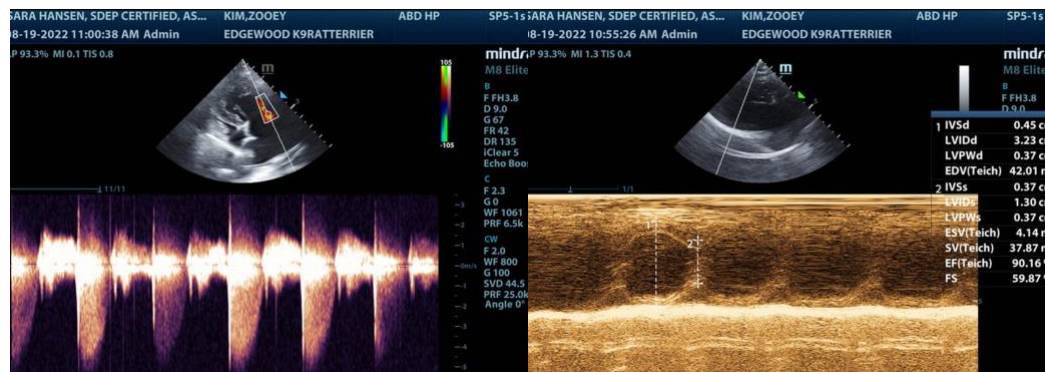
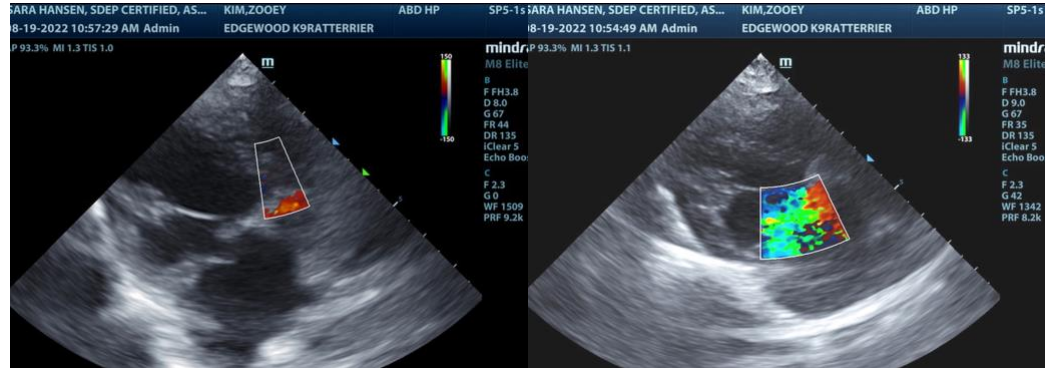
Dr. Kimball

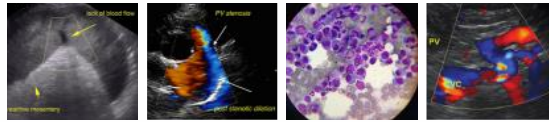
DATE

8/19/22

Invoice

16915





PATIENT

Zooley Kim

The information and recommendations provided are based on the images presented by the referring veterinarian/sonographer. No evaluation can be communicated regarding pathology that was not visible in the image/video clips provided.

SPECIES

Canine

Thank you for this referral. If the clinical or image interpretation does not parallel your findings or if I can be of any further assistance please contact me.

BREED

Rat Terrier

Eric Lindquist, DMV, DABVP, Cert. IVUSS

CEO of Sonopath.com

Eric.Lindquist@SonoPath.com

SEX

Spayed Female

AGE

14 Years

WEIGHT

9.7 Pounds

INTERPRETED BY

Eric Lindquist, DMV,
DABVP, Cert. IVUSS

**IMAGING
PERFORMED BY**

Sara Hansen

HOSPITAL NAME

Edgewood AC

REFERRING VET

Dr. Kimball

DATE

8/19/22

Invoice

16915