



PATIENT

Tyson Rackham

SPECIES

Canine

BREED

American Staffordshire
Mix

SEX

Neutered male

AGE

9 years

WEIGHT

67 lbs

INTERPRETED BY

Eric Lindquist, DMV
DABVP, Cert. IVUSS

**IMAGING
PERFORMED BY**

Dr. Kitz

HOSPITAL NAME

Woodlands AH

REFERRING VET

Dr. Kitz

INVOICE

32432

DATE

8/19/22

PRESENTING CLINICAL SIGNS

History: Patient presented after a ten day duration of anorexia, drinking and urinating excessively, and some vomiting.

Abnormal PE/Chem/CBC/UA Results: On presentation, Tyson was depressed, and had a temperature of 104.5. He had a new Grade I murmur. He had lost over ten pounds. CBC showed WBC of 25k with neutrophilia Chem showed elevated creatinine at 2.3 and hypokalemia. Urinalysis showed USG of 1.012 and significant sediment with TNTC RBCs and WBCs. Radiographs of chest and abdomen - three view - submitted for review - no specific abnormalities other than some possible striated soft tissue opacity foreign material in the stomach. Urine culture submitted to the lab has already come back with First Trac positive for bacterial growth. Patient was improved following 2x maintenance IV fluids throughout the day, and IV Unasyn started following collection of urine for culture. He is current on Leptospirosis vaccination.

ULTRASONOGRAPHIC EXAMINATION OF THE ABDOMEN

Urinary System

The **urinary bladder**, trigone, and pelvic urethra presented normal thicknesses and normal tone. The pelvic urethra was imaged 3.0 cm beyond the cystourethral junction and appeared normal. The ureters were not visible which is normal. No uroliths or sediment were visualized and anechoic urine was present. No evidence of inflammatory or neoplastic changes was noted. Ureteral papillae were normal.

The residual prostate measured

The **kidneys** revealed normal size and structure, corticomedullary definition and ratio for this age. The cortices presented largely uniform texture with normal echogenic relationship to liver and spleen. Medullary structure differed distinctly from the cortex. The capsules were acceptably uniform without significant irregularities. The left kidney measured 7.5 cm. The right kidney measured 8.05 cm with trace pyelectasia.

Adrenal Glands

Both **adrenal glands** were visualized and recognized as having normal shape, size, position and echogenicity for this breed. The phrenic vasculature, glandular echogenicity and detail were unremarkable. Capsule, cortex, and medullary definition were normal for this age patient. The left adrenal gland measured 0.82 cm. The right adrenal gland measured 0.6 cm at the cranial pole and 0.4 cm at the caudal pole.

Spleen

The **spleen** in this patient was mildly enlarged with subtle, heterogenous parenchymal changes. The spleen was folded upon itself caudally. This is a positional variant and is not pathological. There was no evidence of significant disease.

Liver

The **liver** images submitted revealed subjectively normal liver size, contour, and structure. Parenchymal echogenicity was naturally coarse and hypoechoic to the spleen. Vascular and biliary tracts were of normal volume with no evidence of congestion. The gallbladder presented acceptably thin walls with



PATIENT

Tyson Rackham

primarily anechoic content. The cystic and common bile ducts were normal. No pathological hepatic lymphadenopathy was evident. No overt structural evidence of inflammatory, infiltrative or regenerative pathology was evident.

SPECIES

Canine

Gastrointestinal

Examination of the **gastrointestinal tract** revealed a stomach and intestine free of stasis, of normal wall thickness, acceptable curvilinear mural detail, and peristaltic activity. Small and large intestine demonstrated normal luminal chyme and stool consistency respectively. No obstructive or overt infiltrative disease was noted. No associated abnormal lymphatic activity was noted.

BREED

American Staffordshire
Mix

SEX

Neutered male

Pancreas

The base and limbs of the **pancreas** were observed to be largely isoechoic to surrounding omental fat. Pancreatic duct and capsular contour were acceptably normal and parenchyma respected normal curvilinear patterns. No overt evidence of active inflammatory or neoplastic disease was noted.

AGE

9 years

ULTRASONOGRAPHIC FINDINGS

Structurally unremarkable abdomen.

WEIGHT

67 lbs

INTERPRETATION OF THE FINDINGS & FURTHER RECOMMENDATIONS

INTERPRETED BY

Eric Lindquist, DMV
DABVP, Cert. IVUSS

There was no evidence of pathology.

Maldigestion panel, three view chest radiographs and full CNS examination is recommended to examine for occult disease that could be responsible for the weight loss. Evaluation for competitive eating environments should also be considered.

IMAGING PERFORMED BY

Dr. Kitz

HOSPITAL NAME

Woodlands AH

REFERRING VET

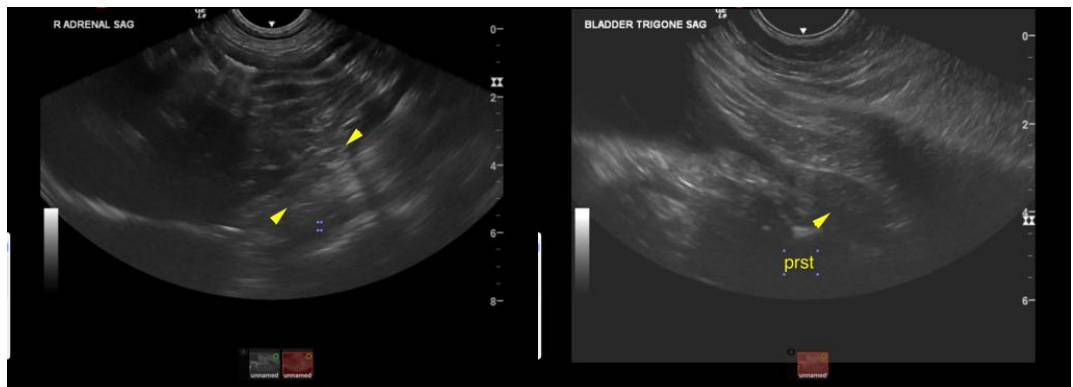
Dr. Kitz

INVOICE

32432

DATE

8/19/22





PATIENT

Tyson Rackham

SPECIES

Canine

BREED

American Staffordshire
Mix

SEX

Neutered male

AGE

9 years

WEIGHT

67 lbs

INTERPRETED BY

Eric Lindquist, DMV
DABVP, Cert. IVUS

**IMAGING
PERFORMED BY**

Dr. Kitz

HOSPITAL NAME

Woodlands AH

REFERRING VET

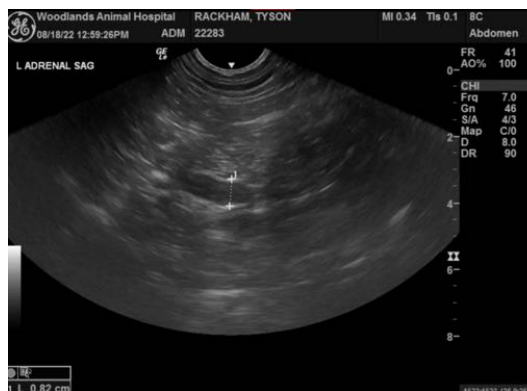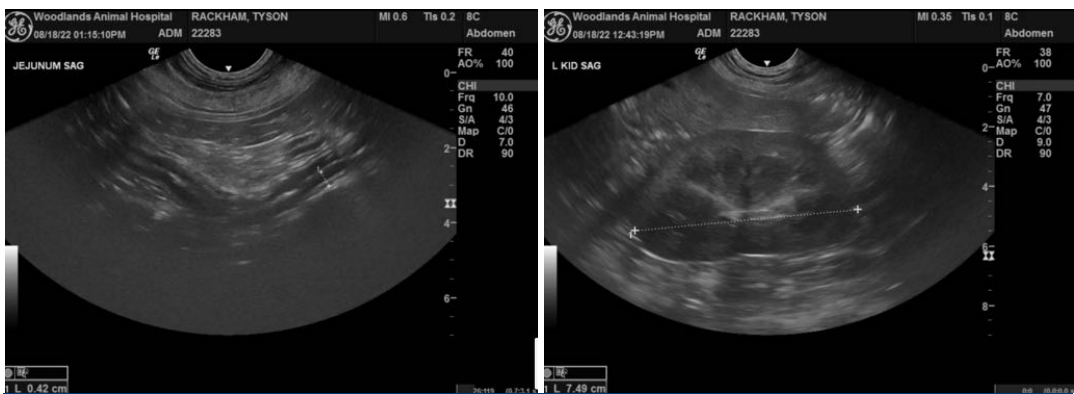
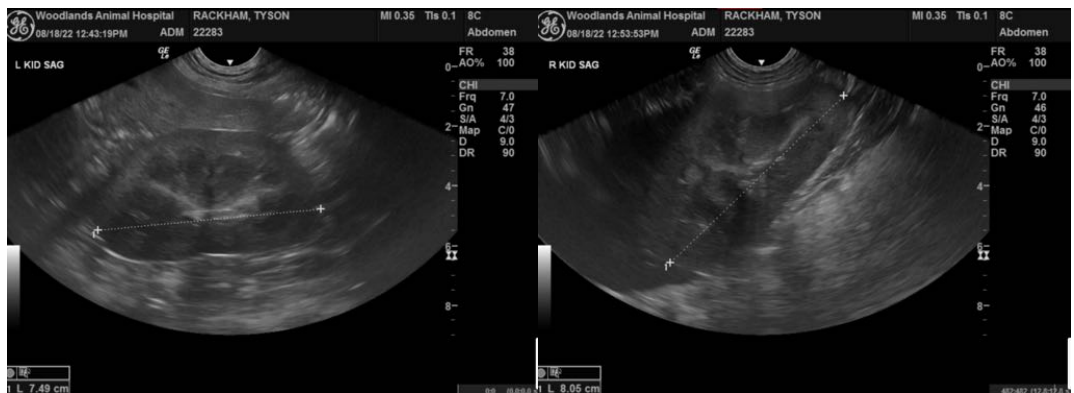
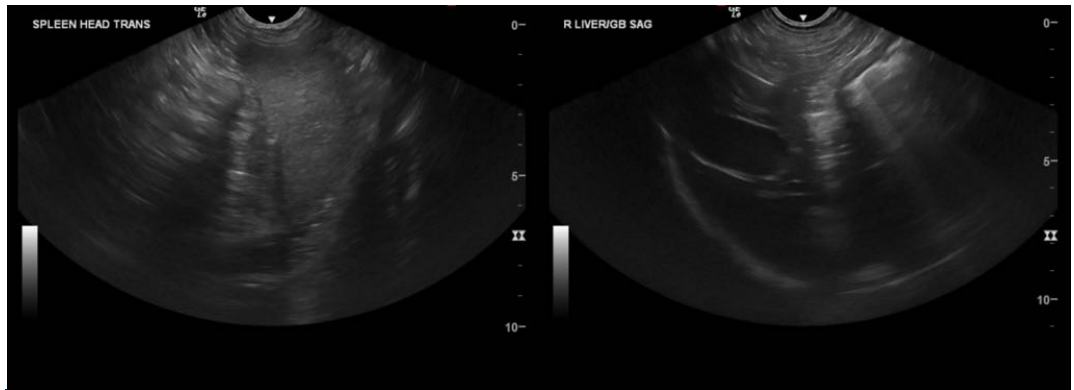
Dr. Kitz

INVOICE

32432

DATE

8/19/22





PATIENT

Tyson Rackham

The information and recommendations provided are based on the images presented by the referring veterinarian/sonographer. No evaluation can be communicated regarding pathology that was not visible in the image/video clips provided.

SPECIES

Canine

Thank you for this referral. If the clinical or image interpretation does not parallel your findings or if I can be of any further assistance please contact me.

BREED

American Staffordshire
Mix

Eric Lindquist, DMV, DABVP, Cert. IVUSS, CEO of SonoPath.com
info@SonoPath.com

SEX

Neutered male



The following is an applicable excerpt from the *Curbside Guide to Diagnosis and Treatment of Sonographic Disease* offered by [SonoPath.com](http://sonopath.com) Lindquist, Fra Lobetti, and Modler.

AGE

9 years

An essential quick guide for every general practitioner and sonographer.

<https://sonopath.com/products/curbside-guide-editing-due-release-1201201>

WEIGHT

67 lbs

Fever of Unknown Origin

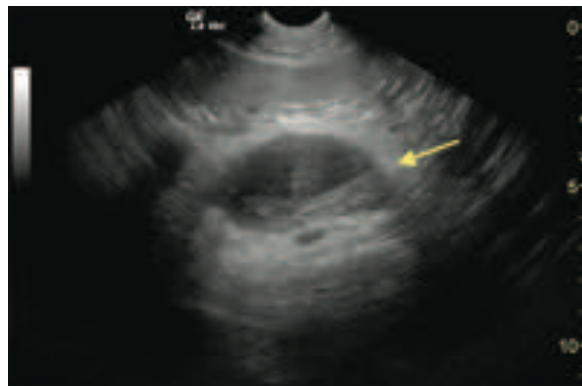
<http://www.sonopath.com/FUO>

INTERPRETED BY

Eric Lindquist, DMV
DABVP, Cert. IVUSS

IMAGING PERFORMED BY

Dr. Kitz



Long axis of the mid-abdomen in a dog with an omental abscess after foreign body penetration from the gastrointestinal tract. The hypoechoic necrotic center of the lesion is surrounded by a thick echogenic capsule and hyperechoic mesenteric fat (arrow) indicating focal peritonitis. The linear echogenic needle (5 cm depth) is barely visible owing to the density of the purulent material contained within the abscess.

HOSPITAL NAME

Woodlands AH

REFERRING VET

Dr. Kitz

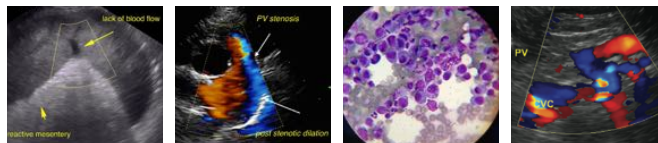
INVOICE

32432

Description: The definition of a fever of unknown origin (FUO) has not been clearly defined for animals. Currently, it is either understood to be a fever that does not resolve within the period one would expect for a “self-limiting infection” being treated with appropriate antimicrobial therapy, or that for which an underlying diagnosis has not been determined despite considerable diagnostic effort. The common causes of FUO were summarized concisely in a presentation at the American College of Veterinary Internal Medicine 2004 Forum. The presenters synthesized information from three veterinary papers on the subject, which suggested the following:

DATE

8/19/22



PATIENT

Tyson Rackham

SPECIES

Canine

BREED

American Staffordshire
Mix

SEX

Neutered male

AGE

9 years

WEIGHT

67 lbs

INTERPRETED BY

Eric Lindquist, DMV
DABVP, Cert. IVUSS

IMAGING PERFORMED BY

Dr. Kitz

HOSPITAL NAME

Woodlands AH

REFERRING VET

Dr. Kitz

INVOICE

32432

DATE

8/19/22

| | Final Diagnosis | Bennett (dogs & cats) | Dunn and Dunn (dogs only) | Lunn (dogs & one cat) | Total |
|--|----------------------------|-----------------------|---------------------------|-----------------------|------------|
| | Infection | 21 | 16 | 10 | 47 |
| | Immune | 18 | 22 | 6 | 46 |
| | Bone marrow disease | 4 | 22 | 2 | 28 |
| | Neoplasia (outside marrow) | 0 | 10 | 2 | 12 |
| | Miscellaneous | 2 | 12 | 2 | 16 |
| | No diagnosis | 0 | 19 | 2 | 21 |
| | TOTALS | 45 | 101 | 24 | 170 |

The types of infection diagnosed in this case series were varied, ranging from discospondylitis (8 cases), blastomycosis (6), and bacterial endocarditis (4), to leishmaniasis (1), prostatitis (1), and *Ehrlichia canis* infection (1); a multitude of other infectious causes also fell within the spectrum. Of the cases in which immune-mediated disease was found, 44% had immune-mediated polyarthritis. Bone marrow diseases included myeloproliferative disease, myelodysplasia (8), lymphocytic leukemia (8), myeloma (3), chronic granulocytic leukemia (3), lymphoblastic leukemia, and malignant histiocytosis. The types of neoplasia located outside the bone marrow included lymphoma (6), metastatic disease (2), and neoplasms of the lung, spleen, and stomach. Finally, miscellaneous diseases included hypertrophic osteodystrophy (6), meningitis (3), portosystemic shunt (3), lymphadenitis (2), panosteitis, and intervertebral disc disease. Overall, the most common causes across all cases were polyarthritis (44), lymphoid neoplasia (15), discospondylitis (8), myelodysplasia (8), hypertrophic osteodystrophy (6), and blastomycosis (6).

Clinical Signs: Animals usually present with either persistent or waxing and waning fevers ranging from 103°F to 106°F. Other clinical signs depend on the underlying cause of the fever. Careful and thorough physical examination is required to assess potential causes.

Diagnostics: FOU etiologies are partly related to geography, and thus locale or travel history should factor into a practitioner's diagnostic approach. A patient's lifestyle may also provide clues regarding exposure to certain etiologic agents. Therefore, conducting a thorough history can unveil important pieces of the diagnostic puzzle. Physical examination is especially important and should include an inspection of all accessible lymph nodes, palpation and movement of the joints, a fundic examination, a neurological evaluation, spinal and limb palpation and range of motion tests, and a rectal examination.



PATIENT

Tyson Rackham

SPECIES

Canine

BREED

American Staffordshire
Mix

SEX

Neutered male

AGE

9 years

WEIGHT

67 lbs

INTERPRETED BY

Eric Lindquist, DMV
DABVP, Cert. IVUSS

IMAGING PERFORMED BY

Dr. Kitz

HOSPITAL NAME

Woodlands AH

REFERRING VET

Dr. Kitz

INVOICE

32432

DATE

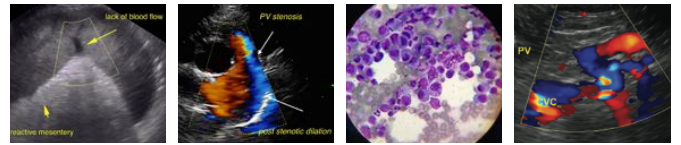
8/19/22

A minimum database should include a CBC reviewed by a clinical pathologist, as well as a biochemical profile and urinalysis. Retroviral testing should also be considered in cats. In areas where tick-borne disease is prevalent, in-house testing should be performed early. Advanced laboratory work can include: urine culture, blood culture, and infectious disease panels (PCR and/or serology). In dogs, one may screen for the following infectious agents: *Ehrlichia* spp., *Borrelia burgdorferi*, Rock Mountain Spotted Fever, *Bartonella* spp. (culture and PCR), and *Leptospira* spp. in cases of hepatic or renal involvement. In cats, one should evaluate for FeLV, FIV, feline infectious peritonitis (FIP) virus, toxoplasmosis, *Hemoplasma* spp. (*Mycoplasma*), and *Bartonella* spp. (culture and PCR). Testing for *Ehrlichia* spp., *Rickettsia* spp., and *Anaplasma phagocytophilum* can also be considered. A fungal assay is indicated if the patient lives in or has had exposure to a region with a higher incidence of fungal disease. Other infectious disease tests may be performed depending on the geographical location of the pet. Screening for *Brucella* should be done in breeding dogs. Immune-mediated disease screening can include a Coomb's test, a slide agglutination test (if the patient is anemic), and an antinuclear antibody (ANA) test. Immune disease is often a diagnosis of exclusion.

Imaging should include thoracic radiographs, abdominal ultrasound, and/or abdominal radiographs. Ultrasound can be very useful for assessing evidence of cholangiohepatitis, pyelonephritis, chronic urinary tract infection, abscess formation, peritonitis, and neoplasia; it also permits an examination of the intra-abdominal lymph nodes. An echocardiogram can offer assessment for vegetative endocarditis, whereas spinal radiographs offer assessment for discospondylitis. In cases where all other testing has proven negative and the patient has not responded to broad-spectrum antibiotics and supportive care, arthrocentesis should be considered to evaluate for septic joint disease, immune-mediated polyarthritis, and infectious disease. Finally, one can consider assessing the cerebrospinal fluid for meningoencephalitis, GME, and meningitis/arteritis. A bone marrow exam should be performed if blood dyscrasias are noted on the CBC.

Treatment: Treatment of the fever depends entirely on the underlying cause. Ideally, a thorough diagnostic plan will yield a diagnosis that will guide the appropriate therapeutic course. However, if an exhaustive approach has not produced a definitive diagnosis and there is no response to broad-spectrum antibiotics, trial therapy with immunosuppressive agents such as prednisolone can be considered to treat presumed immune-mediated diseases. Given the potential for negative sequelae should an underlying infection be present, one must be certain that the investigation is thorough and monitor the patient's response carefully.

Conclusion: If a documented fever has not responded to antibiotics, antipyretics, or general nursing care, it is important to obtain a diagnosis to guide more specific treatment. A systematic physical examination and thorough history-taking will help inform further diagnostics in addition to what is revealed by the minimum database.



PATIENT

Tyson Rackham

SPECIES

Canine

BREED

American Staffordshire
Mix

SEX

Neutered male

AGE

9 years

WEIGHT

67 lbs

INTERPRETED BY

Eric Lindquist, DMV
DABVP, Cert. IVUSS

**IMAGING
PERFORMED BY**

Dr. Kitz

HOSPITAL NAME

Woodlands AH

REFERRING VET

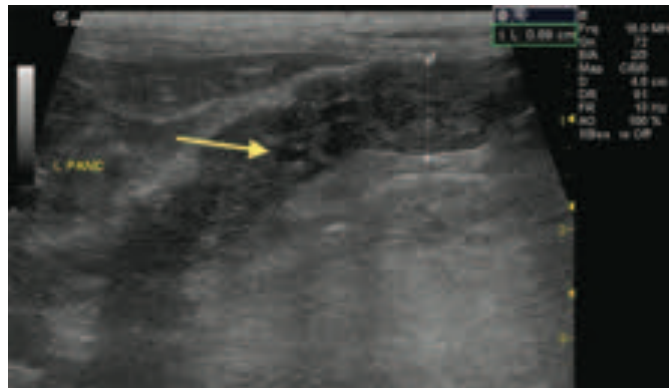
Dr. Kitz

INVOICE

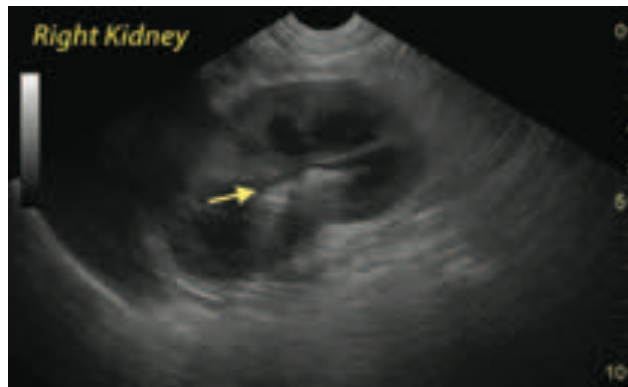32432

DATE

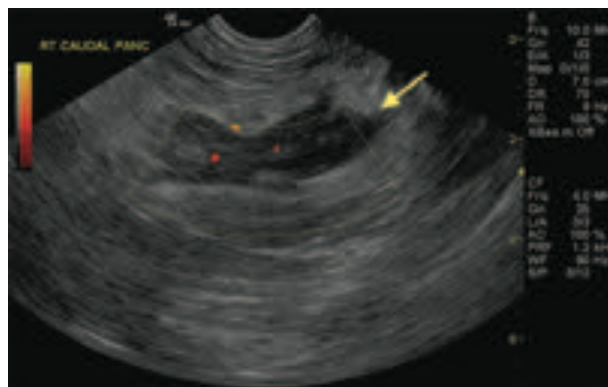
8/19/22



Long axis of the left pancreatic limb (between calipers) in a cat with pancreatitis after undergoing a renal transplant. Note the decrease in echogenicity and mild loss of regular echotexture of the swollen and irregularly contoured pancreas. Also note the mild dilation of the pancreatic duct (arrow). Focal peritonitis is evident by increased echogenicity and loss of the linear echotexture of the surrounding mesentery.



Long axis of the right kidney in a dog with pyelonephritis. Note the increased echogenicity and irregular outline of the renal crest and diverticuli and the mild dilation of the renal pelvis (arrow).

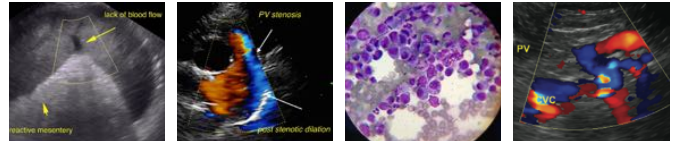


Long axis of the right pancreatic limb in a dog with acute pancreatitis. The swollen hypoechoic pancreas is embedded in hyperechoic mesenteric fat (arrow). Note the regional differences in blood flow intensity within the parenchyma as demonstrated by Power Doppler interrogation compatible with multifocal disruption of vascularization as a sequela of the severe inflammation.

References:

Bennet D. Diagnosis of pyrexia of unknown origin. *In Practice* 1995;17(10):470-81.

Dunn KJ, Dunn JK. Diagnostic investigations in 101 dogs with pyrexia of unknown origin. *J Sm Anim Pract* 1998;39(12):574-80.



PATIENT

Tyson Rackham

Flood J. The diagnostic approach to fever of unknown origin in cats. *Compend Contin Educ Vet* 2009;31(1):26-31.

SPECIES

Canine

Flood J. The diagnostic approach to fever of unknown origin in dogs. *Compend Contin Educ Vet* 2009;31(1):14-21.

BREED

American Staffordshire
Mix

Lappin MR. The role of blood borne pathogens in feline fever of unknown origin. Proceedings from the American College of Veterinary Internal Medicine, Denver, CO, June 15-18, 2011.

SEX

Neutered male

Lunn KF. Fever of unknown origin: a systematic approach to diagnosis. *Compend Contin Educ Vet* 2001;23(11):976-92.

Lunn KF. Fever of unknown origin: appropriate choice of diagnostic tests. Proceedings from the American College of Veterinary Internal Medicine, Minneapolis, MN, June 9-12, 2004.

AGE

9 years

WEIGHT

67 lbs

INTERPRETED BY

Eric Lindquist, DMV
DABVP, Cert. IVUSS

**IMAGING
PERFORMED BY**

Dr. Kitz

HOSPITAL NAME

Woodlands AH

REFERRING VET

Dr. Kitz

INVOICE

32432

DATE

8/19/22