

**DATE PRESENTING CLINICAL SIGNS**

8/19/22

History: Mass in abdomen- potentially associated with bladder.

PATIENT

Current Medications: None listed.

Date of Previous IntraPet Ultrasound: No previous.

Molly Ware

Sedation: Not required to complete full diagnostic ultrasound.

Stat Report: Not requested.

SPECIES

Imaging Performed By: Stephanie Warga RDCS, RVT.

Canine

ULTRASONOGRAPHIC EXAMINATION OF THE ABDOMEN**BREED****Urinary System**

King Charles Cavalier

A 9.0 cm mixed hypoechoic microcystic undifferentiated mass was noted in the caudal abdomen. The mass appears to be adjacent to the **urinary bladder**, as well as deviating the bladder, whether it derives from the bladder or possibly residual uterine stump is unclear (suspect uterine stump origin). FNA is warranted.

SEX

Spayed Female

The **kidneys** revealed largely normal size and structure, corticomedullary definition and ratio (cortex 1/3 of medulla) were essentially maintained with some moderate age-related loss of curvilinear patterns regarding the capsule and C/M junction. The cortices presented largely uniform texture with some increased echogenicity expected for his age patient. Medullary structure differed distinctly from that of the cortex and no evidence of pelvic dilation was present. The right kidney measured 4.7 cm. The left kidney measured 4.66 cm.

AGE

8/11/09

WEIGHT

23.5 Pounds

Adrenal Glands

Both **adrenal glands** were visualized and recognized as having normal shape, size, position and echogenicity for this breed. The phrenic vasculature, glandular echogenicity and detail were unremarkable. Capsule, cortex, and medullary definition were normal for this age patient. The right adrenal gland measured 1.85 cm x 0.55 cm at the caudal pole and 0.55 cm at the cranial pole. The left adrenal gland measured 2.5 cm x 0.73 cm at the caudal pole and 0.56 cm at the cranial pole.

INTERPRETED BYEric Lindquist, DMV
DABVP, Cert. IVUS**Spleen**The **spleen** in this patient was uniform, yet volume contracted. Hydration status should be assessed.**HOSPITAL NAME**

Homeward Bound VS

LiverThe **liver** was mildly enlarged with a hypoechoic partially undifferentiated nodule (2.1 cm) in the left cranial liver. The nodular change in the liver may represent a metastatic lesion. The gallbladder and common bile duct were unremarkable.**REFERRING VET**

Dr. Vance

Gastrointestinal

Examination of the **gastrointestinal tract** revealed a stomach and intestine free of stasis, of normal wall thickness, acceptable curvilinear mural detail, and peristaltic activity. Small and large intestine demonstrated normal luminal chyme and stool consistency respectively. No obstructive or overt infiltrative disease was noted. No associated abnormal lymphatic activity was noted.

INVOICE

16928

Pancreas

The base and limbs of the **pancreas** were observed to be largely isoechoic to surrounding omental fat. Pancreatic duct and capsular contour were acceptably normal and parenchyma respected normal curvilinear patterns. No overt evidence of active inflammatory or neoplastic disease was noted.

Free Abdomen

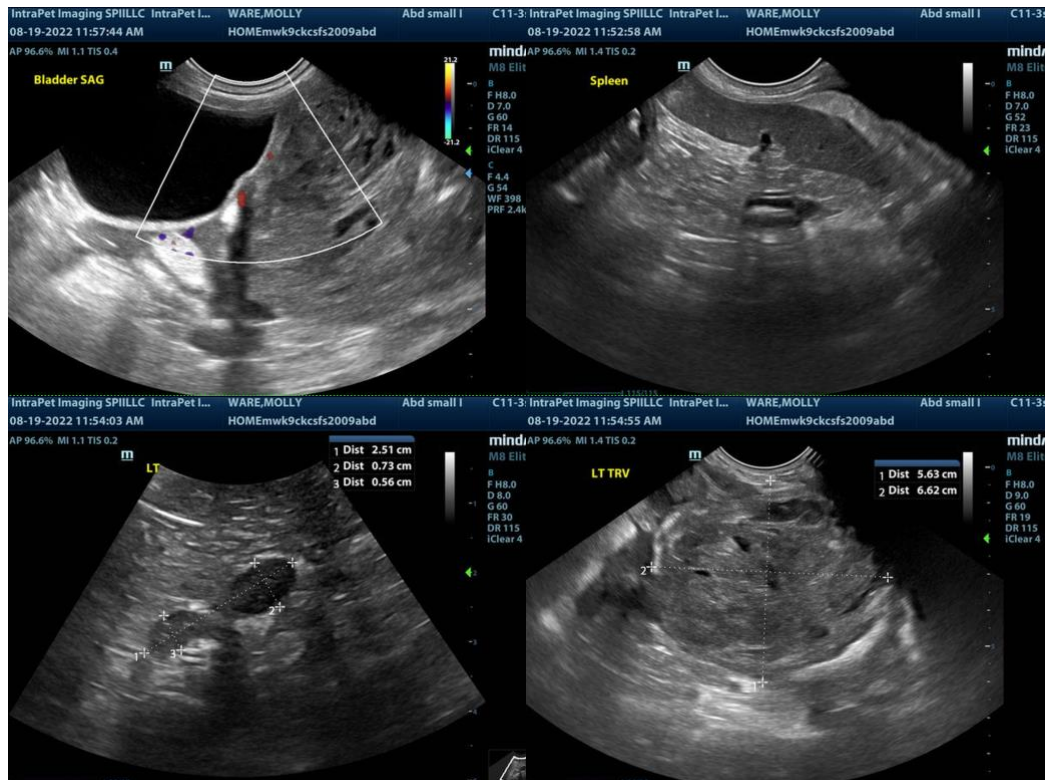
Free fluid was noted in the abdomen between the liver lobes and the caudal mass. Echogenic free fluid noted in the abdomen is likely secondary to the mass effect.

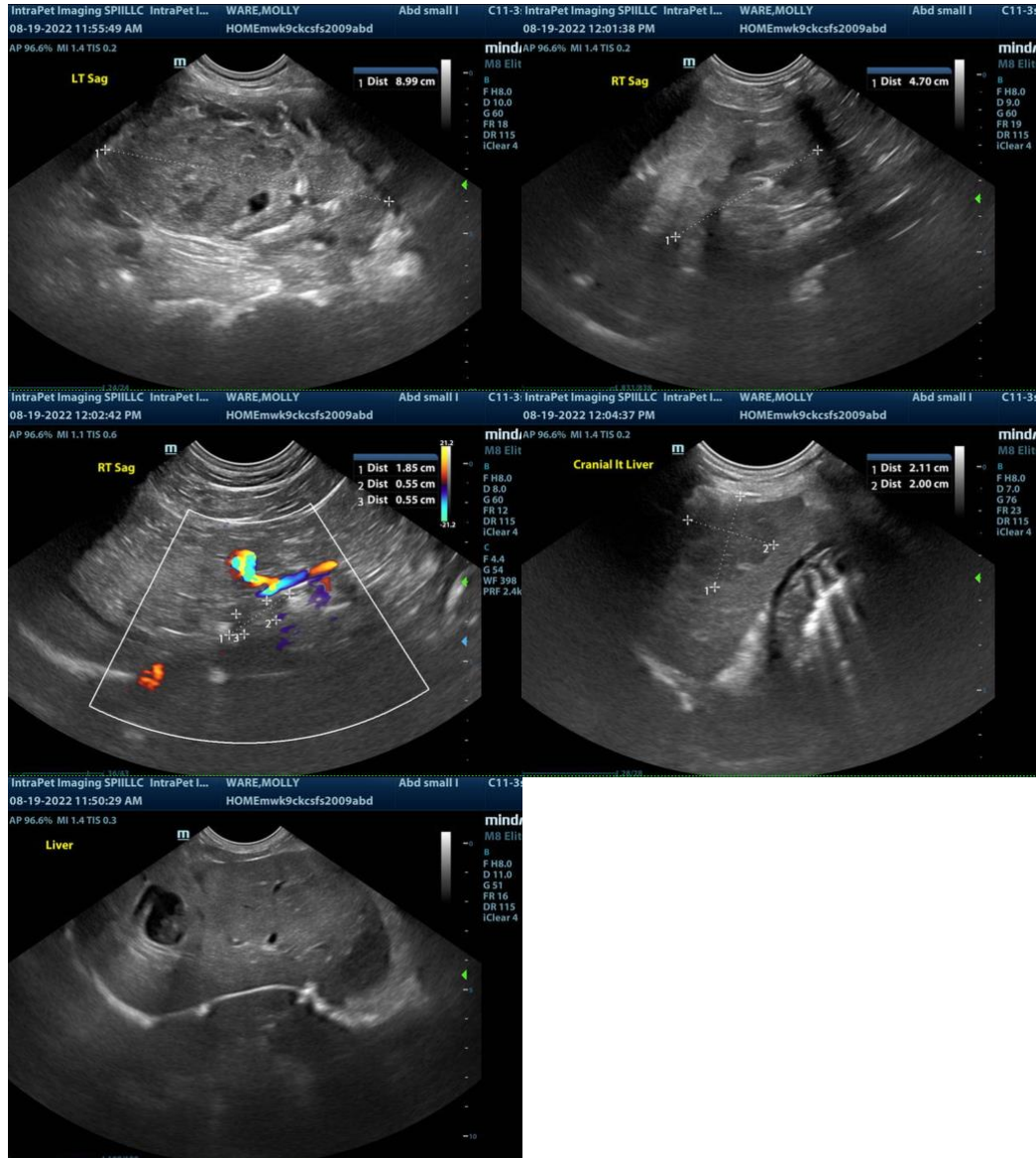
ULTRASONOGRAPHIC FINDINGS

- Mixed hypoechoic microcystic undifferentiated mass in the caudal abdomen, suspect uterine stump origin
- Liver, mildly enlarged with a hypoechoic partially undifferentiated nodule
- Free fluid
- Volume contracted spleen
- Age-related renal changes

INTERPRETATION OF THE FINDINGS & FURTHER RECOMMENDATIONS

FNA of the mass is warranted. The nodular changes in the liver may represent a metastatic lesion. Echogenic free fluid noted in the abdomen is likely secondary to the mass effect. Prognosis is guarded to poor depending upon cytology results. CT evaluation to evaluate the extent of the mass with relation to the pelvic inlet would be ideal, however, the mass deviates the urinary bladder and extends into the pelvic inlet.





The information and recommendations provided are based on the images presented by the referring veterinarian. No evaluation can be communicated regarding pathology that was not visible in the image/video clips provided.

Thank you for this referral. If the clinical or image interpretation does not parallel your findings or if I can be of any further assistance please contact me.

Eric Lindquist, DMV, DABVP, Cert. IVUSS, CEO of SonoPath.com
 Eric.Lindquist@SonoPath.com