



**PATIENT**

Dino Galic

**SPECIES**

Canine

**BREED**

Pitbull

**SEX**

Spayed Female

**AGE**

1 Year

**WEIGHT**

49 Pounds

**INTERPRETED BY**

Eric Lindquist, DMV  
DABVP, Cert. IVUSS

**IMAGING PERFORMED BY**

Dr. Jennifer Todd

**HOSPITAL NAME**

Lambs Gap AH

**REFERRING VET**

Dr. Laura Campbell

**INVOICE**

16906

**DATE**

8/19/22

**PRESENTING CLINICAL SIGNS**

History: Dino is a one year old, FS, Pitbull with a history of chronic diarrhea. Trials of Provable probiotic and Hill's GI Biome food has not improved her symptoms. There is no vomiting, her appetite is normal. 7/15/22: CBC, Chemistry, T4 and resting cortisol were all normal. -normal cobalamin level -decreased Folate level=indicative of proximal small intestinal disease, consider folate supplementation -normal PLI -normal TLI

**ULTRASONOGRAPHIC EXAMINATION OF THE ABDOMEN**

**Urinary System**

The **urinary bladder**, trigone, and pelvic urethra presented normal thicknesses and normal tone. The ureters were not visible which is normal. No uroliths or sediment were visualized and anechoic urine was present. No evidence of inflammatory or neoplastic changes were noted. Ureteral papillae were normal. The pelvic urethra was imaged 3.0 cm beyond the cystourethral junction.

The **kidneys** revealed normal size and structure, corticomedullary definition and ratio for this age. The cortices presented largely uniform texture with normal echogenic relationship to liver and spleen. Medullary structure differed distinctly from the cortex and no evidence of pelvic dilation was present. The capsules were acceptably uniform without significant irregularities. The right kidney measured 5.96 cm. The left kidney measured 5.88 cm.

**Adrenal Glands**

Both **adrenal glands** were visualized and recognized as having normal shape, size, position and echogenicity for this breed. The phrenic vasculature, glandular echogenicity and detail were unremarkable. Capsule, cortex, and medullary definition were normal for this age patient. The left adrenal gland measured 2.27 cm x 0.42 cm at the cranial pole and 0.41 cm at the caudal pole. The right adrenal gland measured 2.24 cm x 0.8 cm at the cranial pole and 0.4 cm at the caudal pole.

**Spleen**

The **spleen** presented a smooth homogeneous parenchyma hyperechoic to liver and renal cortical parenchyma. The capsule was smooth without noticeable expansion or deviation from within the spleen or adjacent pathology. The splenic vasculature demonstrated normal volume without signs of congestion or thrombosis. No sonographic evidence of acute or chronic inflammatory, neoplastic, or infarctual changes were noted. Cranial folding of the spleen was noted, not pathological.

**Liver**

The **liver** images submitted revealed subjectively normal liver size, contour, and structure. Parenchymal echogenicity was naturally coarse and hypoechoic to the spleen. Vascular and biliary tracts were of normal volume with no evidence of congestion. The gallbladder presented acceptably thin walls with primarily anechoic content. The cystic and common bile ducts were normal. No pathological hepatic lymphadenopathy was evident. No overt structural evidence of inflammatory, infiltrative or regenerative pathology was evident.

**Gastrointestinal**

The **stomach** was filled with progressively shadowing luminal material, measuring approximately 5.0 cm with progressive sound beam attenuation. If the patient was NPO, foreign matter is likely. The



**PATIENT**

small intestine was spastic yet unremarkable otherwise. The foreign matter appears to be localized in the pylorus. No accordion pleating noted.

Dino Galic

**Pancreas**

**SPECIES**

The base and limbs of the **pancreas** were observed to be largely isoechoic to surrounding omental fat. Pancreatic duct and capsular contour were acceptably normal and parenchyma respected normal curvilinear patterns. No overt evidence of active inflammatory or neoplastic disease was noted.

Canine

**BREED**

**ULTRASONOGRAPHIC FINDINGS**

Pitbull

- Gastric foreign matter, assuming NPO status

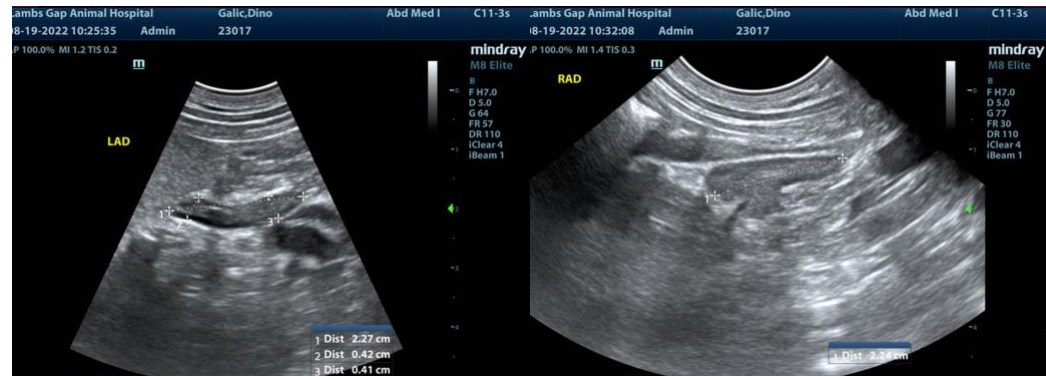**SEX**

**INTERPRETATION OF THE FINDINGS & FURTHER RECOMMENDATIONS**

Spayed Female

If the patient was not NPO, I recommend a recheck sonogram at NPO status and recheck of SDEP 13 position just prior to surgical intervention. Gastrotomy and GI biopsies would be appropriate after removing the soft foreign matter in the stomach.

**AGE**



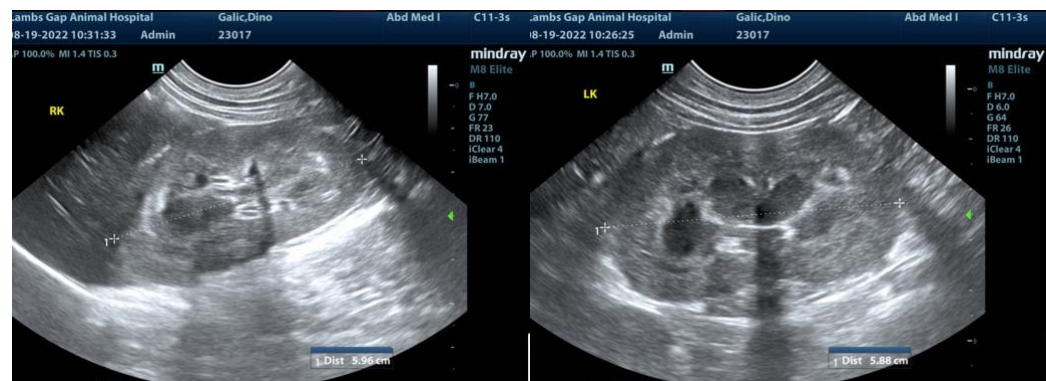
1 Year

**WEIGHT**

49 Pounds

**INTERPRETED BY**

Eric Lindquist, DMV  
DABVP, Cert. IVUSS



**IMAGING PERFORMED BY**

Dr. Jennifer Todd

**HOSPITAL NAME**

Lambs Gap AH

**REFERRING VET**

Dr. Laura Campbell

**INVOICE**

16906

**DATE**

8/19/22



**PATIENT**

Dino Galic

**SPECIES**

Canine

**BREED**

Pitbull

**SEX**

Spayed Female

**AGE**

1 Year

**WEIGHT**

49 Pounds

**INTERPRETED BY**

Eric Lindquist, DMV  
DABVP, Cert. IVUSS

**IMAGING PERFORMED BY**

Dr. Jennifer Todd

**HOSPITAL NAME**

Lambs Gap AH

**REFERRING VET**

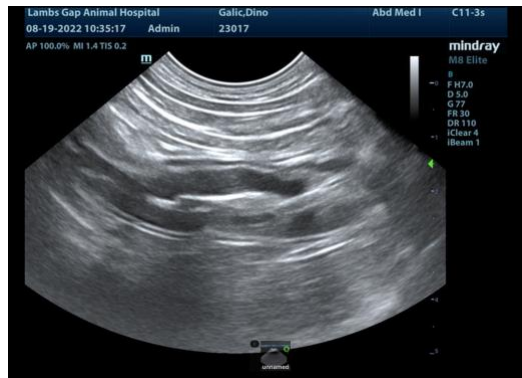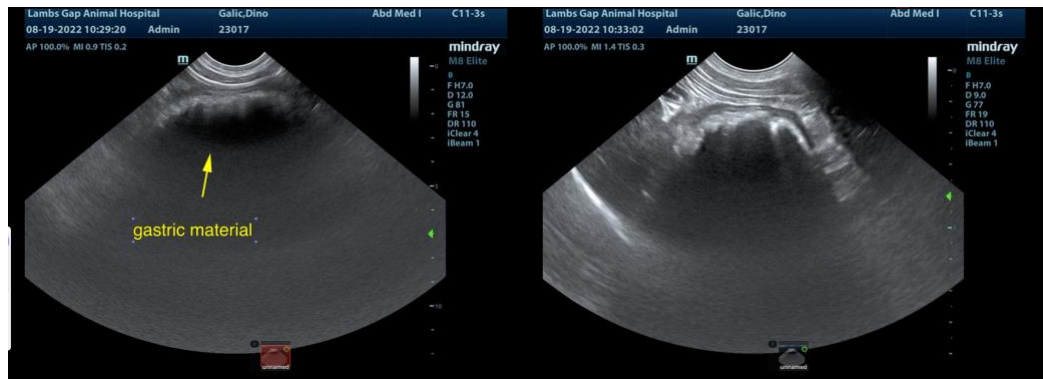
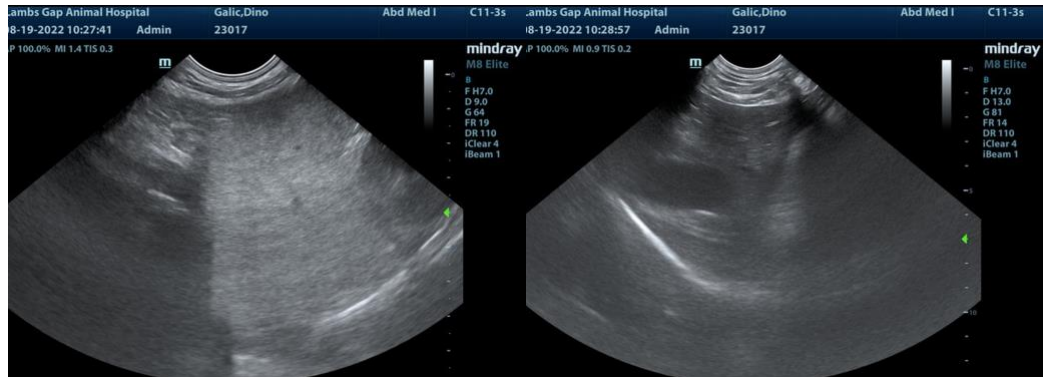
Dr. Laura Campbell

**INVOICE**

16906

**DATE**

8/19/22



The information and recommendations provided are based on the images presented by the referring veterinarian. No evaluation can be communicated regarding pathology that was not visible in the image/video clips provided.

Thank you for this referral. If the clinical or image interpretation does not parallel your findings or if I can be of any further assistance please contact me.

**Eric Lindquist**, DMV, DABVP, Cert. IVUSS, CEO of SonoPath.com  
info@SonoPath.com