

PATIENT PRESENTING CLINICAL SIGNS

Winnie Brown dark bloody discharge from time to time. Currently on Clavaseptin. Severe uterine enlargement. If pregnant less than 42 to 45 days. Pyometra? Mucometra?
Abnormal PE/Chem/CBC/UA Results: WBC 18.27 high, PCT 0.63 high

SPECIES LIMITED ULTRASONOGRAPHIC EXAMINATION

Canine The uterus was dilated. At least two fetuses were present with evident heart beats. Anechoic amniotic fluid present. Subjectively normal fetal structures and fetal sac integrity. No evidence of inflammation.

BREED Both ovaries were uniform. No evident pathology. The left ovary measured 0.6 cm. The right ovary measured 0.9 cm.

French Bulldog

SEX ULTRASONOGRAPHIC FINDINGS

Intact Female

- Viable pregnancy, approximately 45+ days with at least two live fetuses

INTERPRETATION OF THE FINDINGS & FURTHER RECOMMENDATIONS

AGE Periodic metritis may be occurring given the bloody discharge. However, structurally the uterus and fetus appear intact without evident pathology.

4 Years

WEIGHT

11.9 kg

INTERPRETED BY

Eric Lindquist, DMV
DABVP, Cert. IVUSS

IMAGING PERFORMED BY

Crystal Hill

HOSPITAL NAME

BPH Burlington

REFERRING VET

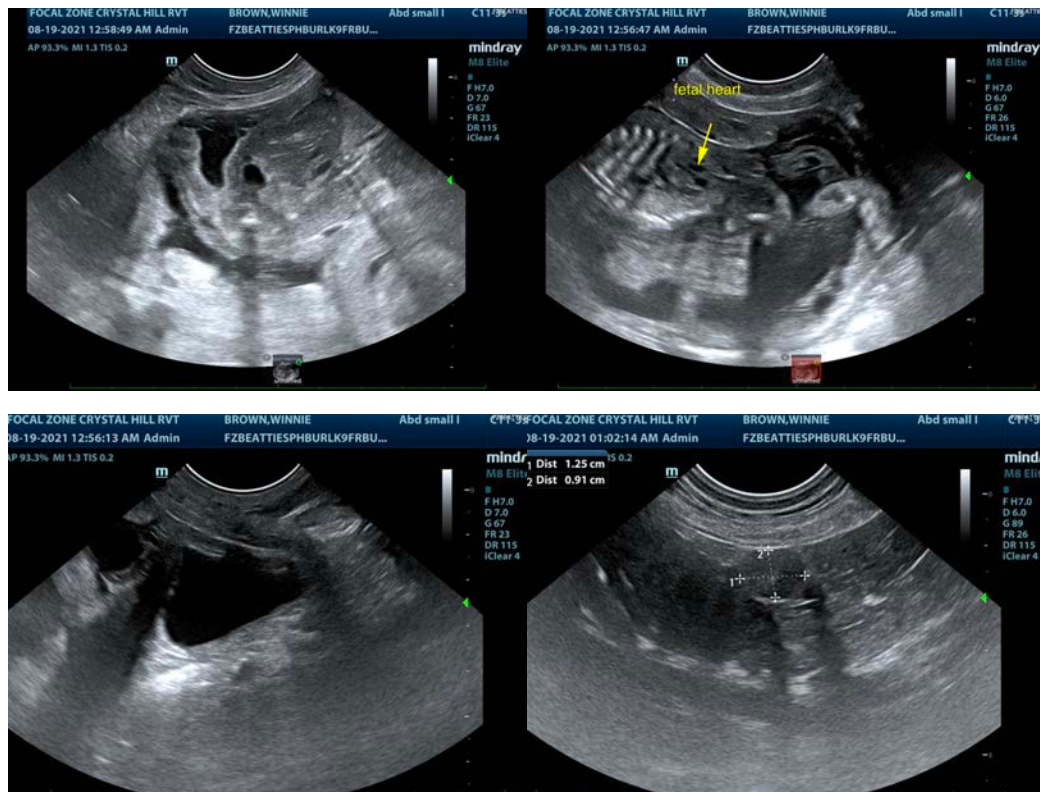
Dr. Williams

INVOICE

24813

DATE

8/19/21





PATIENT

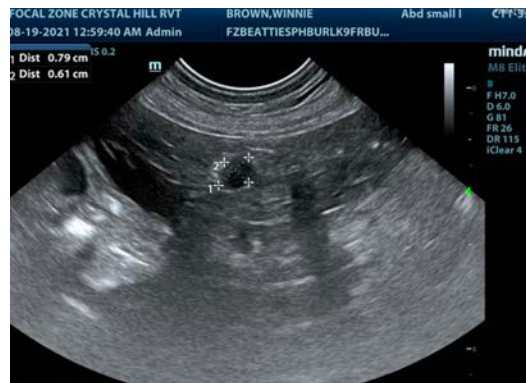Winnie Brown

SPECIES

Canine

BREED

French Bulldog



SEX

Intact Female

AGE

4 Years

WEIGHT

11.9 kg

INTERPRETED BY

Eric Lindquist, DMV
DABVP, Cert. IVUSS

**IMAGING
PERFORMED BY**

Crystal Hill

HOSPITAL NAME

BPH Burlington

REFERRING VET

Dr. Williams

INVOICE

24813

DATE

8/19/21

The information and recommendations provided are based on the images presented by the referring veterinarian. No evaluation can be communicated regarding pathology that was not visible in the image/video clips provided.

Thank you for this referral. If the clinical or image interpretation does not parallel your findings or if I can be of any further assistance please contact me.

Eric Lindquist, DMV, DABVP, Cert. IVUSS, CEO of SonoPath.com
Eric.Lindquist@SonoPath.com