



**PATIENT**

Bella Sather

**SPECIES**

Canine

**BREED**

Labrador

**SEX**

Female

**AGE**

1 year

**WEIGHT**

53 lbs

**INTERPRETED BY**

Eric Lindquist, DMV  
DABVP, Cert. IVUSS

**IMAGING PERFORMED BY**

Dr. Sallee

**HOSPITAL NAME**

Hermiston VC

**REFERRING VET**

Dr. Sallee

**INVOICE**

91360

**DATE**

8/19/21

**PRESENTING CLINICAL SIGNS**

History: History of UTI, placed on simplecef for UTI and p became mildly ataxic. Ultrasound of bladder yesterday hypoechoic, no visible pyometra. Discontinued simplecef p progressed overnight to severe panting, head pressing, not able to walk, possible seizure. Sedated with diazepam on arrival d/t dysphoria

Abnormal PE/Chem/CBC/UA Results: 104.3 on arrival, ALT 342 (10-125), hypocholesterolemia 70 (110-320), low MCV and MCH

**ULTRASONOGRAPHIC EXAMINATION OF THE ABDOMEN**

*Urinary System*

Sand accumulation was noted in the **bladder** with a large amount of echogenic debris. The pelvic urethra was unremarkable.

The iliac lymph nodes were slightly enlarged.

The uterus was slightly thickened without fluid dilation.

The **kidneys** were swollen and irregular in contour with multi-focal areas of mineralization. There was loss of corticomedullary definition noted as well. Both kidneys measured 8.6 cm.

*Adrenal Glands*

The **adrenal glands** were not visualized.

*Spleen*

The **spleen** presented a smooth homogeneous parenchyma hyperechoic to liver and renal cortical parenchyma. A slight 1.0 cm splenic cyst was noted at the caudal aspect of the spleen. This is not likely pathological. The splenic vasculature demonstrated normal volume without signs of congestion or thrombosis.

*Liver*

The **liver** was subnormal in size. An abnormal vessel measuring approximately 0.8 cm in width was noted. This is consistent with intrahepatic shunt. I suspect central divisional shunt. The remainder of the hepatic parenchyma was relatively uniform. The gallbladder was mildly over distended.

*Gastrointestinal*

The stomach was overdistended with chyme, fluid and shadowing structures that are likely kibble. No overt foreign body was noted in the pyloric outflow. However, foreign body obstruction cannot be completely ruled out.



**PATIENT**

**Pancreas**

Bella Sather

The base and limbs of the **pancreas** were observed to be largely isoechoic to surrounding omental fat. Pancreatic duct and capsular contour were acceptably normal and parenchyma respected normal curvilinear patterns. No overt evidence of active inflammatory or neoplastic disease was noted.

**SPECIES**

Canine

**ULTRASONOGRAPHIC FINDINGS**

**BREED**

Labrador

Intrahepatic portosystemic shunt. Suspect central divisional intrahepatic shunt.

Swollen kidneys with mineralization and minor pyelectasia.

Large amount of bladder debris.

**SEX**

Female

Mild uterine thickening.

Splenic cyst.

**AGE**

1 year

**INTERPRETATION OF THE FINDINGS & FURTHER RECOMMENDATIONS**

Bile acid profile is warranted. IV fluid support, urine culture and sensitivity is recommended. The fever may be deriving from urinary tract infection. The bile acids are suspected to be significantly elevated. Referral for interventional radiologist approach to vascular plug or other procedure is recommended for intrahepatic shunting. Concurrent gastric foreign body cannot be ruled out. However, the stomach may be dilated owing to metabolic ileus.

**INTERPRETED BY**

Eric Lindquist, DMV  
DABVP, Cert. IVUS

**IMAGING PERFORMED BY**

Dr. Sallee

**HOSPITAL NAME**

Hermiston VC

**REFERRING VET**

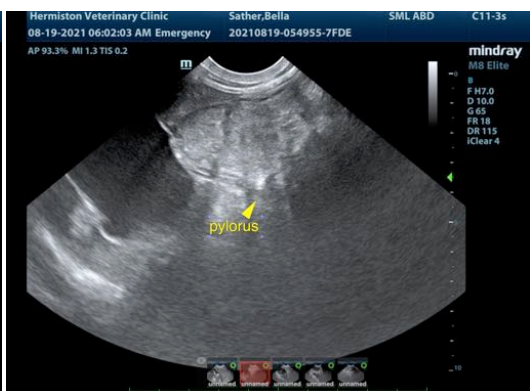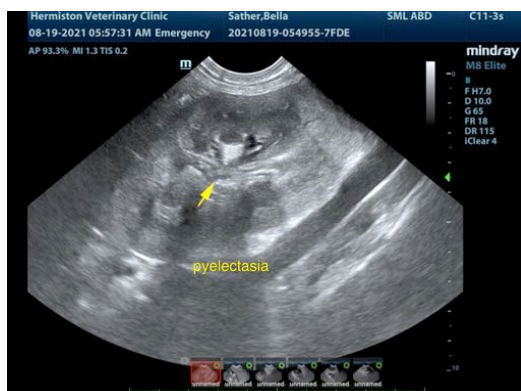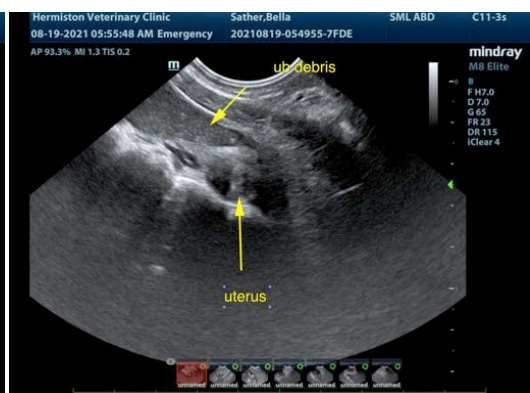
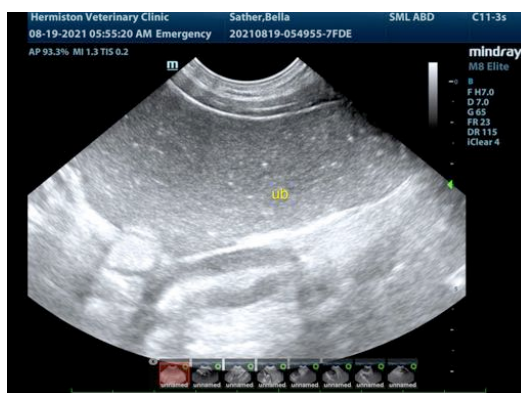Dr. Sallee

**INVOICE**

91360

**DATE**

8/19/21





**PATIENT**

Bella Sather

**SPECIES**

Canine

**BREED**

Labrador

**SEX**

Female

**AGE**

1 year

**WEIGHT**

53 lbs

**INTERPRETED BY**

Eric Lindquist, DMV  
DABVP, Cert. IVUS

**IMAGING PERFORMED BY**

Dr. Sallee

**HOSPITAL NAME**

Hermiston VC

**REFERRING VET**

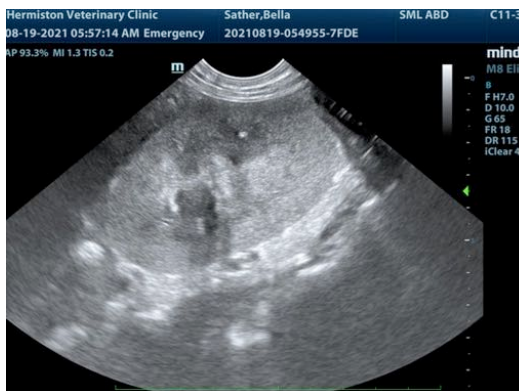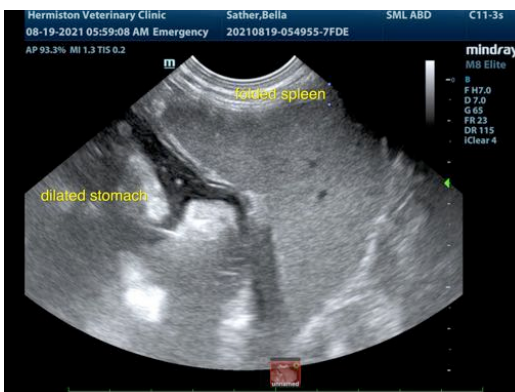
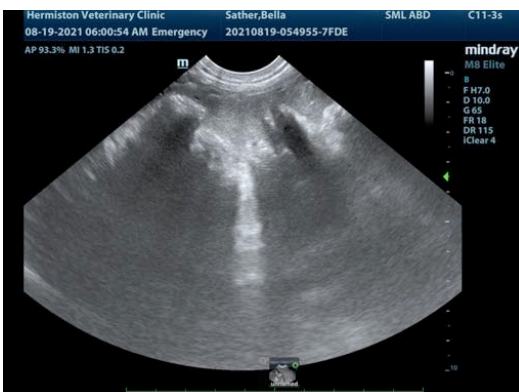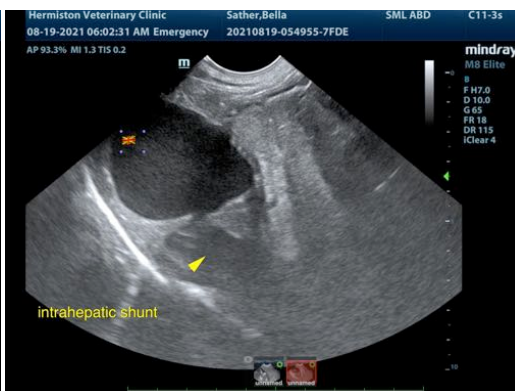
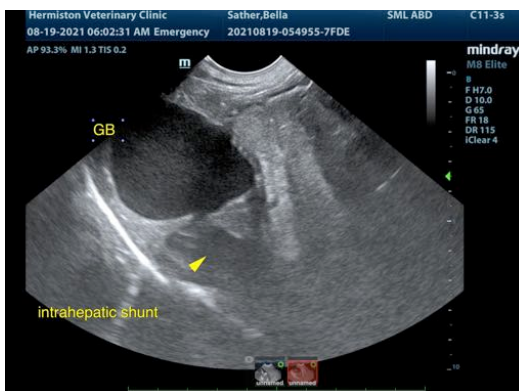
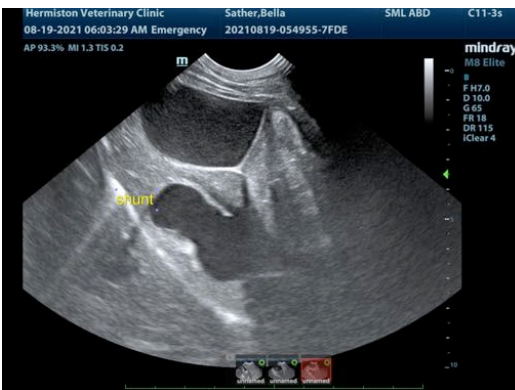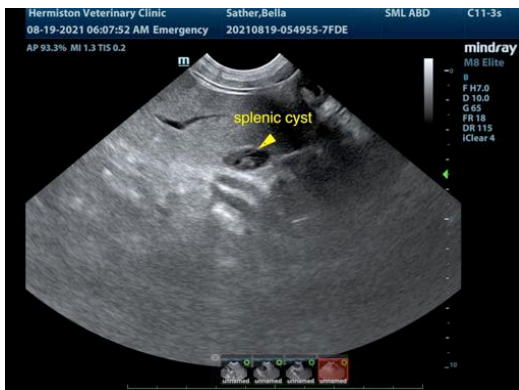Dr. Sallee

**INVOICE**

91360

**DATE**

8/19/21





**PATIENT**

Bella Sather

The information and recommendations provided are based on the images presented by the referring veterinarian. No evaluation can be communicated regarding pathology that was not visible in the image/video clips provided.

**SPECIES**

Canine

Thank you for this referral. If the clinical or image interpretation does not parallel your findings or if I can be of any further assistance please contact me.

**BREED**

Labrador

Eric Lindquist, DMV, DABVP, Cert. IVUSS, CEO of SonoPath.com  
[info@SonoPath.com](mailto:info@SonoPath.com)

**SEX**

Female

**AGE**

1 year

**WEIGHT**

53 lbs

**INTERPRETED BY**

Eric Lindquist, DMV  
DABVP, Cert. IVUSS

**IMAGING  
PERFORMED BY**

Dr. Sallee

**HOSPITAL NAME**

Hermiston VC

**REFERRING VET**

Dr. Sallee

**INVOICE**

91360

**DATE**

8/19/21