



PATIENT PRESENTING CLINICAL SIGNS

Riley Martin History: Had abdominal ultrasound on 8/16/23. Splenic mass. Echo prior to surgery
 Abnormal PE/Chem/CBC/UA Results: 210/169(181), 110/87(92)

SPECIES BREED ULTRASONOGRAPHIC EXAMINATION OF THE HEART

Canine

Shepherd Mix

Spayed female

9 years

85 lbs

Eric Lindquist, DMV
 DABVP, Cert. IVUSS

JK

Hamburg VC

Dr. Martens

46669

8/17/23

The echocardiogram in this patient demonstrated normal **left atrial** size based on 3 separate methods of LA evaluation. The cranial and caudal **mitral** valve leaflets presented normal linear structure, extension in systole, and union in diastole with normal kinesis. The **left ventricle** presented thicknesses with linear contour and was not dilated nor restricted. The **myocardium** presented normal echogenicity without subjective evidence of significant fibrotic or ischemic disease. **Contractility** of the ventricular walls was adequate and in normal range for this patient evidenced by the fractional shortening measurement and subjective evaluation of the different regions of the myocardium. The **left ventricular outflow** tract demonstrated normal laminar flow and subjective structural integrity. The **right atrium** and auricle revealed normal size, structure and content. No evidence of masses was noted. **Tricuspid** valvular assessment demonstrated adequate linear morphology and kinesis. The **right ventricle** was of normal size (1/3 diameter of LV), chordae structure, myocardial echogenicity and thickness. **Pulmonary outflow** tract assessment revealed normal valve structure, laminar flow, and diameter (approx. 1:1 pa/ao ratio). No visible **pericardial** or free pleura fluid was noted. The cranial **mediastinum and pericardial and extra-cardiac regions** were free of masses in the visible window.

CANINE CARDIAC PARAMETERS	MR VMAX (m/s)	TR VMAX (m/s)	LA/AO (Boon method)	LA/AO (Heart Base;)	FS (%)	EF (%)	EPSS (cm)
NORMAL PARAMETER	4.5-5.5	<2.7	1.3	Up to 1.6	28-40	40-100	<0.6
PATIENT			1.0	1.3	35	75	0.5
CANINE CARDIAC PARAMETERS	HR (BPM)	AV VMAX (m/s)	PV MAX (m/s)	BODY WEIGHT (kg)	LA (2D short axis Base view) (cm)	LVIDd (Avg; 2D and m-mode short axis) (cm)	LVIDs (Avg; 2D and m-mode short axis) (cm)
NORMAL PARAMETER	50-100	0.7-1.7	0.7-1.6	BELOW	BELOW	BELOW	BELOW
PATIENT		1.7		85 lbs	1.9	3.8	

ULTRASONOGRAPHIC FINDINGS

Normal echocardiogram.

INVOICE

46669

8/17/23



INTERPRETATION OF THE FINDINGS & FURTHER RECOMMENDATIONS

There was no evidence of pericardial or pleural effusion. There is no contraindication to anesthetic procedure. A large amount of ascites was noted through the diaphragm and is non-cardiogenic in nature.

PATIENT

Riley Martin

SPECIES

Canine

BREED

Shepherd Mix

SEX

Spayed female

AGE

9 years

WEIGHT

85 lbs

INTERPRETED BY

Eric Lindquist, DMV
DABVP, Cert. IVUSS

IMAGING PERFORMED BY

JK

HOSPITAL NAME

Hamburg VC

REFERRING VET

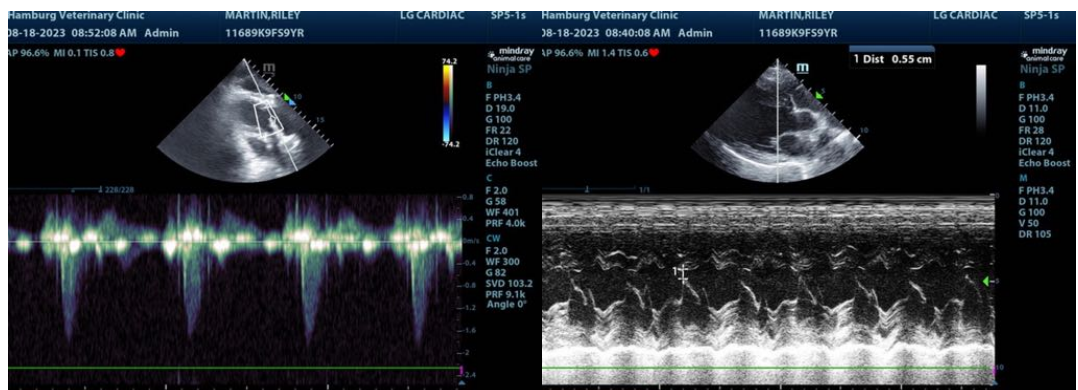
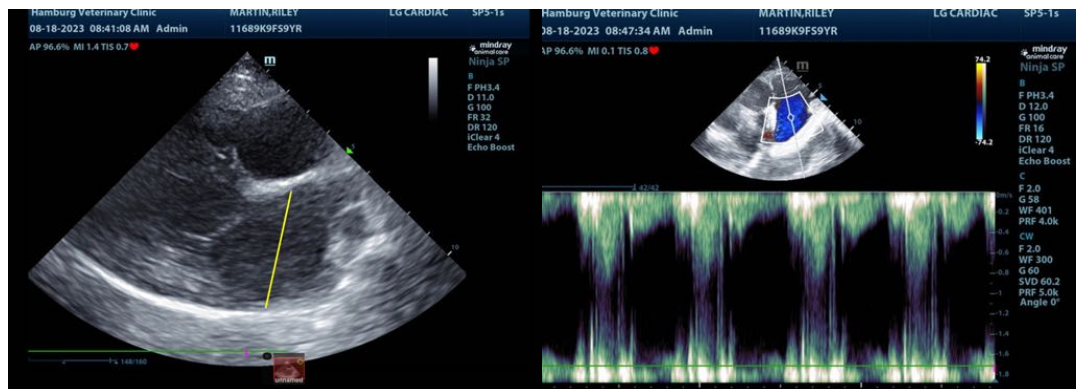
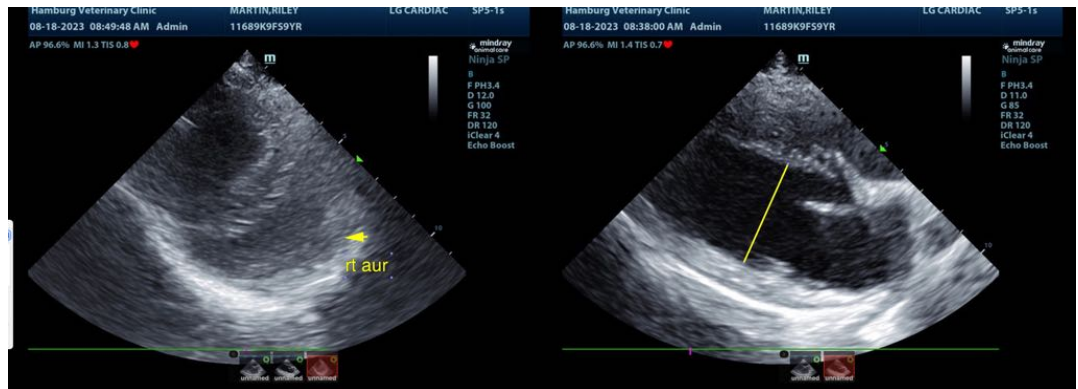
Dr. Martens

INVOICE

46669

DATE

8/17/23





PATIENT

Riley Martin

SPECIES

Canine

BREED

Shepherd Mix

SEX

Spayed female

AGE

9 years

WEIGHT

85 lbs

INTERPRETED BY

Eric Lindquist, DMV
DABVP, Cert. IVUSS

IMAGING PERFORMED BY

JK

HOSPITAL NAME

Hamburg VC

REFERRING VET

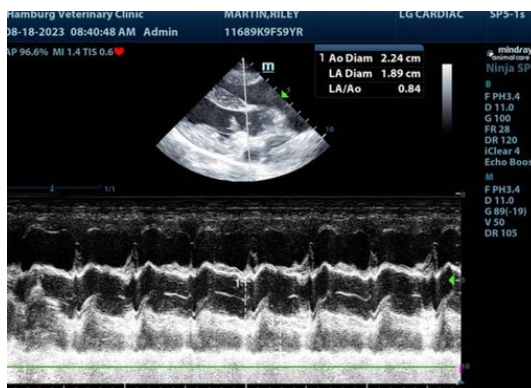
Dr. Martens

INVOICE

46669

DATE

8/17/23



The information and recommendations provided are based on the images presented by the referring veterinarian/sonographer. No evaluation can be communicated regarding pathology that was not visible in the image/video clips provided.

Thank you for this referral. If the clinical or image interpretation does not parallel your findings or if I can be of any further assistance please contact me.

Eric Lindquist, DMV, DABVP, Cert. IVUSS, CEO of SonoPath.com
info@SonoPath.com