



**PATIENT PRESENTING CLINICAL SIGNS**

LittleFoot Wallace

P presented for lethargy for 1 week, decreased appetite, no v/d. P has fleas Temp 104.2, P has lost 1# in a week.

**SPECIES**

Feline

Abnormal PE/Chem/CBC/UA Results: CBC: WBC 25 (2-17) Neu 22.49 (2.3-10.29) Suspected Bands Mono 0.72 (0.05-0.67) Eos 0.13 (0.17-1.57) PLT 123 (151-600) Chem ALKP 12 (14-111) Felv/FIV Neg/Neg

**BREED**

DSH

**ULTRASONOGRAPHIC EXAMINATION OF THE ABDOMEN**

**SEX**

Neutered Male

**Urinary System**

The **urinary bladder**, trigone, and pelvic urethra presented normal thicknesses and normal tone. The ureters were not visible which is normal. No uroliths or sediment were visualized and anechoic urine was present. No evidence of inflammatory or neoplastic changes were noted. Ureteral papillae were normal. The pelvic urethra was imaged 2.0 cm beyond the cystourethral junction.

**AGE**

2 Years

The **kidneys** were technically normal in size yet subjectively swollen and hypervascular. Mild enhanced surrounding pericapsular fat noted, suggestive for inflammation. The left kidney measured 4.4 cm. The right kidney measured 4.7 cm.

**WEIGHT**

9.8

**Adrenal Glands**

Both **adrenal glands** were visualized and recognized as having normal shape, size, position and echogenicity for this breed. The phrenic vasculature, glandular echogenicity and detail were unremarkable. Capsule, cortex, and medullary definition were normal for this age patient. The left adrenal gland measured 0.46 cm. The right adrenal gland measured 0.42 cm.

**INTERPRETED BY**

Eric Lindquist, DMV

DABVP, Cert. IVUSS

**Spleen**

The **spleen** was mildly enlarged (1.26 cm) with uniform, but subtly micronodular parenchyma, and undulating capsular contour. This is consistent with reactive spleen owing to immune stimulus or early infiltrative disease such as mast cell disease or lymphoma. 25-gauge FNA would be ideal if weight loss is an issue to differentiate early round cell neoplasia versus splenitis or reactive spleen all of which can present in this manner.

**IMAGING PERFORMED BY**

Carolina Vet Mobile

**HOSPITAL NAME**

Monroe Road AH

**Liver**

The **liver** images submitted revealed subjectively normal liver size, contour, and structure. Parenchymal echogenicity was naturally coarse and hypoechoic to the spleen. Vascular and biliary tracts were of normal volume with no evidence of congestion. The gallbladder presented acceptably thin walls with primarily anechoic content. The cystic and common bile ducts were normal. No pathological hepatic lymphadenopathy was evident. No overt structural evidence of inflammatory, infiltrative or regenerative pathology was evident.

**REFERRING VET**

Dr. Hariharan

**INVOICE**

44781

**DATE**

8/18/23

**Gastrointestinal**

The **gastric** wall was thickened. No overt loss of mural detail. However, mucosa thickness was 0.65 cm. Empty lumen. The small intestine and colon were unremarkable. Mesenteric lymph nodes were slightly enlarged and hypoechoic with reactive mesentery. The largest node measured approximately 1.5 cm.



**PATIENT**

**Pancreas**

LittleFoot Wallace

The base and limbs of the **pancreas** were observed to be largely isoechoic to surrounding omental fat. Pancreatic duct and capsular contour were acceptably normal and parenchyma respected normal curvilinear patterns. No overt evidence of active inflammatory or neoplastic disease was noted.

**SPECIES**

Feline

**ULTRASONOGRAPHIC FINDINGS**

**BREED**

DSH

- Enlarged spleen
- Mild gastritis pattern with mesenteric lymphadenopathy
- Subjectively swollen kidneys

**SEX**

Neutered Male

**INTERPRETATION OF THE FINDINGS & FURTHER RECOMMENDATIONS**

No overt neoplastic criteria. However, I cannot rule out an early round cell presentation. Ultrasound guided FNA of a mesenteric lymph node with cytology and culture as well as FNA of the spleen indicated. If any inflammatory sediment is present in the urine, then renal FNA indicated. Lymphadenitis, splenitis, infectious agents, viral disease, bartonella all potentials. However, round cell neoplasia is also possible Sampling is strongly recommended in this patient. A clinical trial of Enrofloxacin/Clindamycin combination and support care warranted in the meantime.

**AGE**

2 Years

**WEIGHT**

9.8

**INTERPRETED BY**

Eric Lindquist, DMV  
DABVP, Cert. IVUSS

**IMAGING PERFORMED BY**

Carolina Vet Mobile

**HOSPITAL NAME**

Monroe Road AH

**REFERRING VET**

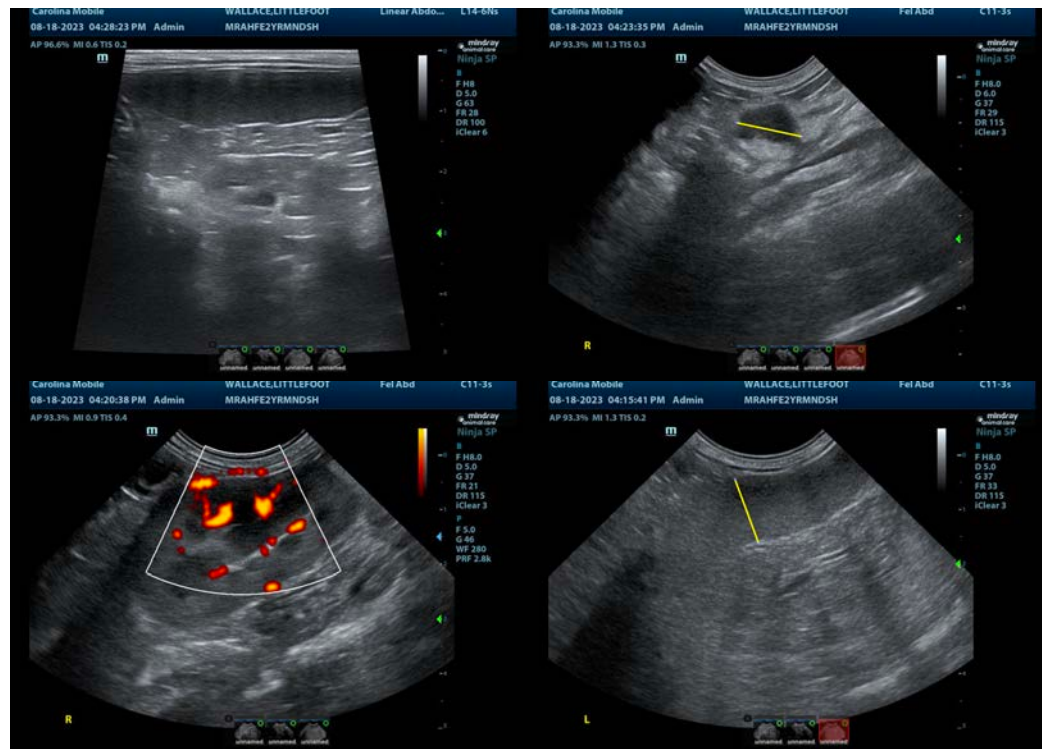
Dr. Hariharan

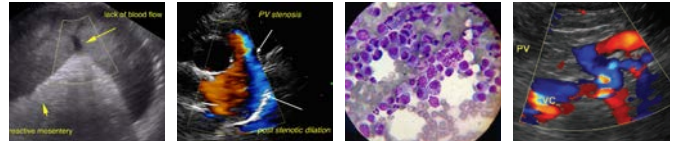
**INVOICE**

44781

**DATE**

8/18/23





**PATIENT**

LittleFoot Wallace

**SPECIES**

Feline

**BREED**

DSH

**SEX**

Neutered Male

**AGE**

2 Years

**WEIGHT**

9.8

**INTERPRETED BY**

Eric Lindquist, DMV  
DABVP, Cert. IVUSS

**IMAGING PERFORMED BY**

Carolina Vet Mobile

**HOSPITAL NAME**

Monroe Road AH

**REFERRING VET**

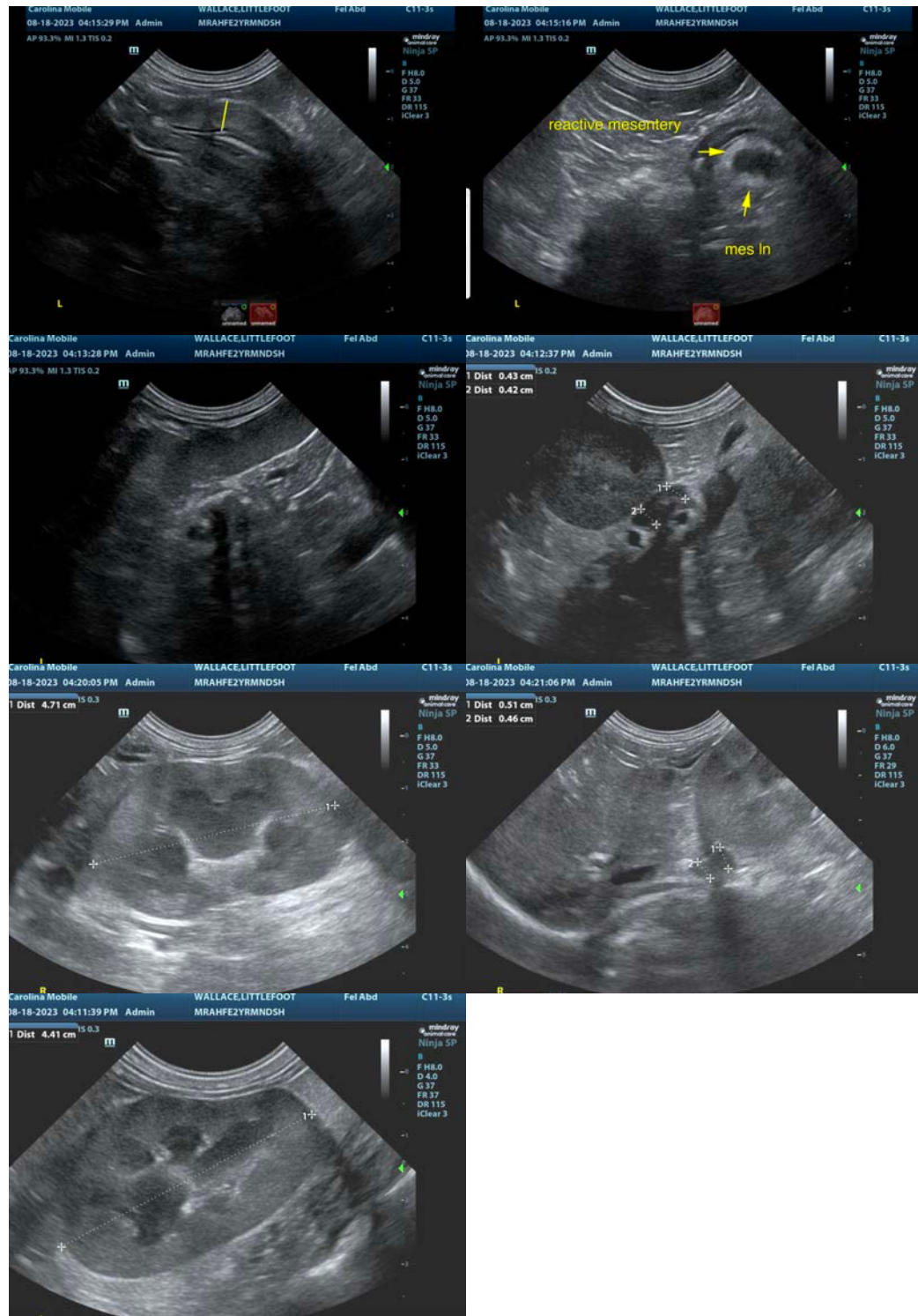
Dr. Hariharan

**INVOICE**

44781

**DATE**

8/18/23





**PATIENT**

LittleFoot Wallace

The information and recommendations provided are based on the images presented by the referring veterinarian/sonographer. No evaluation can be communicated regarding pathology that was not visible in the image/video clips provided.

**SPECIES**

Feline

Thank you for this referral. If the clinical or image interpretation does not parallel your findings or if I can be of any further assistance please contact me.

**Eric Lindquist, DMV, DABVP, Cert. IVUSS, CEO of SonoPath.com**


**BREED**

DSH

[info@SonoPath.com](mailto:info@SonoPath.com)

**SEX**

Neutered Male



The following is an applicable excerpt from the *Curbside Guide to Diagnosis & Treatment of Sonographic Disease* offered by [SonoPath.com](http://www.sonopath.com) Lindquist, Frank, Lobetti, and Modler.

**AGE**

2 Years

An essential quick guide for every general practitioner and sonographer.

<https://sonopath.com/products/curbside-guide-editing-due-release-12012015>

**WEIGHT**

9.8

Fever of Unknown Origin

<http://www.sonopath.com/FUO>

**INTERPRETED BY**

Eric Lindquist, DMV

DABVP, Cert. IVUSS

**IMAGING PERFORMED BY**

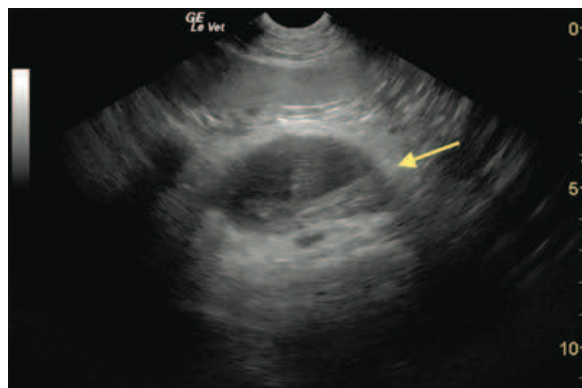
Carolina Vet Mobile

**HOSPITAL NAME**

Monroe Road AH

**REFERRING VET**

Dr. Hariharan



Long axis of the mid-abdomen in a dog with an omental abscess after foreign body penetration from the gastrointestinal tract. The hypoechoic necrotic center of the lesion is surrounded by a thick echogenic capsule and hyperechoic mesenteric fat (arrow) indicating focal peritonitis. The linear echogenic needle (5 cm depth) is barely visible owing to the density of the purulent material contained within the abscess.

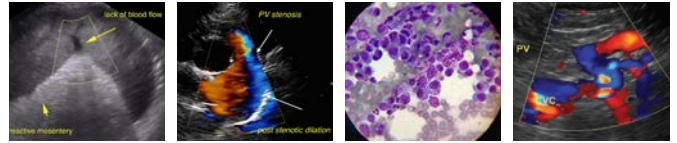
**INVOICE**

44781

**DATE**

8/18/23

Description: The definition of a fever of unknown origin (FUO) has not been clearly defined for animals. Currently, it is either understood to be a fever that does not resolve within the period one would expect for a “self-limiting infection” being treated with appropriate antimicrobial therapy, or that for which an underlying diagnosis has not been determined despite considerable diagnostic effort. The common causes of FUO were summarized concisely in a presentation at the American College of Veterinary



**PATIENT**

Internal Medicine 2004 Forum. The presenters synthesized information from three veterinary papers on the subject, which suggested the following:

LittleFoot Wallace

**SPECIES**

Feline

**BREED**

DSH

**SEX**

Neutered Male

**AGE**

2 Years

**WEIGHT**

9.8

**INTERPRETED BY**

Eric Lindquist, DMV

DABVP, Cert. IVUSS

**IMAGING PERFORMED BY**

Carolina Vet Mobile

**HOSPITAL NAME**

Monroe Road AH

**REFERRING VET**

Dr. Hariharan

**INVOICE**

44781

**DATE**

8/18/23

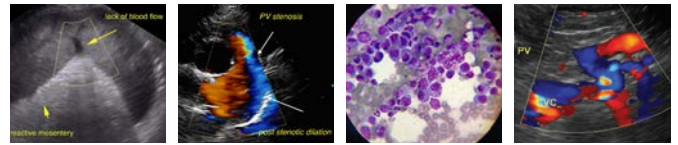
Final Diagnosis	Bennett (dogs & cats)	Dunn and Dunn (dogs only)	Lunn (dogs & one cat)	Total	Percent
Infection	21	16	10	47	28
Immune	18	22	6	46	27
Bone marrow disease	4	22	2	28	16
Neoplasia (outside marrow)	0	10	2	12	7
Miscellaneous	2	12	2	16	9
No diagnosis	0	19	2	21	12
<b>TOTALS</b>	<b>45</b>	<b>101</b>	<b>24</b>	<b>170</b>	<b>99</b>

The types of infection diagnosed in this case series were varied, ranging from discospondylitis (8 cases), blastomycosis (6), and bacterial endocarditis (4), to leishmaniasis (1), prostatitis (1), and *Ehrlichia canis* infection (1); a multitude of other infectious causes also fell within the spectrum. Of the cases in which immune-mediated disease was found, 44% had immune-mediated polyarthritis. Bone marrow diseases included myeloproliferative disease, myelodysplasia (8), lymphocytic leukemia (8), myeloma (3), chronic granulocytic leukemia (3), lymphoblastic leukemia, and malignant histiocytosis. The types of neoplasia located outside the bone marrow included lymphoma (6), metastatic disease (2), and neoplasms of the lung, spleen, and stomach. Finally, miscellaneous diseases included hypertrophic osteodystrophy (6), meningitis (3), portosystemic shunt (3), lymphadenitis (2), panosteitis, and intervertebral disc disease. Overall, the most common causes across all cases were polyarthritis (44), lymphoid neoplasia (15), discospondylitis (8), myelodysplasia (8), hypertrophic osteodystrophy (6), and blastomycosis (6).

Clinical Signs: Animals usually present with either persistent or waxing and waning fevers ranging from 103°F to 106°F. Other clinical signs depend on the underlying cause of the fever. Careful and thorough physical examination is required to assess potential causes.

Diagnostics: FUO etiologies are partly related to geography, and thus locale or travel history should factor into a practitioner's diagnostic approach. A patient's lifestyle may also provide clues regarding exposure to certain etiologic agents. Therefore, conducting a thorough history can unveil important pieces of the diagnostic puzzle. Physical examination is especially important and should include an inspection of all accessible lymph nodes, palpation and movement of the joints, a fundic examination, a neurological evaluation, spinal and limb palpation and range of motion tests, and a rectal examination.

A minimum database should include a CBC reviewed by a clinical pathologist, as well as a biochemical profile and urinalysis. Retroviral testing should also be considered in cats. In areas where tick-borne



**PATIENT**

LittleFoot Wallace

**SPECIES**

Feline

**BREED**

DSH

**SEX**

Neutered Male

**AGE**

2 Years

**WEIGHT**

9.8

disease is prevalent, in-house testing should be performed early. Advanced laboratory work can include: urine culture, blood culture, and infectious disease panels (PCR and/or serology). In dogs, one may screen for the following infectious agents: *Ehrlichia* spp., *Borrelia burgdorferi*, Rock Mountain Spotted Fever, *Bartonella* spp. (culture and PCR), and *Leptospira* spp. in cases of hepatic or renal involvement. In cats, one should evaluate for FeLV, FIV, feline infectious peritonitis (FIP) virus, toxoplasmosis, *Hemoplasma* spp. (*Mycoplasma*), and *Bartonella* spp. (culture and PCR). Testing for *Ehrlichia* spp., *Rickettsia* spp., and *Anaplasma phagocytophilum* can also be considered. A fungal assay is indicated if the patient lives in or has had exposure to a region with a higher incidence of fungal disease. Other infectious disease tests may be performed depending on the geographical location of the pet. Screening for *Brucella* should be done in breeding dogs. Immune-mediated disease screening can include a Coomb's test, a slide agglutination test (if the patient is anemic), and an antinuclear antibody (ANA) test. Immune disease is often a diagnosis of exclusion.

Imaging should include thoracic radiographs, abdominal ultrasound, and/or abdominal radiographs. Ultrasound can be very useful for assessing evidence of cholangiohepatitis, pyelonephritis, chronic urinary tract infection, abscess formation, peritonitis, and neoplasia; it also permits an examination of the intra-abdominal lymph nodes. An echocardiogram can offer assessment for vegetative endocarditis, whereas spinal radiographs offer assessment for discospondylitis. In cases where all other testing has proven negative and the patient has not responded to broad-spectrum antibiotics and supportive care, arthrocentesis should be considered to evaluate for septic joint disease, immune-mediated polyarthritis, and infectious disease. Finally, one can consider assessing the cerebrospinal fluid for meningoencephalitis, GME, and meningitis/arteritis. A bone marrow exam should be performed if blood dyscrasias are noted on the CBC.

**INTERPRETED BY**

Eric Lindquist, DMV

DABVP, Cert. IVUSS

**Treatment:** Treatment of the fever depends entirely on the underlying cause. Ideally, a thorough diagnostic plan will yield a diagnosis that will guide the appropriate therapeutic course. However, if an exhaustive approach has not produced a definitive diagnosis and there is no response to broad-spectrum antibiotics, trial therapy with immunosuppressive agents such as prednisolone can be considered to treat presumed immune-mediated diseases. Given the potential for negative sequelae should an underlying infection be present, one must be certain that the investigation is thorough and monitor the patient's response carefully.

**IMAGING PERFORMED BY**

Carolina Vet Mobile

**Conclusion:** If a documented fever has not responded to antibiotics, antipyretics, or general nursing care, it is important to obtain a diagnosis to guide more specific treatment. A systematic physical examination and thorough history-taking will help inform further diagnostics in addition to what is revealed by the minimum database.

**HOSPITAL NAME**

Monroe Road AH

**REFERRING VET**

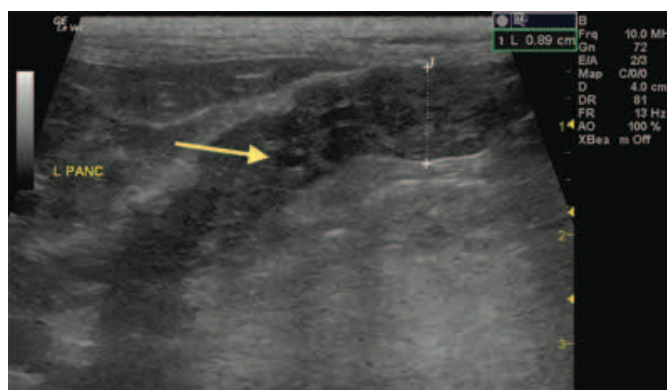
Dr. Hariharan

**INVOICE**

44781

**DATE**

8/18/23



Long axis of the left pancreatic limb (between calipers) in a cat with pancreatitis after undergoing a renal transplant. Note the decrease in echogenicity and mild loss of regular echotexture of the swollen and irregularly contoured pancreas. Also note the mild dilation of the pancreatic duct (arrow). Focal peritonitis is evident by increased echogenicity and loss of the linear echotexture of the



**PATIENT**

LittleFoot Wallace

**SPECIES**

Feline

**BREED**

DSH

**SEX**

Neutered Male

**AGE**

2 Years

**WEIGHT**

9.8

**INTERPRETED BY**

Eric Lindquist, DMV

DABVP, Cert. IVUSS

**IMAGING PERFORMED BY**

Carolina Vet Mobile

**HOSPITAL NAME**

Monroe Road AH

**REFERRING VET**

Dr. Hariharan

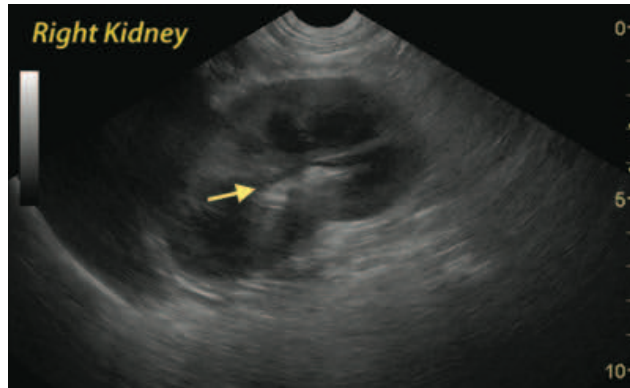
**INVOICE**

44781

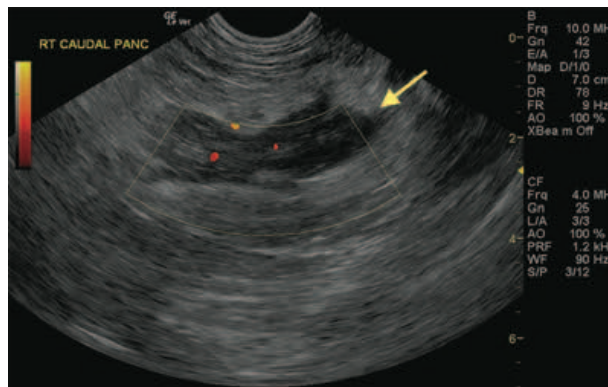
**DATE**

8/18/23

surrounding mesentery.



Long axis of the right kidney in a dog with pyelonephritis. Note the increased echogenicity and irregular outline of the renal crest and diverticuli and the mild dilation of the renal pelvis (arrow).



Long axis of the right pancreatic limb in a dog with acute pancreatitis. The swollen hypoechoic pancreas is embedded in hyperechoic mesenteric fat (arrow). Note the regional differences in blood flow intensity within the parenchyma as demonstrated by Power Doppler interrogation compatible with multifocal disruption of vascularization as a sequela of the severe inflammation.

References:

Bennet D. Diagnosis of pyrexia of unknown origin. *In Practice* 1995;17(10):470-81.

Dunn KJ, Dunn JK. Diagnostic investigations in 101 dogs with pyrexia of unknown origin. *J Sm Anim Pract* 1998;39(12):574-80.

Flood J. The diagnostic approach to fever of unknown origin in cats. *Compend Contin Educ Vet* 2009;31(1):26-31.

Flood J. The diagnostic approach to fever of unknown origin in dogs. *Compend Contin Educ Vet* 2009;31(1):14-21.



**PATIENT**

LittleFoot Wallace

Lappin MR. The role of blood borne pathogens in feline fever of unknown origin. Proceedings from the American College of Veterinary Internal Medicine, Denver, CO, June 15-18, 2011.

**SPECIES**

Feline

Lunn KF. Fever of unknown origin: a systematic approach to diagnosis. *Compend Contin Educ Vet* 2001;23(11):976-92.

**BREED**

DSH

Lunn KF. Fever of unknown origin: appropriate choice of diagnostic tests. Proceedings from the American College of Veterinary Internal Medicine, Minneapolis, MN, June 9-12, 2004.

**SEX**

Neutered Male

**AGE**

2 Years

**WEIGHT**

9.8

**INTERPRETED BY**

Eric Lindquist, DMV

DABVP, Cert. IVUSS

**IMAGING PERFORMED BY**

Carolina Vet Mobile

**HOSPITAL NAME**

Monroe Road AH

**REFERRING VET**

Dr. Hariharan

**INVOICE**

44781

**DATE**

8/18/23