



PATIENT

Bailey Argueta

PRESENTING CLINICAL SIGNS

History: recheck prev u/s 8/16 potential underlying emerging pyo

SPECIES

Canine

ULTRASONOGRAPHIC EXAMINATION OF THE ABDOMEN

It appears that the dilated structure is likely a cystic left ovary or proximal left uterine horn. The remainder of the uterus appeared unremarkable.

BREED

Golden Retriever

ULTRASONOGRAPHIC FINDINGS

Dilated structure likely cystic left ovary or proximal left uterine horn.

SEX

Female

INTERPRETATION OF THE FINDINGS & FURTHER RECOMMENDATIONS

This is not likely playing a primary role in the history of the clinical signs in this patient; however, if this patient is not destined for reproductive activity then ovariohysterectomy is recommended.

AGE

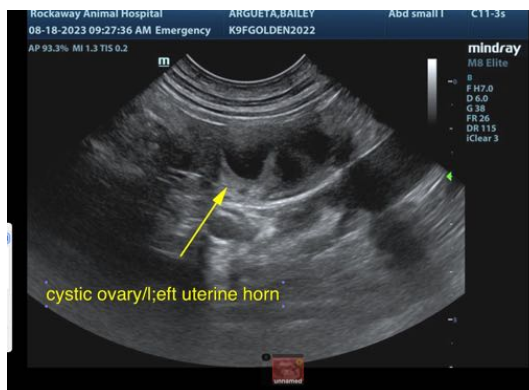
9 months

WEIGHT

53 lbs

INTERPRETED BY

Eric Lindquist, DMV
DABVP, Cert. IVUSS



IMAGING PERFORMED BY

Jenn

The information and recommendations provided are based on the images presented by the referring veterinarian/sonographer. No evaluation can be communicated regarding pathology that was not visible in the image/video clips provided.

HOSPITAL NAME

Rockaway AH

Thank you for this referral. If the clinical or image interpretation does not parallel your findings or if I can be of any further assistance please contact me.

REFERRING VET

Dr. Maniar

Eric Lindquist, DMV, DABVP, Cert. IVUSS, CEO of SonoPath.com
info@SonoPath.com

INVOICE

46668

DATE

8/18/23