



**PATIENT**

Chester Curtis

**PRESENTING CLINICAL SIGNS**

lethargic, r/o neoplasia, anemic on routine bw takes dasuquin and vitamin c daily

**SPECIES**

Canine

Abnormal PE/Chem/CBC/UA Results: retic (hi) 1.4, magn. (lo) 1.4, squamos ep. (hi) 4-10, ph (hi) 8.0, abs. lymph. (lo) 689, neu (hi) 79, platelet count (lo) 77, hct (lo) 27, hemog. (lo) 8.5, rbc (lo) 3.6

**ULTRASONOGRAPHIC EXAMINATION OF THE ABDOMEN**

**BREED**

Lab

**Urinary System**

The **urinary bladder** itself was unremarkable. Slight sand accumulation noted, non-obstructive.

**SEX**

Neutered Male

The **kidneys** revealed normal size and structure, corticomedullary definition and ratio for this age. The cortices presented largely uniform texture with normal echogenic relationship to liver and spleen. Medullary structure differed distinctly from the cortex and no evidence of pelvic dilation was present. The capsules were acceptably uniform without significant irregularities. The left kidney measured 7.4 cm. The right kidney measured 7.4 cm.

**AGE**

8 Years 3 Months

**Adrenal Glands**

The regions of the **adrenal glands** were unremarkable.

**WEIGHT**

87.5 Pounds

**Spleen**

The **spleen** presented a smooth homogeneous parenchyma hyperechoic to liver and renal cortical parenchyma. The spleen was folded upon itself cranially. The capsule was smooth without noticeable expansion or deviation from within the spleen or adjacent pathology. The splenic vasculature demonstrated normal volume without signs of congestion or thrombosis. No sonographic evidence of acute or chronic inflammatory, neoplastic, or infarctual changes were noted.

**INTERPRETED BY**

Eric Lindquist, DMV

**Liver**

DABVP, Cert. IVUSS

The **liver** images submitted revealed subjectively normal liver size, contour, and structure. Parenchymal echogenicity was naturally coarse and hypoechoic to the spleen. Vascular and biliary tracts were of normal volume with no evidence of congestion. The gallbladder presented acceptably thin walls with primarily anechoic content. The cystic and common bile ducts were normal. No pathological hepatic lymphadenopathy was evident. No overt structural evidence of inflammatory, infiltrative or regenerative pathology was evident.

**IMAGING PERFORMED BY**

Heather

**HOSPITAL NAME**

ACC Flanders

**Gastrointestinal**

Examination of the **gastrointestinal tract** revealed a stomach and intestine free of stasis, of normal wall thickness, acceptable curvilinear mural detail, and peristaltic activity. Small and large intestine demonstrated normal luminal chyme and stool consistency respectively. No obstructive or overt infiltrative disease was noted. No associated abnormal lymphatic activity was noted.

**REFERRING VET**

Dr. Hallihan

**Pancreas**

**INVOICE**

40576

The base and limbs of the **pancreas** were observed to be largely isoechoic to surrounding omental fat. Pancreatic duct and capsular contour were acceptably normal and parenchyma respected normal curvilinear patterns. No overt evidence of active inflammatory or neoplastic disease was noted.

**Other**

**DATE**

8/18/22

Rapid view of the heart revealed no evident pathology.



**PATIENT**

Chester Curtis

**ULTRASONOGRAPHIC FINDINGS**

- Structurally unremarkable abdomen

**SPECIES**

Canine

**INTERPRETATION OF THE FINDINGS & FURTHER RECOMMENDATIONS**

No evidence of pathology responsible the anemia. CBC path review +/- bone marrow aspirate may be appropriate.

**BREED**

Lab

**SEX**

Neutered Male

**AGE**

8 Years 3 Months

**WEIGHT**

87.5 Pounds

**INTERPRETED BY**

Eric Lindquist, DMV

DABVP, Cert. IVUSS

**IMAGING PERFORMED BY**

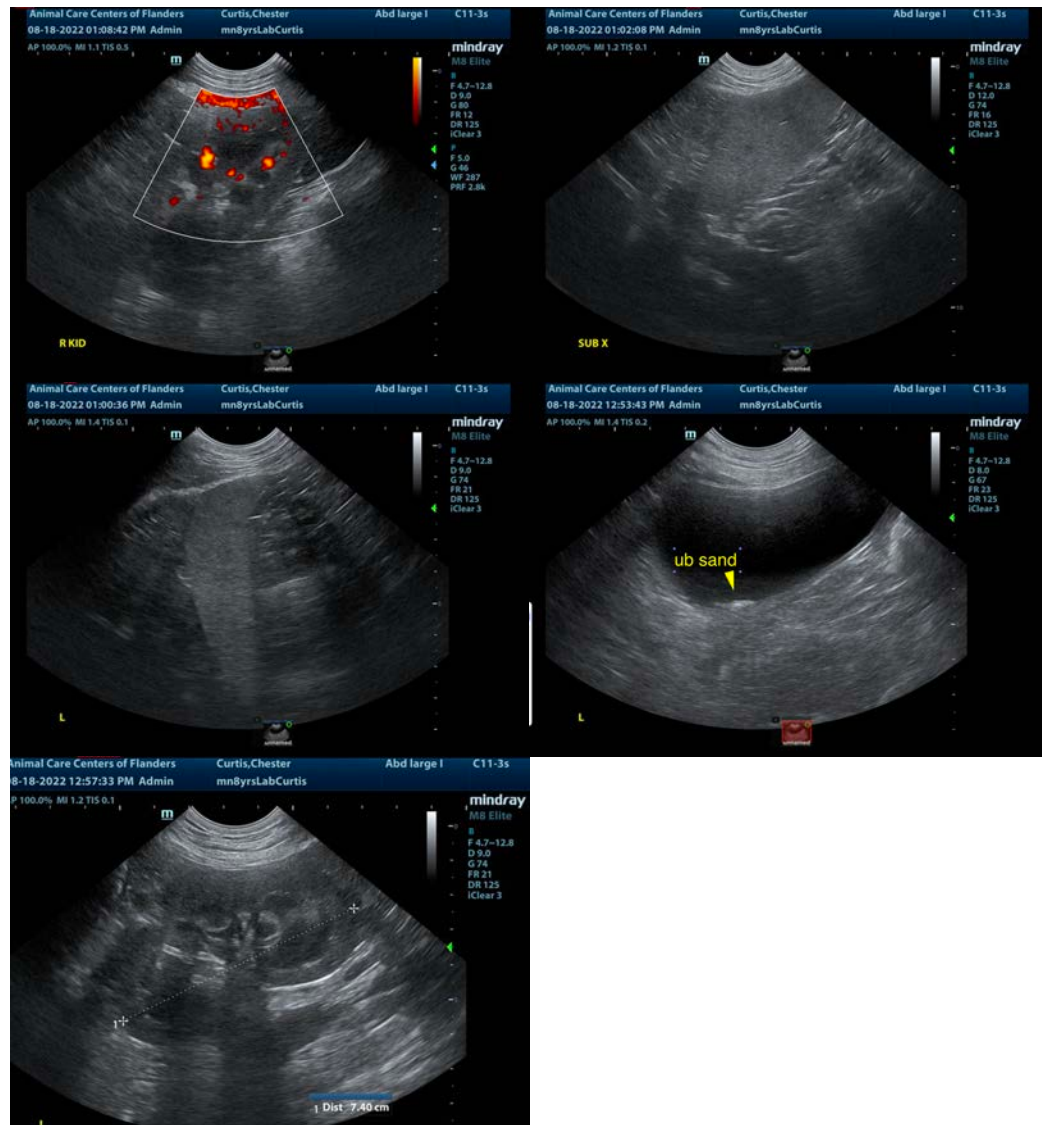
Heather

**HOSPITAL NAME**

ACC Flanders

**REFERRING VET**

Dr. Hallihan



The information and recommendations provided are based on the images presented by the referring veterinarian/sonographer. No evaluation can be communicated regarding pathology that was not visible in the image/video clips provided.

**INVOICE**

40576

Thank you for this referral. If the clinical or image interpretation does not parallel your findings or if I can be of any further assistance please contact me.

**DATE**

8/18/22

Eric Lindquist, DMV, DABVP, Cert. IVUSS, CEO of SonoPath.com [info@SonoPath.com](mailto:info@SonoPath.com)