



PATIENT PRESENTING CLINICAL SIGNS

Aurora Olthof

History: No history of heart murmur O planning on breeding and wants to screen for heart disease

SPECIES ULTRASONOGRAPHIC EXAMINATION OF THE HEART

Canine

BREED

Golden Retriever

SEX

Female

AGE

2 years

The echocardiogram in this patient demonstrated normal **left atrial** size based on 3 separate methods of LA evaluation. The cranial and caudal **mitral** valve leaflets presented normal linear structure, extension in systole, and union in diastole with normal kinesis. The **left ventricle** presented thicknesses with linear contour and was not dilated nor restricted. The **myocardium** presented normal echogenicity without subjective evidence of significant fibrotic or ischemic disease. **Contractility** of the ventricular walls was adequate and in normal range for this patient evidenced by the fractional shortening measurement and subjective evaluation of the different regions of the myocardium. The **left ventricular outflow** tract demonstrated normal laminar flow and subjective structural integrity. The **right atrium** and auricle revealed normal size, structure and content. No evidence of masses was noted. **Tricuspid** valvular assessment demonstrated adequate linear morphology and kinesis. The **right ventricle** was of normal size (1/3 diameter of LV), chordae structure, myocardial echogenicity and thickness. **Pulmonary outflow** tract assessment revealed normal valve structure, laminar flow, and diameter (approx. 1:1 pa/ao ratio). No visible **pericardial** or free pleura fluid was noted. The cranial **mediastinum and pericardial and extra-cardiac regions** were free of masses in the visible window.

WEIGHT

66.4 lbs

INTERPRETED BY

Eric Lindquist, DMV
DABVP, Cert. IVUSS

IMAGING PERFORMED BY

Dr. Gunther

HOSPITAL NAME

New Frontier AMC

REFERRING VET

Dr. Gunther

CANINE CARDIAC PARAMETERS	MR VMAX (m/s)	TR VMAX (m/s)	LA/AO (Boon method)	LA/AO (Heart Base; Swe)	FS (%)	EF (%)	EPSS (cm)
NORMAL PARAMETER	4.5-5.5	<2.7	1.3	<1.6	28-40	40-100	<0.6
PATIENT			1.15	1.36	35	65	0.1
CANINE CARDIAC PARAMETERS	HR (BPM)	AV VMAX (m/s)	PV MAX (m/s)	BODY WEIGHT (kg)	LA (2D short axis Base view) (cm)	LVIDd (Avg; 2D and m-mode short axis) (cm)	LVIDs (Avg; 2D and m-mode short axis) (cm)
NORMAL PARAMETER	50-100	0.7-1.7	0.7-1.6	BELOW	BELOW	BELOW	BELOW
PATIENT		1.7	0.9	66.4 lbs	3.51	3.37	

ULTRASONOGRAPHIC FINDINGS

Normal echocardiogram.

INVOICE

32416

DATE

8/18/22

INTERPRETATION OF THE FINDINGS & FURTHER RECOMMENDATIONS

There was no evidence of acquired or congenital cardiac disease. There is no contraindication to breeding based on the echocardiogram provided.



PATIENT

Aurora Olthof

SPECIES

Canine

BREED

Golden Retriever

SEX

Female

AGE

2 years

WEIGHT

66.4 lbs

INTERPRETED BY

Eric Lindquist, DMV
DABVP, Cert. IVUS

IMAGING PERFORMED BY

Dr. Gunther

HOSPITAL NAME

New Frontier AMC

REFERRING VET

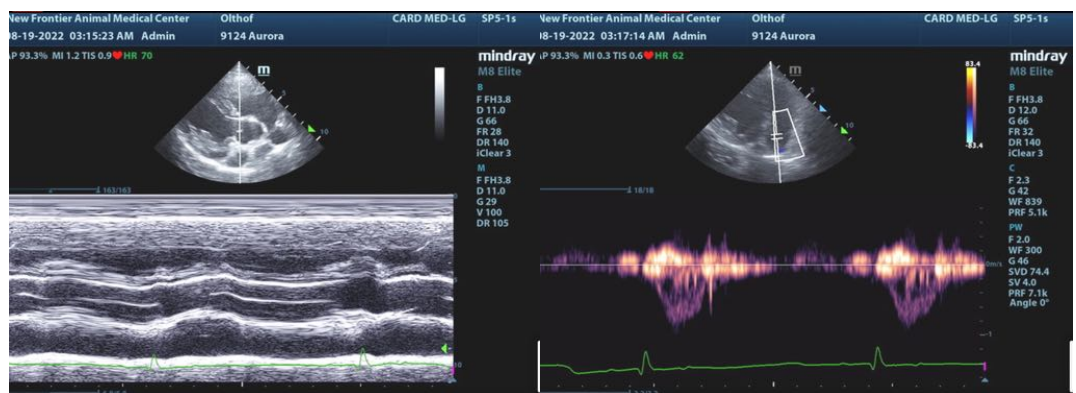
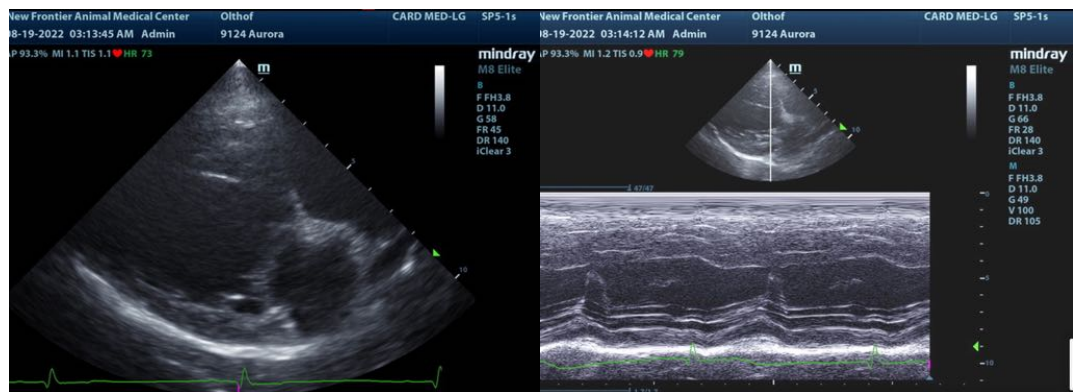
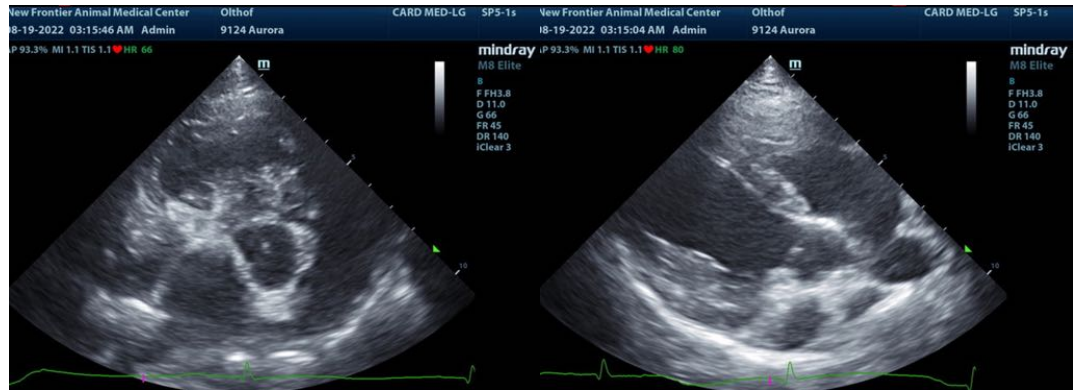
Dr. Gunther

INVOICE

32416

DATE

8/18/22





PATIENT

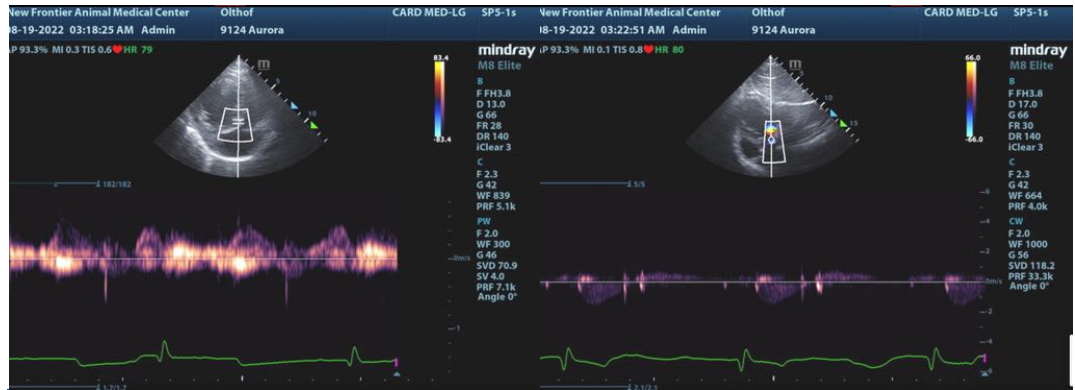
Aurora Olthof

SPECIES

Canine

BREED

Golden Retriever



SEX

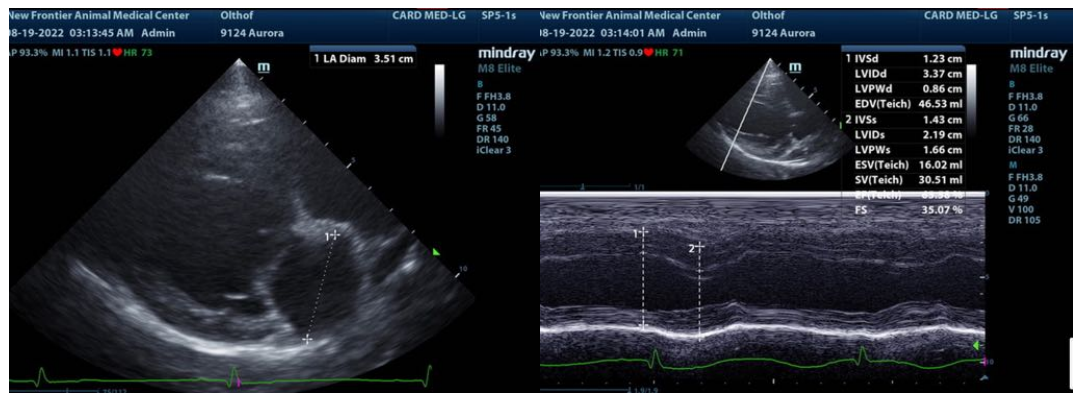
Female

AGE

2 years

WEIGHT

66.4 lbs



INTERPRETED BY

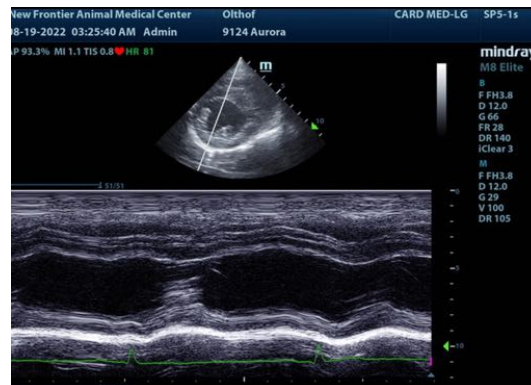
Eric Lindquist, DMV
DABVP, Cert. IVUSS

IMAGING PERFORMED BY

Dr. Gunther

HOSPITAL NAME

New Frontier AMC



REFERRING VET

Dr. Gunther

The information and recommendations provided are based on the images presented by the referring veterinarian/sonographer. No evaluation can be communicated regarding pathology that was not visible in the image/video clips provided.

Thank you for this referral. If the clinical or image interpretation does not parallel your findings or if I can be of any further assistance please contact me.

INVOICE

32416

Eric Lindquist, DMV, DABVP, Cert. IVUSS, CEO of SonoPath.com
info@SonoPath.com

DATE

8/18/22