



PATIENT

Seven Harris

SPECIES

Canine

BREED

Labrador Retriever

SEX

Male

AGE

88 years

WEIGHT

68.2 lbs

INTERPRETED BY

Eric Lindquist, DMV
DABVP, Cert. IVUSS

IMAGING PERFORMED BY

Dr. Anderson

HOSPITAL NAME

Elizabeth AH

REFERRING VET

Dr. Anderson

INVOICE

91321

DATE

8/18/21

PRESENTING CLINICAL SIGNS

History: Not eating or drinking for 2 days. Losing large amounts of hair.
Abnormal PE/Chem/CBC/UA Results: PE: bilaterally symmetrical ventrum and limb hair loss, prominent nipples, pain on abdominal palpation, cryptorchid, external testicle is very soft and small, small mass above accessory pad RF. CBC: 5.29 M/uL, WBC 22.52 K/uL, Mono 2.4 K/uL, Neut 18.78 K/uL, Baso 0.15 K/uL Chem: normal cPL: normal X-rays of Chest: No mets seen, 3 areas of spondylosis X-rays of abdomen: mass seen between bladder and spleen.

ULTRASONOGRAPHIC EXAMINATION OF THE ABDOMEN

Urinary System

The **urinary bladder**, trigone, and pelvic urethra presented normal thicknesses and normal tone. The ureters were not visible which is normal. No uroliths or sediment were visualized and anechoic urine was present. No evidence of inflammatory or neoplastic changes was noted. Ureteral papillae were normal.

The **kidneys** revealed largely normal size and structure, corticomedullary definition and ratio (cortex 1/3 of medulla) were essentially maintained with some age-related loss of curvilinear patterns regarding the capsule and C/M junction. The cortices presented largely uniform texture with some increased echogenicity expected for this age patient. Medullary structure differed distinctly from that of the cortex and no evidence of pelvic dilation was present. The right kidney measured 7.33 cm. The left kidney measured 7.68 cm.

Adrenal Glands

Both **adrenal glands** were visualized and recognized as having normal shape, size, position and echogenicity for this breed. The phrenic vasculature, glandular echogenicity and detail were unremarkable. Capsule, cortex, and medullary definition were normal for this age patient. The left adrenal gland measured 2.96 x 0.62 cm at the caudal pole and 0.6 cm at the cranial pole. The right adrenal gland measured 2.06 x 0.66 cm at the cranial pole and 0.66 cm at the caudal pole.

Spleen

The **spleen** presented a smooth homogeneous parenchyma hyperechoic to liver and renal cortical parenchyma. The capsule was smooth without noticeable expansion or deviation from within the spleen or adjacent pathology. The splenic vasculature demonstrated normal volume without signs of congestion or thrombosis. No sonographic evidence of acute or chronic inflammatory, neoplastic, or infarctual changes was noted.

Liver

The **liver** images submitted revealed subjectively normal liver size, contour, and structure. Parenchymal echogenicity was naturally coarse and hypoechoic to the spleen. Vascular and biliary tracts were of normal volume with no evidence of congestion. The gallbladder presented acceptably thin walls with primarily anechoic content. The cystic and common bile ducts were normal. No pathological hepatic



PATIENT

lymphadenopathy was evident. No overt structural evidence of inflammatory, infiltrative or regenerative pathology was evident.

Seven Harris

SPECIES

Gastrointestinal

Canine

Examination of the **gastrointestinal tract** revealed a stomach and intestine free of stasis, of normal wall thickness, acceptable curvilinear mural detail, and peristaltic activity. Small and large intestine demonstrated normal luminal chyme and stool consistency respectively. No obstructive or overt infiltrative disease was noted. No associated abnormal lymphatic activity was noted.

BREED

Labrador Retriever

SEX

Pancreas

Male

The base and limbs of the **pancreas** were observed to be largely isoechoic to surrounding omental fat. Pancreatic duct and capsular contour were acceptably normal and parenchyma respected normal curvilinear patterns. No overt evidence of active inflammatory or neoplastic disease was noted.

AGE

88 years

Free Abdomen

WEIGHT

68.2 lbs

An undifferentiated, mixed, hypoechoic, moderately complex 10 x 5.8 cm caudal abdominal mass was noted in this patient. This is suspected to be Sertoli cell transformation from retained testicle. The mass appears to be isolated. There was no evidence of metastatic disease. Removal should prove curative. The prostate was not visualized. Slight free fluid was noted around the mass.

INTERPRETED BY

Heart

Eric Lindquist, DMV
DABVP, Cert. IVUSS

Rapid view of the heart revealed no evidence of pathology.

IMAGING PERFORMED BY

ULTRASONOGRAPHIC FINDINGS

Dr. Anderson

Mixed hypoechoic abdominal mass suspected to be Sertoli cell transformation from retained testicle.

HOSPITAL NAME

Elizabeth AH

INTERPRETATION OF THE FINDINGS & FURTHER RECOMMENDATIONS

Chest radiographs followed by exploratory surgery and mass removal is recommended.

REFERRING VET

Dr. Anderson

INVOICE

91321

DATE

8/18/21



PATIENT

Seven Harris

SPECIES

Canine

BREED

Labrador Retriever

SEX

Male

AGE

88 years

WEIGHT

68.2 lbs

INTERPRETED BY

Eric Lindquist, DMV
DABVP, Cert. IVUS

IMAGING PERFORMED BY

Dr. Anderson

HOSPITAL NAME

Elizabeth AH

REFERRING VET

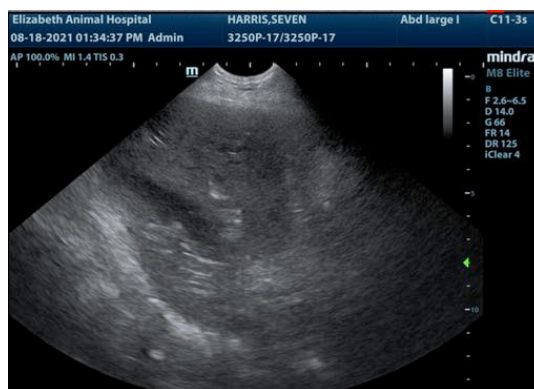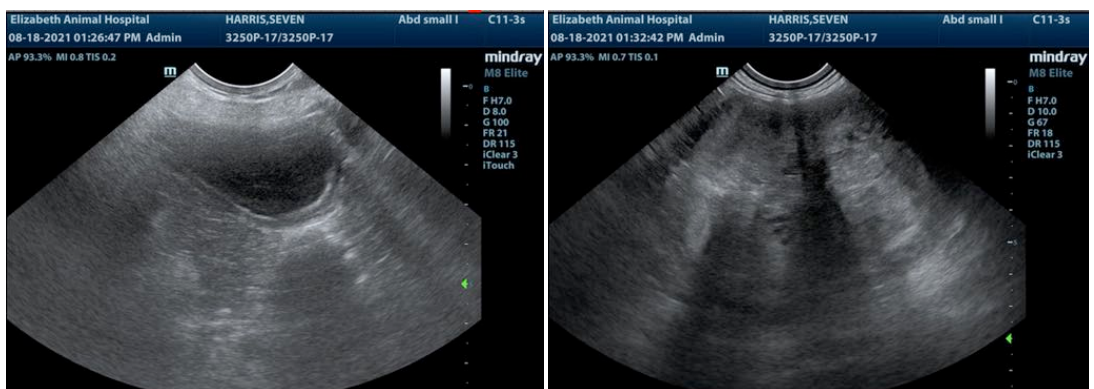
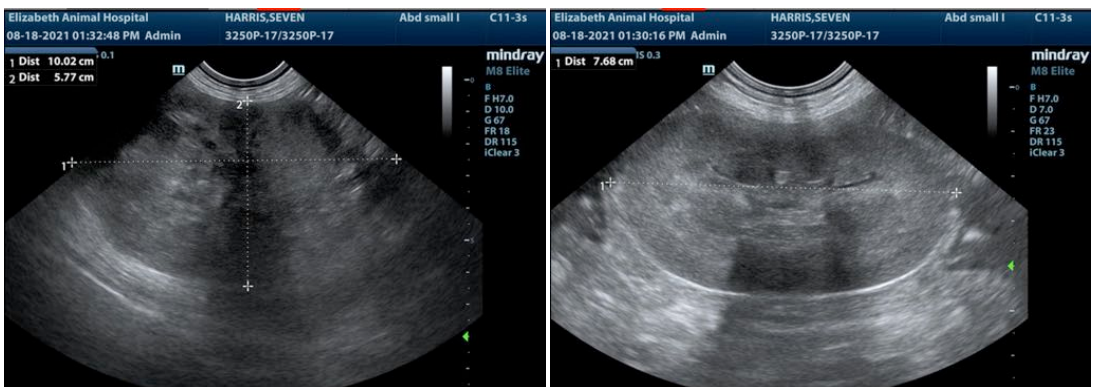
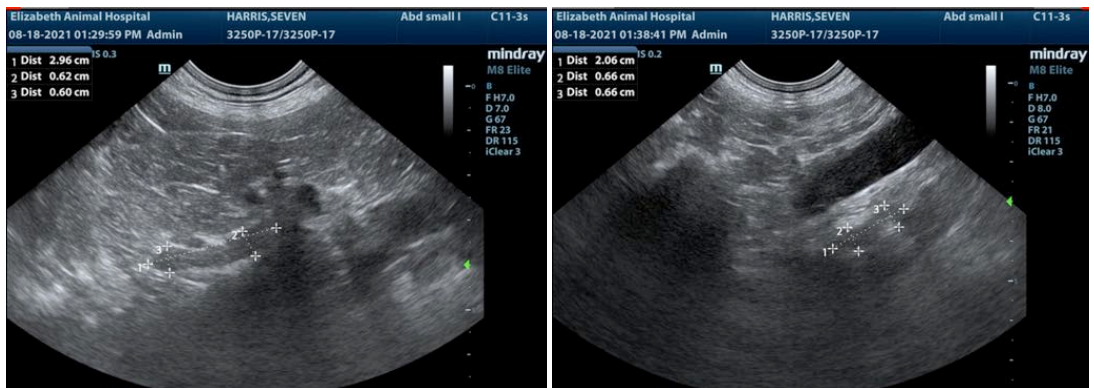
Dr. Anderson

INVOICE

91321

DATE

8/18/21





PATIENT

Seven Harris

veterinarian. No evaluation can be communicated regarding pathology that was not visible in the image/video clips provided.

Thank you for this referral. If the clinical or image interpretation does not parallel your findings or if I can be of any further assistance please contact me.

SPECIES

Canine

Eric Lindquist, DMV, DABVP, Cert. IVUSS, CEO of SonoPath.com
info@SonoPath.com

BREED

Labrador Retriever

SEX

Male

AGE

88 years

WEIGHT

68.2 lbs

INTERPRETED BY

Eric Lindquist, DMV
DABVP, Cert. IVUSS

**IMAGING
PERFORMED BY**

Dr. Anderson

HOSPITAL NAME

Elizabeth AH

REFERRING VET

Dr. Anderson

INVOICE

91321

DATE

8/18/21