

**DATE**

8/18/21

PRESENTING CLINICAL SIGNS

History: Chronic vomiting, patient has history of pancreatitis. Pet also has recurrent hematuria. ***PLEASE CHECK HEART BASE FOR HEMANGIO SCREENING***.

Current Medications: Provable capsules - 1 cap po SID Cerenia 24 mg - 2-tab po SID, Cytopoint -50 mg sq every 3-4 weeks, HA diet.

PATIENT

Pharoah Hankins

Lab Results: Most recent labs - 8/13/2021 - PLT elevated; mild lymphopenia; Chem was normal; UA - increased RBC + hyaline casts. We have emailed full labs + rads taken today.

Radiographs: Attached separately.

Date of Previous IntraPet Ultrasound: No previous IntraPet scans.

Sedation: not needed

Stat Report: not requested

SPECIES

Canine

BREED

Portuguese Water Dog

ULTRASONOGRAPHIC EXAMINATION OF THE ABDOMEN**Urinary System**

The **urinary bladder**, trigone, and pelvic urethra presented normal thicknesses and normal tone. The ureters were not visible which is normal. No uroliths or sediment were visualized and anechoic urine was present. No evidence of inflammatory or neoplastic changes was noted. Ureteral papillae were normal.

SEX

Neutered male

The **kidneys** revealed normal size and structure, corticomedullary definition and ratio for this age. The cortices presented largely uniform texture with normal echogenic relationship to liver and spleen. Medullary structure differed distinctly from the cortex and no evidence of pelvic dilation was present. The capsules were acceptably uniform without significant irregularities. The right kidney measured 5.65 cm.

AGE

9/12

WEIGHT

47.6 lbs

Adrenal Glands

Both **adrenal glands** were visualized and recognized as having normal shape, size, position and echogenicity for this breed. The phrenic vasculature, glandular echogenicity and detail were unremarkable. Capsule, cortex, and medullary definition were normal for this age patient. The left adrenal gland measured 2.14 x 0.82 cm at the caudal pole and 0.66 cm at the cranial pole. The right adrenal gland measured 2.66 x 0.74 cm at the caudal pole and 0.63 cm at the cranial pole.

INTERPRETED BYEric Lindquist, DMV
DABVP, Cert. IVUSS**Spleen**

The **spleen** revealed subtle, micronodular changes without significant disruption of architecture. However, given the intestinal presentation FNA of the spleen is warranted for screening purposes.

HOSPITAL NAME

Rolling Hills AH

REFERRING VET

Dr. Sutton

Liver

The **liver** images submitted revealed subjectively normal liver size, contour, and structure. Parenchymal echogenicity was naturally coarse and hypoechoic to the spleen. Vascular and biliary tracts were of normal volume with no evidence of congestion. The gallbladder presented acceptably thin walls with primarily anechoic content. The cystic and common bile ducts were normal. No pathological hepatic lymphadenopathy was evident. No overt structural evidence of inflammatory, infiltrative or regenerative pathology was evident.

INVOICE

91343

Gastrointestinal

The stomach appeared normal. The distal ileum approaching the ileocecal junction revealed an infiltrative mass with wall thickness measured up to 1.5 cm. The mass extended for approximately 4-6 cm in total length. It appears to be isolated. Regional inflammatory pattern was noted around the intestinal mass. The remainder of the intestine was unremarkable.

Pancreas

The base and limbs of the **pancreas** were observed to be largely isoechoic to surrounding omental fat. Pancreatic duct and capsular contour were acceptably normal and parenchyma respected normal curvilinear patterns. No overt evidence of active inflammatory or neoplastic disease was noted.

Heart

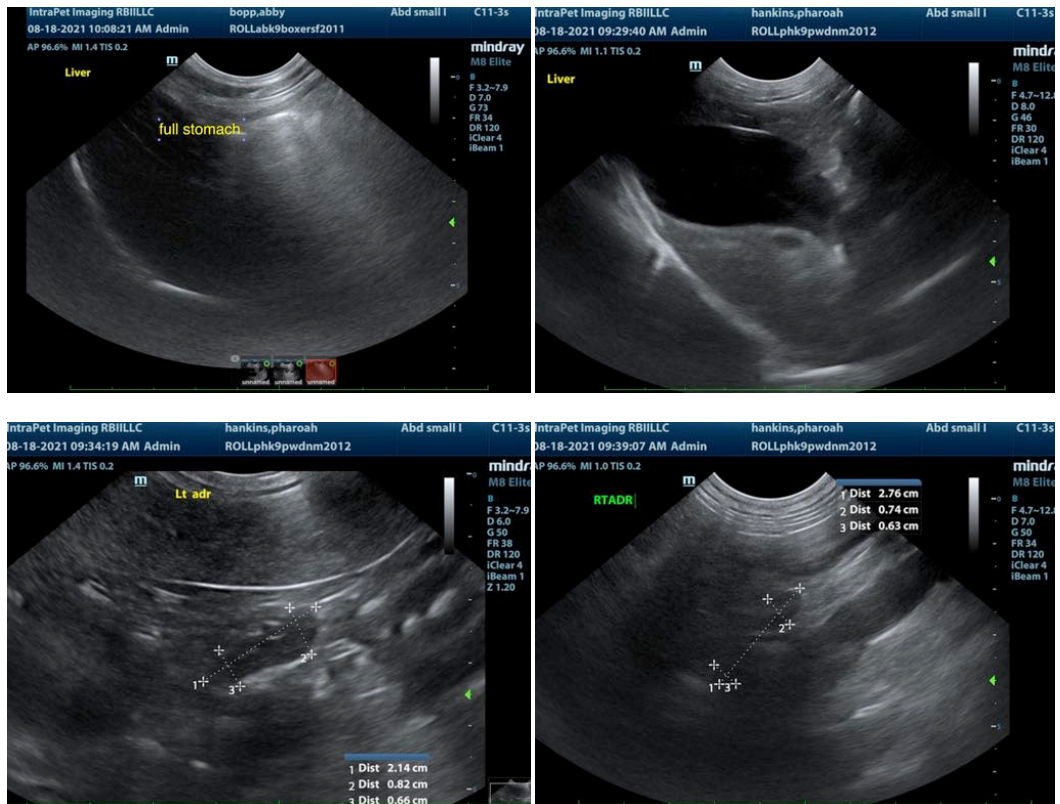
Rapid view of the chest revealed no evident pathology. Subjective normal cardiac structure and function. There is no evidence of extracardiac pathology in the visible planes.

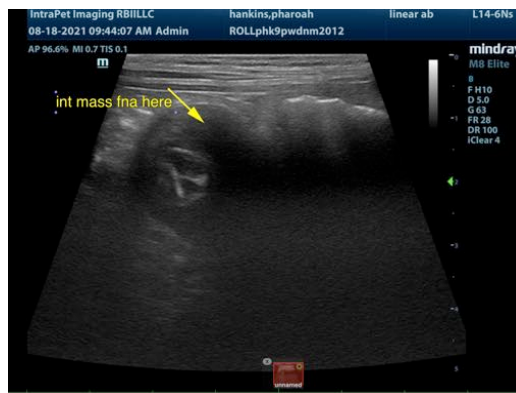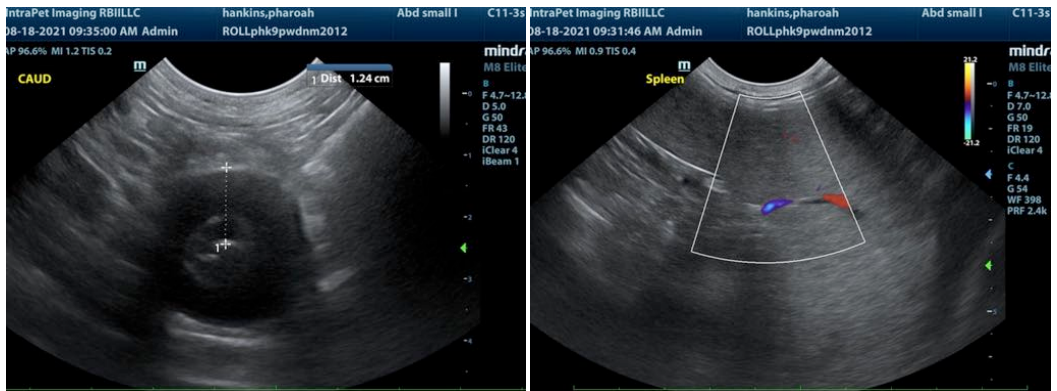
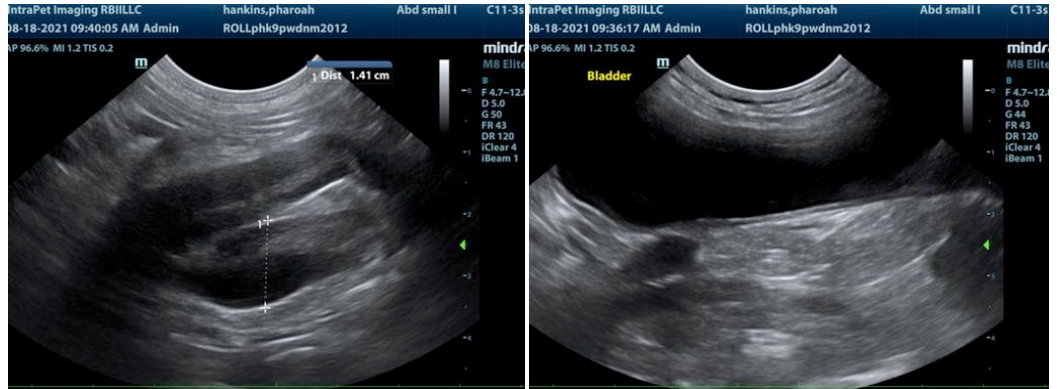
ULTRASONOGRAPHIC FINDINGS

Intestinal mass with micronodular spleen.

INTERPRETATION OF THE FINDINGS & FURTHER RECOMMENDATIONS

I recommend FNA of the spleen for screening purposes to ensure that the lesion is benign. FNA of the intestinal mass would also be ideal, but may be difficult to exfoliate. Intraoperative ultrasound with aggressive resection and anastomosis would be ideal. The mass appears to be in the ileum/ileocecal region.





The information and recommendations provided are based on the images presented by the referring veterinarian. No evaluation can be communicated regarding pathology that was not visible in the image/video clips provided.

Thank you for this referral. If the clinical or image interpretation does not parallel your findings or if I can be of any further assistance please contact me.

Eric Lindquist, DMV, DABVP, Cert. IVUSS, CEO of SonoPath.com
 Eric.Lindquist@SonoPath.com