



PATIENT

Jake Callaghan

SPECIES

Canine

BREED

Portugese Water Dog

SEX

Neutered male

AGE

12 years

WEIGHT

31.7 kg

INTERPRETED BY

Eric Lindquist, DMV
DABVP, Cert. IVUSS

IMAGING PERFORMED BY

Dr. Gumley

HOSPITAL NAME

Cedarview AH

REFERRING VET

Dr. Gumley

INVOICE

46678

DATE

8/17/23

PRESENTING CLINICAL SIGNS

History: Previously noted to have elevated total calcium for last few years by rDVM. iCa and PTH suggest primary parathyroidism. Has heart murmur and periodic VPCs (echo submitted).
Abnormal PE/Chem/CBC/UA Results: Grade 2/6 left apical heart murmur. No lymph node enlargement, normal anal sacs. Bright and alert. iCa = 1.71 (normal 1.25 - 1.45), PTH = 7.7 (normal 1.1 - 10.6)

ULTRASONOGRAPHIC EXAMINATION OF THE THYROID

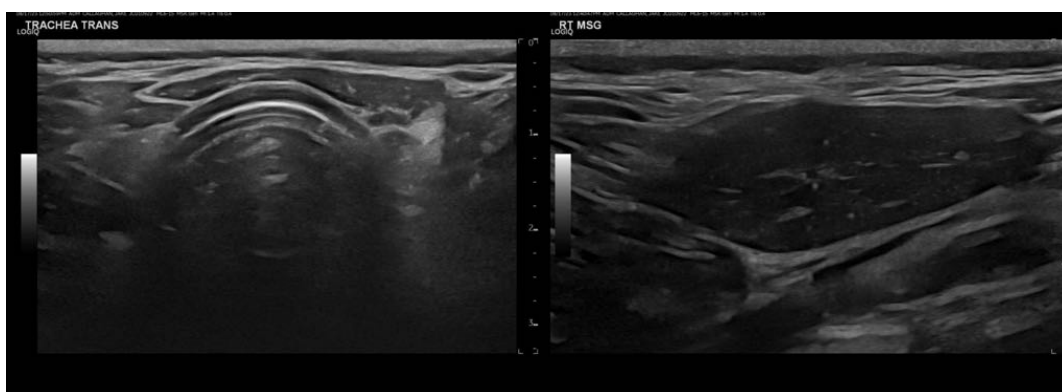
The left thyroid lobe in this patient revealed a 1.2 x 0.66 cm hypoechoic, expansive parathyroid. This is consistent with adenoma. The right thyroid lobe was uniform with no evidence of pathology and measured 0.7 cm. The trachea, carotid artery, esophagus, salivary glands in view were all unremarkable. The left parathyroid adenoma was in the midbody and appears resectable.

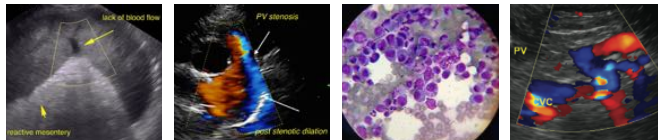
ULTRASONOGRAPHIC FINDINGS

Left medial parathyroid adenoma.
Otherwise, unremarkable cervical region.

INTERPRETATION OF THE FINDINGS & FURTHER RECOMMENDATIONS

Surgical intervention is recommended. 25-gauge ultrasound-guided FNA of the hypoechoic nodule could be considered to confirm adenoma; however, this is strongly consistent with parathyroid adenoma given the patient's history and appears readily resectable from a surgical standpoint.





PATIENT

Jake Callaghan

SPECIES

Canine

BREED

Portugese Water Dog

SEX

Neutered male

AGE

12 years

WEIGHT

31.7 kg

INTERPRETED BY

Eric Lindquist, DMV
DABVP, Cert. IVUSS

IMAGING PERFORMED BY

Dr. Gumley

HOSPITAL NAME

Cedarview AH

REFERRING VET

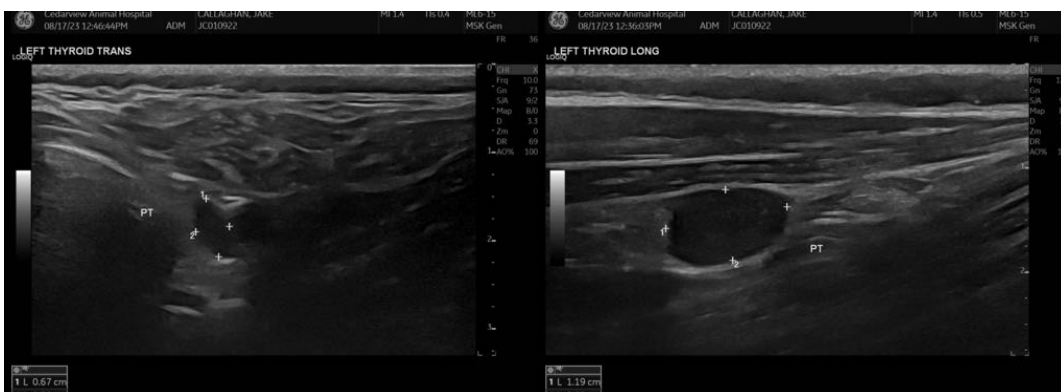
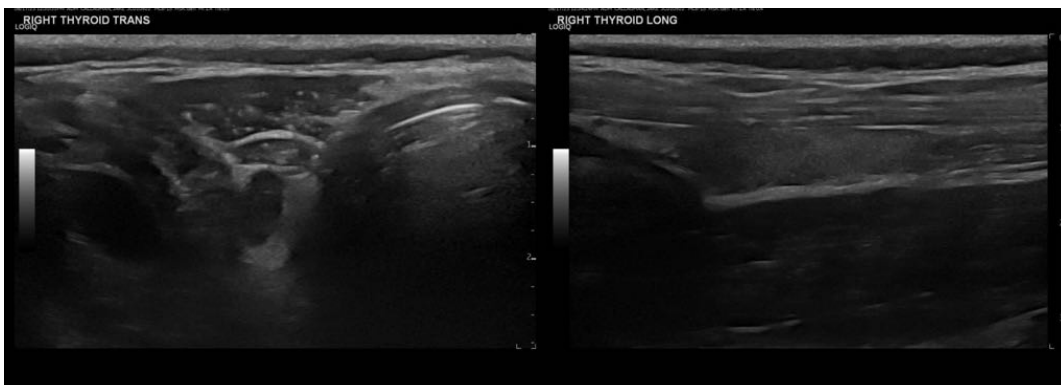
Dr. Gumley

INVOICE

46678

DATE

8/17/23



The information and recommendations provided are based on the images presented by the referring veterinarian/sonographer. No evaluation can be communicated regarding pathology that was not visible in the image/video clips provided.

Thank you for this referral. If the clinical or image interpretation does not parallel your findings or if I can be of any further assistance please contact me.

Eric Lindquist, DMV, DABVP, Cert. IVUSS, CEO of SonoPath.com
info@SonoPath.com