



PATIENT PRESENTING CLINICAL SIGNS

Frank Ficacci

History: Appointment for check mouth/teeth. Per Dr. Casulli worsening heart murmur 5/6 with thrill. No coughing or sneezing. Echo is pre-surgical measure. Medications: Pheno 1/4 grain: 1/2 tab po bid
Abnormal PE/Chem/CBC/UA Results: CBC/CHEM pending - sent to Idexx on 8/17/23.

SPECIES

Canine

ULTRASONOGRAPHIC EXAMINATION OF THE HEART

BREED

Maltipoo

The echocardiogram in this patient demonstrated normal **left atrial** size based on 3 different LA measurement methods. Chamber volumes and echogenicity were normal. The cranial and caudal **mitral** valve leaflets presented vegetative thickening consistent with endocardiosis. Doppler indicated measurable insufficiency. The **left ventricle** presented thicknesses with linear contour and was not dilated nor restricted. The **myocardium** presented normal echogenicity without subjective evidence of significant fibrotic or ischemic disease. **Contractility** of the ventricular walls was adequate and in normal range for this patient evidenced by the fractional shortening measurement and subjective evaluation of the different regions of the myocardium. The **left ventricular outflow** tract demonstrated normal laminar flow and subjective structural integrity. The **right atrium** and auricle revealed normal size, structure and content. No evidence of masses was noted or chamber overload. Minor **tricuspid** insufficiency was noted. The **right ventricle** was of normal size (1/3 diameter of LV), chordae structure, myocardial echogenicity and thickness. **Pulmonic** tract assessment revealed normal valve structure, laminar flow, and diameter (approx. 1:1 pa/ao ratio). No visible **pericardial** or free pleura fluid was noted. No echographically detectable evidence of infiltrative disease was visible. The cranial **mediastinum and pericardial regions** were free of masses in the visible window. Arrhythmogenic activity was noted in this patient.

SEX

Neutered male

AGE

12 years

WEIGHT

6.3 lbs

INTERPRETED BY

Eric Lindquist, DMV
DABVP, Cert. IVUSS

IMAGING PERFORMED BY

Carla

HOSPITAL NAME

Animal Care Center of
Flanders

REFERRING VET

Dr. Casulli

| CANINE CARDIAC PARAMETERS | MR VMAX (m/s) | TR VMAX (m/s) | LA/AO (Boon method) | LA/AO (Heart Base;) | FS (%) | EF (%) | EPSS (cm) |
|---------------------------------|---------------------|---------------------|------------------------|---------------------------|--|--|--|
| NORMAL PARAMETER | 4.5-5.5 | <2.7 | 1.3 | Up to 1.6 | 28-40 | 40-100 | <0.6 |
| PATIENT | 5.5 | | 1.3 | 1.4 | 50 | | 0.1 |
| CANINE CARDIAC PARAMETERS | HR (BPM) | AV VMAX (m/s) | PV MAX (m/s) | BODY WEIGHT | LA 2D short axis Base view (cm) | LVIDd Avg; 2D and m- mode short axis (cm) | LVIDs Avg; 2D and m- mode short axis (cm) |
| NORMAL PARAMETER | 50-100 | 0.7-1.7 | 0.7-1.6 | BELOW | BELOW | BELOW | BELOW |
| PATIENT | | | | 6.3 lbs | 1.8 | 1.7 | |

INVOICE

46677

DATE

8/17/23

ULTRASONOGRAPHIC FINDINGS

Stage B1 valvular disease. No treatment is recommended at this time.



INTERPRETATION OF THE FINDINGS & FURTHER RECOMMENDATIONS

PATIENT

Frank Ficacci

There is no indication for Pimobendan or other medications unless the patient has systemic hypertension.

SPECIES

Canine

BREED

Maltipoo

SEX

Neutered male

AGE

12 years

WEIGHT

6.3 lbs

INTERPRETED BY

Eric Lindquist, DMV
DABVP, Cert. IVUSS

IMAGING PERFORMED BY

Carla

HOSPITAL NAME

Animal Care Center of
Flanders

REFERRING VET

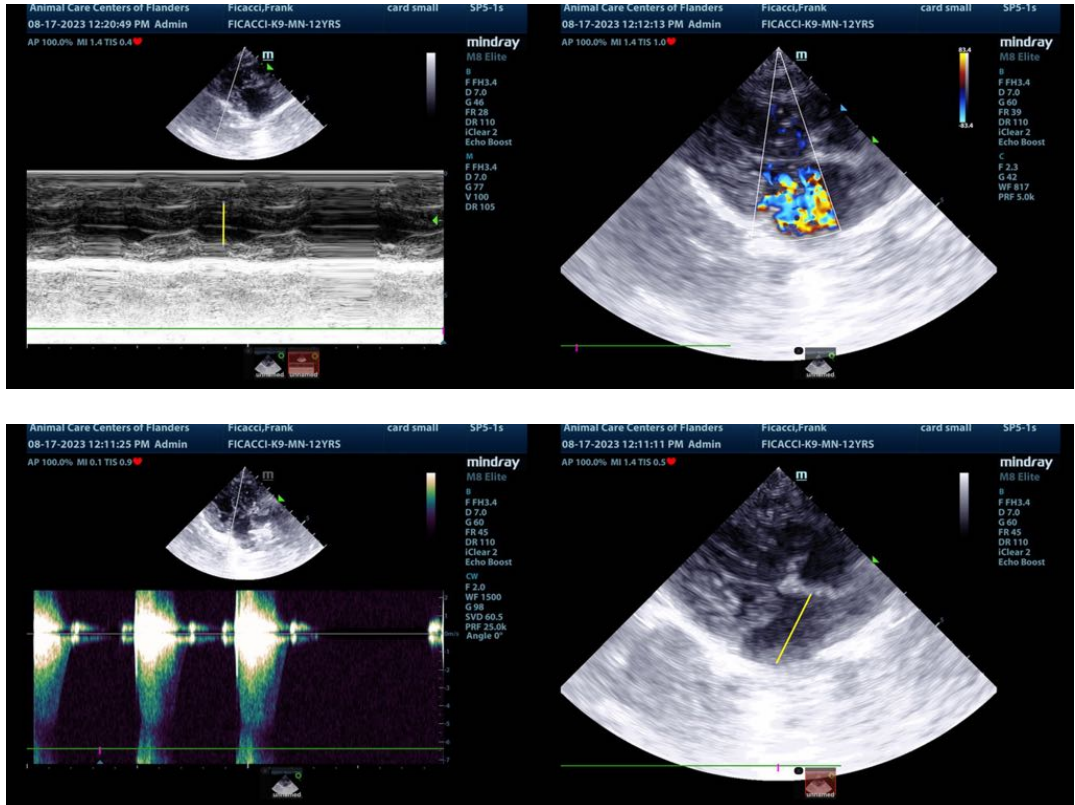
Dr. Casulli

INVOICE

46677

DATE

8/17/23



The information and recommendations provided are based on the images presented by the referring veterinarian/sonographer. No evaluation can be communicated regarding pathology that was not visible in the image/video clips provided.

Thank you for this referral. If the clinical or image interpretation does not parallel your findings or if I can be of any further assistance please contact me.

Eric Lindquist, DMV, DABVP, Cert. IVUSS, CEO of SonoPath.com
info@SonoPath.com